REPRODUCTION IN THE SPOTTED HYAENA, *CROCUTA CROCUTA* (ERXLEBEN)

By L. HARRISON MATTHEWS
Department of Zoology, University of Bristol

(*Communicated by A. S. Parkes, F.R.S.—Received* 26 *October* 1938)

[Plates 1–14]

CONTENTS

INTRODUCTION

> "Hyaenis utramque esse naturam, et alternis annis mares alternis foeminas fieri, parere sine mare, vulgus credit."
>
> PLINY, *Hist. Nat.* lib. VIII, cap. XXX.

From time immemorial it has been known that there is something peculiar about the sexual anatomy and physiology of the spotted hyaena. The writers of antiquity relate the legend that this animal is hermaphrodite, or that it can change its sex at will. Aristotle (384–322 B.C.) mentions the story, but says that it is untrue. He did not, however, distinguish between the spotted and striped hyaenas: the legend relates to the spotted hyaena, but his refutation to the striped, the genital anatomy of which he correctly describes. Pliny the Elder (A.D. 23–79) repeats the legend, mentioning Aristotle's denial of its truth. Claudius Aelianus (*ca.* A.D. 160–220) also states that the hyaena changes its sex in alternate years. The same, or similar, stories have been

VOL. 230. B 565 (Price 24*s.*) [Published 5 July 1939

current until the present day, although little has appeared on the subject in print. Even in 1936 a travel book refers to the spotted hyaena as "hermaphrodite" (Hemmingway 1936).

The scientific literature of the subject is surprisingly meagre. Watson (1877, 1878, 1879, 1881) published descriptions of the anatomy, and especially the genital anatomy, of four deceased menagerie specimens. He showed that the urinogenital canal in the female terminates at the extremity of a large clitoris, which, in the non-parous animal at least, is practically indistinguishable in size and form from the penis of the male. Chapman (1888) confirmed Watson's description, and Grimpe (1916) published some observations on the external genital anatomy of the female, together with some interesting information on the breeding of the species in captivity. The latter point is treated more fully by Schneider (1926). Neuville (1935, 1936 *a*, *b*) describes and discusses the external female genitalia of two aged menagerie specimens, and those of a newly born pup. Nothing further of importance has been traced on the subject: the few additional papers of minor interest are those of Schmotzer and Zimmerman (1922) and Grimpe (1923).

The subject of reproduction in the spotted hyaena thus appeared to be one into which investigation was desirable. Little or no material was available in Europe, and correspondence with the Game Departments of Kenya and Tanganyika revealed the fact that, though the spotted hyaena is one of the commonest animals in many parts of Africa, nothing was known of its breeding, beyond the popular accounts of hermaphroditism referred to above. In the autumn of 1935, therefore, the author travelled to East Africa to study the animal.

MATERIAL AND METHODS

The most promising way of investigating the problem in hand appeared to be to examine as large a series of spotted hyaenas as possible. The writer therefore chartered a 30-cwt. lorry at Arusha, Tanganyika Territory, loaded it with the necessary camping and collecting equipment, and set off "on safari" in search of hyaenas. They are to be found in Tanganyika wherever game is plentiful: a good hunting ground was found on the Balbal plains, below the mountain of that name, west of the Ngorongoro crater, on the edge of the Serengeti plains. Most of the collecting was done at various camps in this region: a visit was made to the Serronea river at the western side of the Serengeti area; and further work was done in the neighbourhood of Mto-wa-mbo near the north end of Lake Manyara in the Great Rift valley.

Hyaenas were easily obtained at night by putting out baits, usually of zebra meat, near the camp. Many were killed by poisoning the baits with strychnine; early and late arrivals at the baits were shot at dusk and dawn if there was enough light. Occasional specimens seen in full daylight were also shot as opportunity offered.

The animals were examined as soon as possible after death. The field work included taking a full set of measurements from each animal in the flesh, examination of the external genitalia, and recording the findings, with measurements and sketches. The internal genitalia were examined, and the complete genital tract was dissected out and preserved from fifty-one of the first sixty-seven animals examined. Later, when storage space became crowded, the complete genital tract of females only was preserved, and the testes alone of the males. The material preserved for histological examination was fixed in alcoholic Bouin's fluid: large specimens were fixed in 10 % formalin. After fixation the material was graded up to 70 % alcohol, in which it was finally preserved.

Notes were made on the colour and state of the pelage; internal and external parasites were collected; blood smears were obtained from most of the specimens; the skulls of all the animals were preserved, and the skins of over eighty. These additional observations and specimens will be reported upon separately elsewhere.

After returning to England the material was completely re-examined, and the various organs of the genital tract were dissected apart and weighed. Histological examination necessitated the sectioning of material from the ovaries, fallopian tubes, uterine cornua and body, vagina, Bartholin's glands, anal glands and mammary glands of the females; and from the testes, epididymides, vasa deferentia, Cowper's glands, prostate, and anal glands of the males. All sections were cut at a thickness of $10\,\mu$, and usually stained with Heidenhain's haematoxylin and Beibrich scarlet.

The material comprised specimens from one hundred and three spotted hyaenas. A number of others was examined, but material from them was not preserved for various reasons. Some of them were not examined until decomposition had started, others had been damaged after death by vultures, hyaenas or other wild animals, and yet others had been badly mangled by the spears of the Masai.

SEX RATIO

Of the one hundred and three animals collected, sixty-three were males and forty females, giving a sex ratio of 61·1 % of males. Unfortunately there is no means of knowing to what extent the series of animals is a representative sample of the population. There was, of course, no selection in collecting, but it is impossible to know whether the methods used favoured the capture of one sex rather than the other. If this is, in fact, an indication of the true sex ratio, there is a very high proportion of males when compared with the sex ratio of other animals. In the dog, the only carnivore in which the sex ratio appears to be known, Parkes (1926) gives the sex ratio as 110·7 to 118·5 males per 100 females, a proportion of 52·8 to 54·3 % of males. It is of interest to notice that this sex ratio is the highest known among domestic or laboratory animals, and, although it refers to the ratio at birth, it may lend some support to the possibility that the high male proportion in the present series may be an indication of the true sex ratio of the population, in the area from which the animals were collected.

EXTERNAL ANATOMY OF THE GENITO-ANAL REGION

(1) THE MALE

The posterior border of the base of the free part of the penis lies at a distance of 20–28 cm. from the root of the tail, or 15–20 cm. anterior to the centre of the anus. The free part of the penis is pendulous, and directed in a forwards and downwards direction. It is 4·0–6·5 cm. in length and 2·5–3·5 cm. in diameter at its base. The prepuce covers most of the glans, of which the tip only is sometimes exposed. It is black in colour and covered with a large number of small transverse and longitudinal wrinkles. There is no median raphe, but the skin of the ventral surface is frequently drawn up into a low longitudinal ridge.

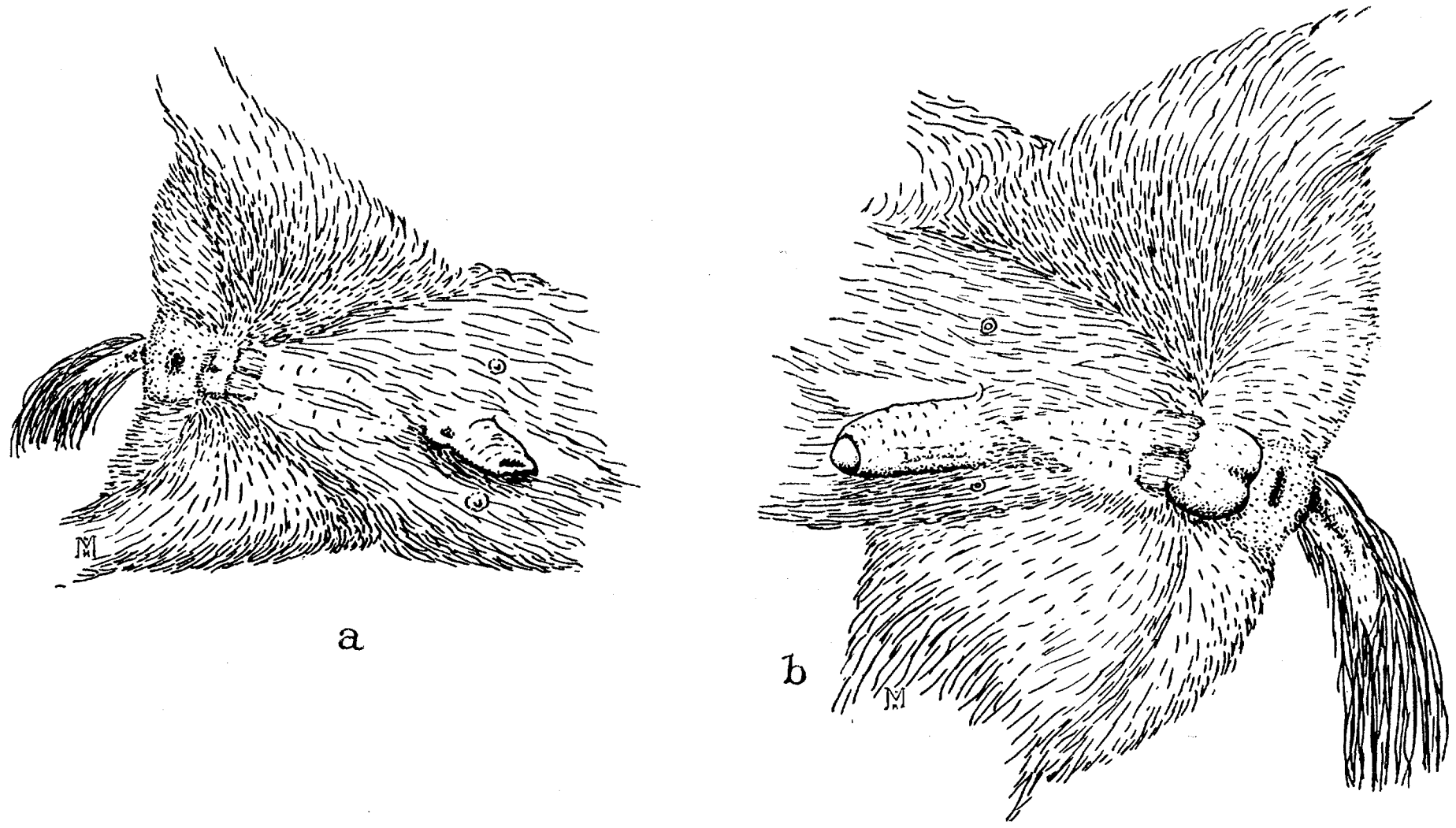

FIG. 1. External genitalia of the male. *a*, prepubertal. *b*, adult (not on the same scale).

Just in front of the penis there is a bare area of skin on the abdomen. It is triangular in shape, with its apex directed forwards. Its base is equal in length to the diameter of the penis, and the sides converge as it runs forward for 7·5–12·5 cm. towards the umbilicus. The surface of the abdomen around it is covered with hair. Its colour is pink to greyish pink.

The glans penis (fig. 2 *a*) is of an elongated ovoid shape, with the pointed end placed distally, and its greatest width one-third to one-half of its length from the base. The dorsal surface is bluntly truncated, so that in side view the profile of the ventral surface is curved, while that of the dorsal surface is curved at its base, but flattened at its extremity. The meatus opens as a longitudinal slit about 2–3 mm. in length, on the dorsal surface of the tip. On the ventral surface, near the base, there is a broad low fraenum preputii, which does not extend far on to the surface of the glans. The distal part of the glans penis is smooth, but the proximal part is covered with a large number of small backwardly directed spines. The border of the spine-covered area is sharply marked off from the smooth area, and extends nearer the tip of the glans on the ventral than on the dorsal surface. The area of spines stops abruptly a few millimetres distal to the junction of glans and prepuce. The colour of the glans is very dark grey to black, its length 3–4 cm. and its greatest breadth, both in transverse and dorso-ventral directions, 1·5–2·9 cm. In some specimens the prepuce projects as much as 1·0 cm. beyond the tip of the glans; in others the tip of the glans is exposed.

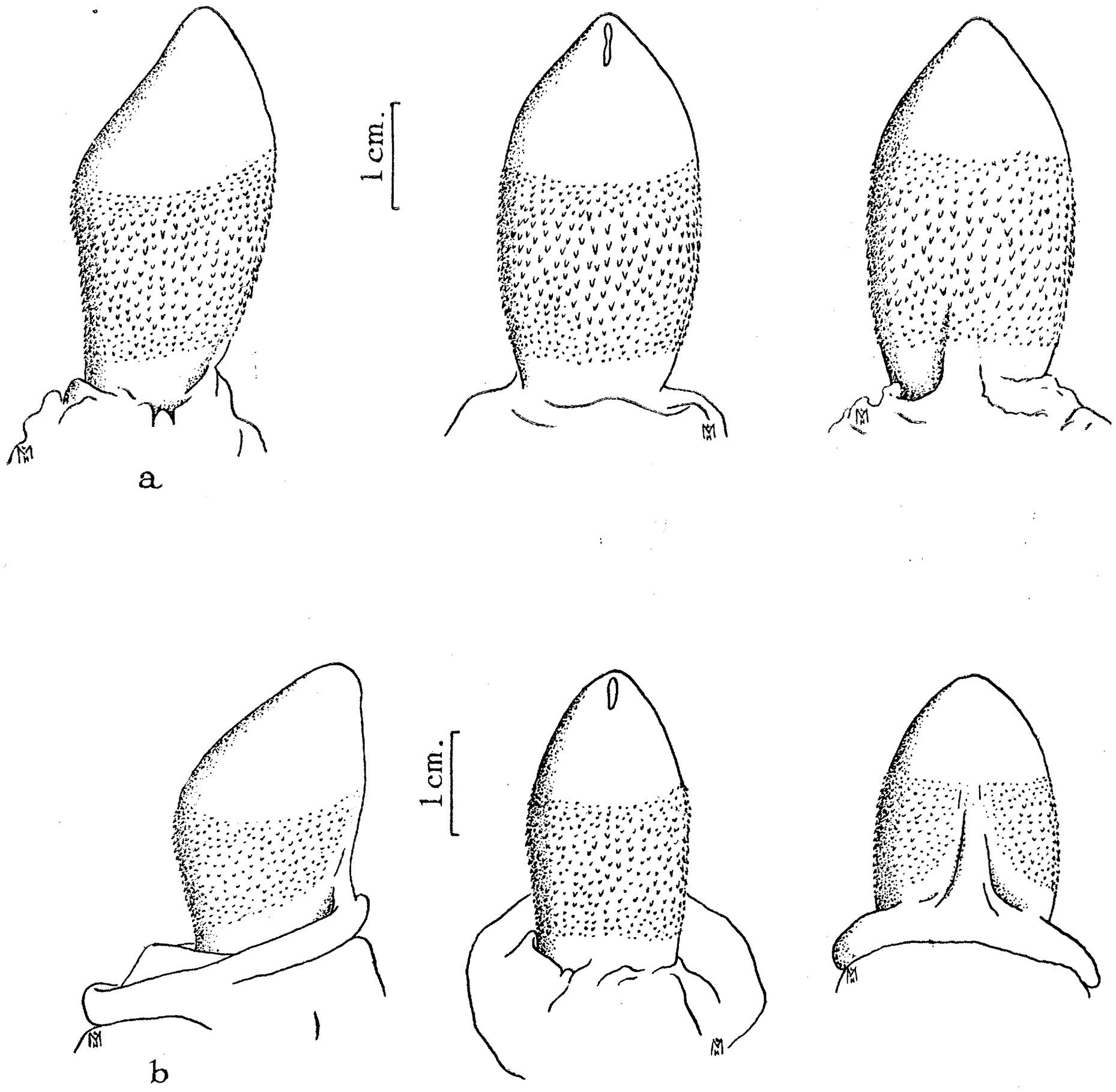

FIG. 2. *a*, glans penis of adult male. *b*, glans clitoridis of prepubertal female.

Immediately behind the base of the penis the hair of the abdomen meets in the middle line, so that the free part of the penis is cut off from a bare area, lying more caudally, by a bridge of fine hair, about 1·5 cm. across in the antero-posterior direction. Behind this bridge of fine hairs lies another bare area. It is roughly triangular, with its apex directed cranially and its base caudally. It is from 8 to 12 cm. in length, and 3·5–5·9 cm. in greatest width. The skin covering it is smooth, but is thrown into two to four parallel median furrows. On each side of the furrows it is covered with a large number of minute transverse wrinkles. In colour it is grey to greyish pink. At its base, which tends to be bent caudally rather than to be directly transverse, it is bounded by the scrotum.

The scrotum consists of two shallow scrotal pouches, one on each side of the middle line, with their greatest projection from the surface of the body at their posterior ends. The scrotum is further divided into two well-marked parts, anterior and posterior. The anterior part is practically flush with the general surface of the perineal region. It is covered with a dense growth of short fine hairs, pale yellowish or nearly white in colour. This area, covered by the tufts of whitish caudally directed. hairs, measures about 2·0 cm. in the antero-posterior direction. The posterior part of the scrotum is covered with smooth skin, black in colour, and bearing only minute scattered hairs, so that it appears glabrous unless closely examined. It measures in antero-posterior length from 3·5 to 5·0 cm., and in transverse width from 2·5 to 4·5 cm. It is the part into which the testes descend, and projects from the perineal region in a posterior direction for about 1·3 cm. A fold is thus produced between its posterior part and the perineum. Its greatest projection at right angles to the perineal level is about 2·5 cm. The scrotal pouches are thus low eminences on the perineum, and are never pendulous. One, or both, of the testes sometimes lies under the skin of the perineal region, so that no external swelling is produced. The pouches then project only slightly, owing to their subcutaneous adipose tissue, and the testes can be felt under the skin slightly anterior to the bare scrotal area. In forty-seven specimens both testes were fully descended into the scrotum and visible externally. In ten one only was visible, while the other could be felt beneath the skin. This condition was found on the right side in three and on the left in seven specimens. Finally, in four specimens neither of the testes caused any external swelling, but could be felt as they lay under the skin slightly anterior to the bare area. Of the forty-seven in which both testes were in the scrotum, eight were noted as having the right one more prominent. The degree of prominence of the testes is certainly not correlated with age: in many quite young specimens both the rather small testes were equally prominent in the scrotum; and among the adults examples were found in which neither of the testes were visible, but merely palpable under the skin. There appears to be a distinct tendency for the right testis to be the most prominent and completely descended.

Behind the scrotum lies the anal area. It is bounded on the anterior side by the scrotum, laterally by the thighs, and posteriorly by the root of the tail. It measures from 7·5 to 10·0 cm. in antero-posterior direction, and is covered with short velvety hairs of a pale buffish colour. The anus lies within the anal pouch, a circular depression about 2·5 cm. in diameter and 1·0 cm. deep. Inside the anal pouch the anus opens centrally; and at the upper, or posterior, part of the pouch lie the mouths of the ducts of the anal glands. The distance from the centre of the anus to the posterior end of the scrotum is 1·5–2·5 cm., and to the root of the tail is 5·0–7·5 cm. The region immediately round the anus, and especially that part between it and the tail, is considerably swollen by the presence of the large anal glands underneath the skin. So great is the projection of the glands that a deep pocket is formed immediately below the root of the tail. It is, of course, blind, and no ducts, from the anal glands or elsewhere, open into it. It is lined with velvety hair similar to that upon the anal region. The under surface of the root of the tail is nearly bare of hair, carrying only scattered fine hairs for a distance of about 10 cm. distal to its origin: the rest of the tail carries long bushy hair.

On the surface of the abdomen there is a pair of rudimentary nipples. They are placed in the centres of small areolae, about 1·3 cm. in diameter, covered with bare black skin beset with fine wrinkles. The nipples are 3·0–5·0 mm. in diameter, and rise to a distance of about 3·0 mm. from the surface of the abdomen. They lie one on each side of the mid-ventral line, about 9·0 cm. apart. The line joining them passes through the anterior border of the base of the free part of the penis.

(2) The female

The external genitalia of the prepubertal, the nulliparous but sexually mature, and the parous female spotted hyaena differ in several respects. The conditions in the prepubertal animal are first described and the differences in the other states are then indicated.

The prepubertal female

The external anatomy of the prepubertal female resembles that of the male very closely. There is a peniform clitoris, penetrated by the urinogenital canal, in a position corresponding with that of the penis; and a swelling similar in appearance to the male scrotum at a parallel site.

The posterior border of the free part of the clitoris lies from 18·0 to 20·0 cm. anterior to the centre of the anus, and from 22·0 to 25·0 cm. anterior to the root of the tail, measured round the curve of the perineal region. The free part of the clitoris is, like the penis of the male, directed in a forwards and downwards direction. It is about 5·0 cm. in length, and 2·5–3·0 cm. in diameter at its base. The prepuce covers the glans, of which the tip is sometimes exposed. The prepuce is black in colour, and covered with small transverse and longitudinal wrinkles. The skin of the posterior surface is frequently drawn up into a low ridge, though there is no median raphe. In front of the clitoris a triangular area of bare skin runs forward, for 7·5–12·5 cm., towards the umbilicus. Its apex is directed cranially, and its colour is pink or greyish pink. Its base is as wide as, or a little wider than, the diameter of the base of the free part of the clitoris. A narrow bare area thus borders the base of the clitoris on each side.

The glans clitoridis (fig. 2*b*) is strikingly similar to the glans penis of the male. Its shape, an elongated ovoid with the smaller end directed distally, is almost identical with that of the glans penis, but its size is slightly smaller. Its length is 3·0–3·5 cm., and its greatest thickness, both in transverse and dorso-ventral directions, is about 1·5 cm. or a little more. On the ventral surface there is a low, though well-marked, fraenum preputii, which extends less than half-way along the glans. The ventral surface of the glans is shorter in antero-posterior length than the dorsal surface. This dimension is

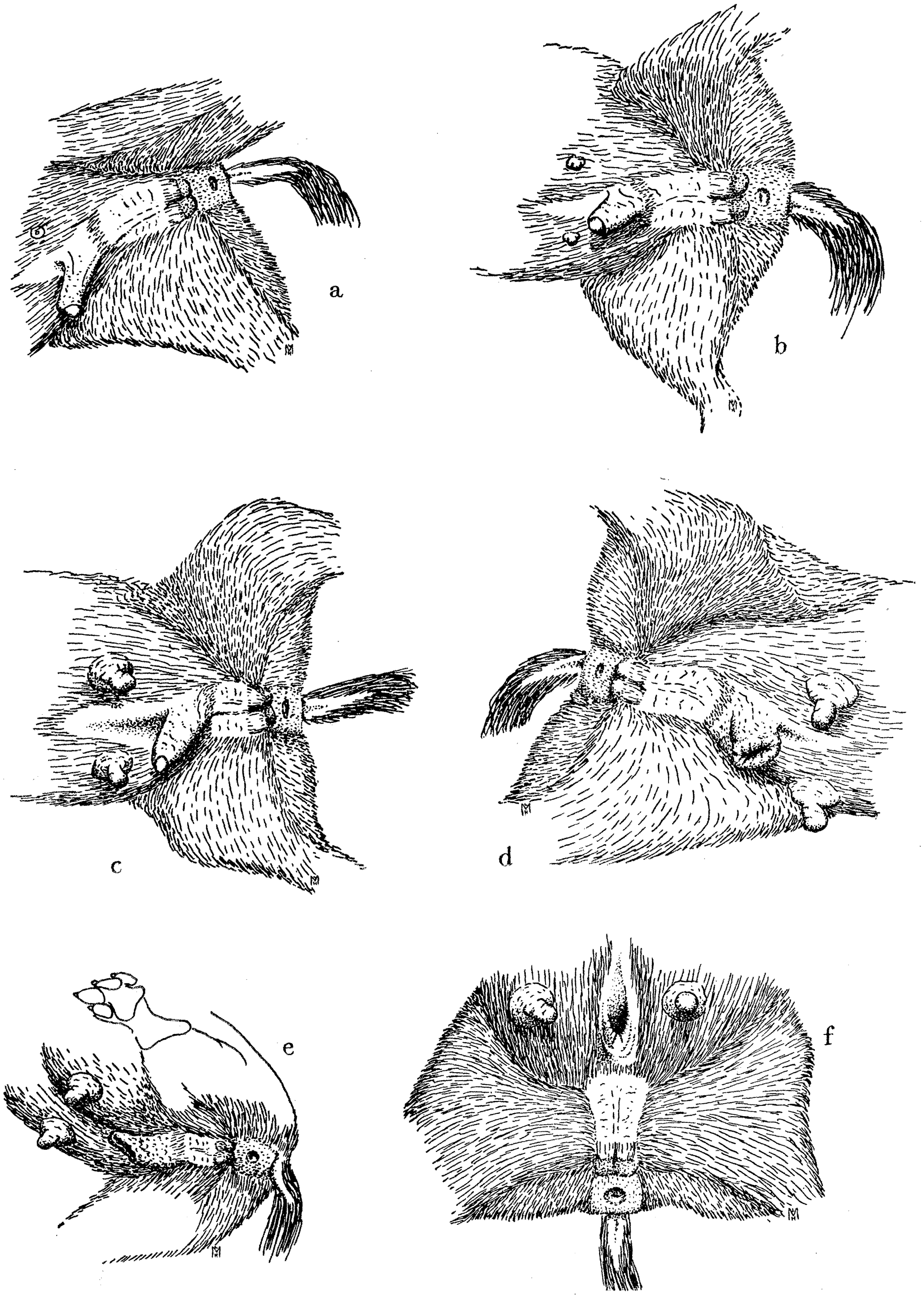

FIG. 3. External genitalia of the female. *a*, prepubertal (group A). *b*, prepubertal (group B) approaching first oestrus. *c*, parous anoestrous. *d*, parous at oestrus. *e*, *f*, lactating.

shorter proportionally than the corresponding distance in the male, so that when the prepuce is retracted a shorter ventral surface is exposed than in that sex. Owing to the shortness of the fraenum and ventral surface of the glans, the junction of glans and prepuce, on the ventral surface only, is drawn farther towards the tip of the glans than in the opposite sex. The distal part of the glans is smooth, but the proximal part is covered with numerous backwardly directed spines, which may be a trifle smaller than in the male. The division between the smooth and spinous areas is sharply marked anteriorly, and the spines extend farther distally on the ventral than on the dorsal surface. The spinous area stops short of the base of the glans by a distance of a few millimetres. In the region of the fraenum preputii the spines are smaller and more widely spaced. The meatus of the urinogenital canal is similar in appearance and position to the urethral meatus of the male. It is a small longitudinal slit, 2·0–3·0 mm. in length, opening on the dorsal surface of the tip of the glans. It is probably one of the most unusual of the forms which the external orifice of the urinogenital canal takes amongst female mammals.

Immediately behind the free part of the clitoris the hair of the abdomen meets in the middle line, so that the clitoris is separated by it from another bare area nearer the tail. This hairy area is greater in the antero-posterior direction than in the male, measuring 3·0–5·0 cm. in length. Behind it lies a bare area, which is shorter in antero-posterior length, but wider transversely, than in the male. It is also less triangular and more quadrilateral in shape. Its length is 7·5–10·0 cm., and its width 5·0–6·3 cm.; its posterior border is slightly V-shaped, with its apex directed caudally. The skin covering this area is bare, save for minute scattered hairs, and is grey to greyish pink in colour. It is thrown into from two to four parallel median longitudinal furrows, on each side of which it is covered with a number of small wrinkles, mostly transverse in direction.

Behind this bare area lies a region formed of two low swellings, side by side, which present an appearance closely resembling the scrotal pouches of the male. As in that sex, it is divisible into two regions. The anterior one is nearly flush with the general perineal level, and is covered with dense, fine, backwardly directed hair, nearly white in colour. The posterior one swells above the perineal surface, and is covered with practically bare skin, dark grey or nearly black in colour. These "scrotal pouches" project from the body surface by reason of their contents of fibrous and adipose tissue. They are not so prominent as they are in some males with large testes in the scrotum, but they are indistinguishable from the condition found in those males in which the testes are not so prominently descended. They project sufficiently for a definite furrow to be formed at their posterior end. The part covered with light-coloured hair-tufts is about 1·3 cm. in antero-posterior length, and the bare part about 2 cm.

Behind the swellings lies the anal area, which is exactly similar in size and shape to that of the male. The anal glands form a similar swelling so that a blind pouch is formed below the root of the tail. The anus opens in the centre of the anal pouch, a circular depression about 2·5 cm. in diameter, into the posterior part of which the ducts of the anal glands open. The nipples lie about 5·0 cm. on each side of the middle line of the abdomen. The line joining them passes through, or a trifle anterior to, the anterior border of the base of the free part of the clitoris. Each lies on an areola of bare black skin, about 1·5–2·0 cm. in diameter. The nipples are practically indistinguishable from the rudimentary nipples of the male, and are about 5·0 mm. in diameter and length.

The nulliparous but sexually mature female (fig. 3 *b*)

The condition in the sexually mature female, that has not bred, differs only in the form of the clitoris. Both copulation and parturition take place through the extremity of the urinogenital canal, which, in the prepubertal animal, is situated at the tip of the glans clitoridis, and is no larger than the urethral meatus of the male. In the prepubertal state these functions are obviously impossible, owing to the minute size of the opening; and the differences found in the sexually mature animal are directed, teleologically speaking, towards facilitating their accomplishment. The prepuce undergoes considerable growth, so that it becomes slack and baggy, and the diameter of the base of the free part of the clitoris increases appreciably. The opening of the prepuce is thus much enlarged, so that it will admit two fingers, but the tissues preserve their elasticity, so that it does not hang open.

At the same time an interesting change takes place in the glans clitoridis. The fraenum preputii (fig. 4 *a*, *b*, *c*) becomes hypertrophied, and then the meatus of the urinogenital canal, situated at the tip of the glans, increases in size. The distal margin of it creeps down round the ventral surface of the glans, travelling down the mid-line of the fraenum preputii. Simultaneously the tip of the glans becomes more rounded and truncated, apparently owing to the enlarging meatus carrying the tip round with it towards the ventral surface. The process is one producing a condition similar to hypospadias. When it is complete, the meatus, instead of being a longitudinal slit 0·25 cm. long on the dorsal surface of the tip of the glans, is a longitudinal opening 1·5 cm. long, extending from near the tip of the now truncated glans, down the fraenum preputii, to the junction of the glans with the prepuce. The process is, in effect, the longitudinal splitting of the fraenum, so that the meatus is now bounded laterally by its two halves.

The growth of the tip of the glans clitoridis in a ventral direction results in the zone of spines on the dorsal surface being brought very much closer to the tip, and the glabrous area on the ventral surface being relatively larger.

In the nulliparous sexually mature animal there is practically no change in the mammary apparatus. The glands are still undeveloped, and the nipples are little, if at all, larger than in the prepubertal state.

The parous female

In the parous female the changes in the clitoris are carried a stage further, and the mammary glands and nipples reach their full development.

In the parous state the prepuce of the clitoris is greatly hypertrophied, so that in extreme cases it hangs in slack, baggy folds (fig. 3 *d*, *e*). It is greyish black in colour, and covered with small wrinkles. This extreme development of slack and flabby prepuce reaches its maximum at the time of parturition, and persists into lactation.

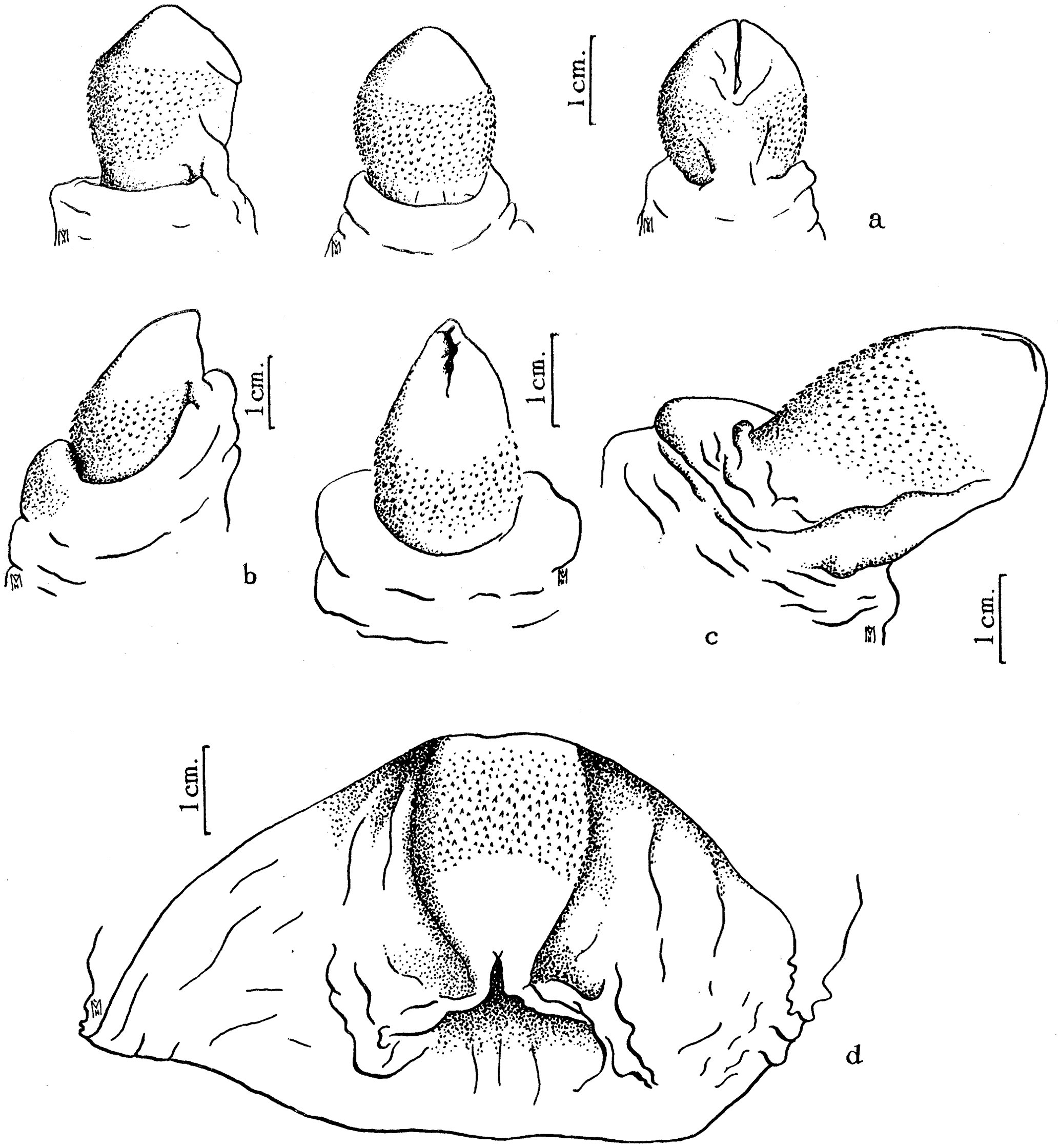

FIG. 4. Glans clitoridis of the female. *a*, *b*, *c*, prepubertal, approaching the first oestrus. Extension of the meatus down the ventral side of the glans, and splitting of the fraenum. *d*, parous, the prepuce opened dorsally, showing the two halves of the split fraenum.

It is very characteristic, and was noted in the field log-books as the "elephant condition". In anoestrus there is a diminution in size and a general tightening up of the folds of the prepuce. It returns towards the condition found in the nulliparous but sexually mature animal, but appears to be always slacker than in that state (fig. 3 *c*). The hypertrophy causes the base of the free part of the clitoris to increase, so that it measures from 3·75 to 5·25 cm. in diameter. At the height of lactation the swelling of the mammary glands is so great that the skin of the anterior surface of the prepuce may be drawn forward. The pendulous free part of the clitoris is thus enveloped, and the organ appears as a forwardly directed aperture lying between the posterior parts of the mammary glands (fig. 3*f*). The size of the opening of the prepuce is greatly enlarged, so that it will readily admit three or four fingers; but the elasticity of the tissues is such that, when unstretched, the opening is not more than 1·0–1·5 cm. in diameter. Lacerations of the margin of the opening are not uncommon, and on healing leave longitudinal splits in the end of the prepuce, sometimes with the addition of isolated tags and flaps.

In the parous state the enlargement of the meatus is carried a stage further than in the nulliparous animal that has reached sexual maturity. The hypospadiac condition increases, so that the opening of the urinogenital canal comes to lie ventrally to the glans clitoridis, in the fold at the junction of the glans and prepuce. The aperture is greatly enlarged, and, owing to the hypertrophy and slackness of the prepuce, it appears to be more transverse than longitudinal in direction, when the parts are unstretched. However, if it is suitably stretched, as described below, the opening is seen to be still truly longitudinal. The opening has crept down the fraenum preputii so as to split it. In consequence, the glans is attached ventrally to the prepuce by the two halves of the fraenum, each lying on one side of the opening of the urinogenital canal (fig. 4 *d*). If, then, the opening of the prepuce is stretched, the cavity appears to contain two chambers, a dorsal one containing the glans clitoridis, and a ventral one containing the opening of the urinogenital canal. The two chambers are separated by the two halves of the fraenum preputii, which appears to cross the cavity of the prepuce horizontally (fig. 5 *d*). The relation of the opening of the urinogenital canal and its true longitudinal direction are well shown in fig. 6. This represents the conditions found in a natural gas injection of the subcutaneous tissues, in a specimen in which decomposition had started. It is a condition which, of course, never occurs in the living animal, but it well illustrates the point under consideration. The gas has accumulated in the subcutaneous tissue surrounding the urinogenital canal, so that the clitoris is tightly blown up, and the skin very much stretched. The most elastic tissue, that surrounding the opening of the urinogenital canal below the glans clitoridis, has yielded most easily to the pressure, and is in consequence most inflated. The longitudinal direction of the opening of the urinogenital canal is clearly demonstrated: the epithelial lining of it is red, whereas that of the surrounding tissue, the internal epithelium of the prepuce, is black.

In the parous female, at the first lactation, the nipples are greatly increased in size (fig. 3 *c*, *d*, *e*, *f*). The areolae on which they are placed increase in diameter to 5·0–5·5 cm., and become conical in shape, rising to a height of about 1·5 cm. from the surface of the abdomen. They are covered with a number of roughly concentric furrows. The nipples grow to about 2·5 cm. in length, and 1·0–1·75 cm. in diameter. They are cylindrical, with bluntly rounded extremities, black in colour, and bear a number of wrinkles running in a direction transverse to their long axis. Owing to the swelling of the mammary glands the nipples are carried forward on the surface of the abdomen. The line joining their centres thus comes to lie from 3·0 to 4·0 cm. in front of the base of the free part of the clitoris, instead of level with it. The distance separating the centres of the nipples is also increased from 10·0 to 13·0 cm.

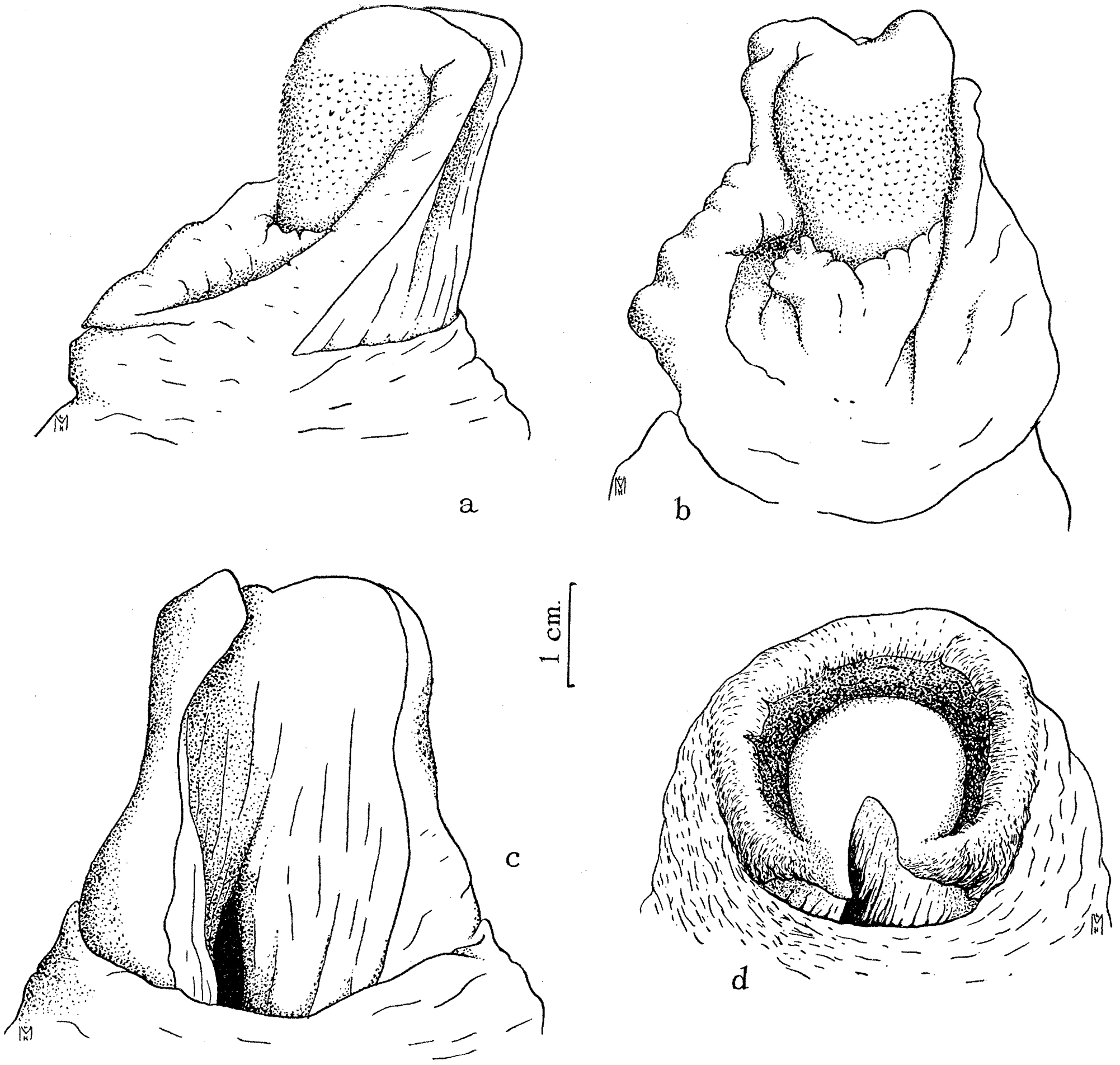

Fig. 5. Glans clitoridis in a parous female, with large, slack prepuce. *a*, *b*, *c*, lateral, dorsal and ventral views. *d*, end view showing the split fraenum crossing the cavity horizontally.

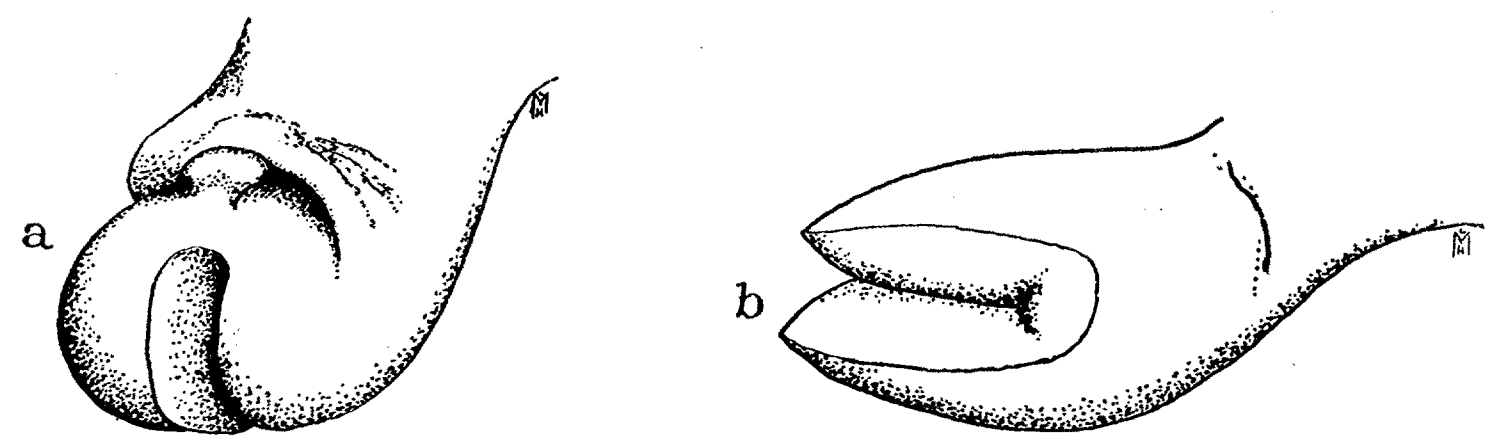

Fig. 6. Natural gas injection of the terminal part of the clitoris. *a*, oblique end view. *b*, ventral view. The gas has filled and distended the loose tissue in the fraenum and round the meatus. The meatus is shown to be longitudinal and not transverse in direction.

With the onset of lactation, supernumerary nipples, which are extremely inconspicuous in the nulliparous stage, undergo some development if they are present. They never attain the size of the functional nipples, nor are they so distinctly separated from the areolae, the conical shape of which is continued onwards to the tip of the nipple. The greatest development found in a supernumerary nipple was in one where the areola was 2·5 cm. in diameter and rose 0·5 cm. above the level of the abdomen, while the nipple was 0·7 cm. in diameter and 1·0 cm. long. The supernumerary nipples lie a short distance posterior, and internal, to the functional nipples, between them and the base of the clitoris. A symmetrically placed pair may be present, or there may be only one on one side (fig. 7). In the present series of animals they are recorded as being developed on both sides in three, and on one side only in one, out of twenty-two parous animals. They appear never to be functional, though one specimen was found in which an extra nipple looked as though it had been sucked by the young. It was placed in the area covered with short hair, just posterior to the free part of the clitoris. It was as large as any extra nipple seen, and appeared to have been sucked by the pups because the area surrounding it was completely denuded of hair, and presented a smooth surface pitted with coarse follicles. The nipple was considerably wrinkled and its general appearance gave the impression that, if not functional in yielding milk, it had certainly received much attention from the pups. During lactation the bare median area on the abdomen, between the anterior margin of the base of the clitoris and the umbilicus, is bounded laterally by the swollen mammary glands. They lie on each side of it, so that it appears as a groove of bare skin between them. In those specimens where the swelling draws the prepuce of the clitoris forwards the preputial opening looks forward along the gutter between the glands.

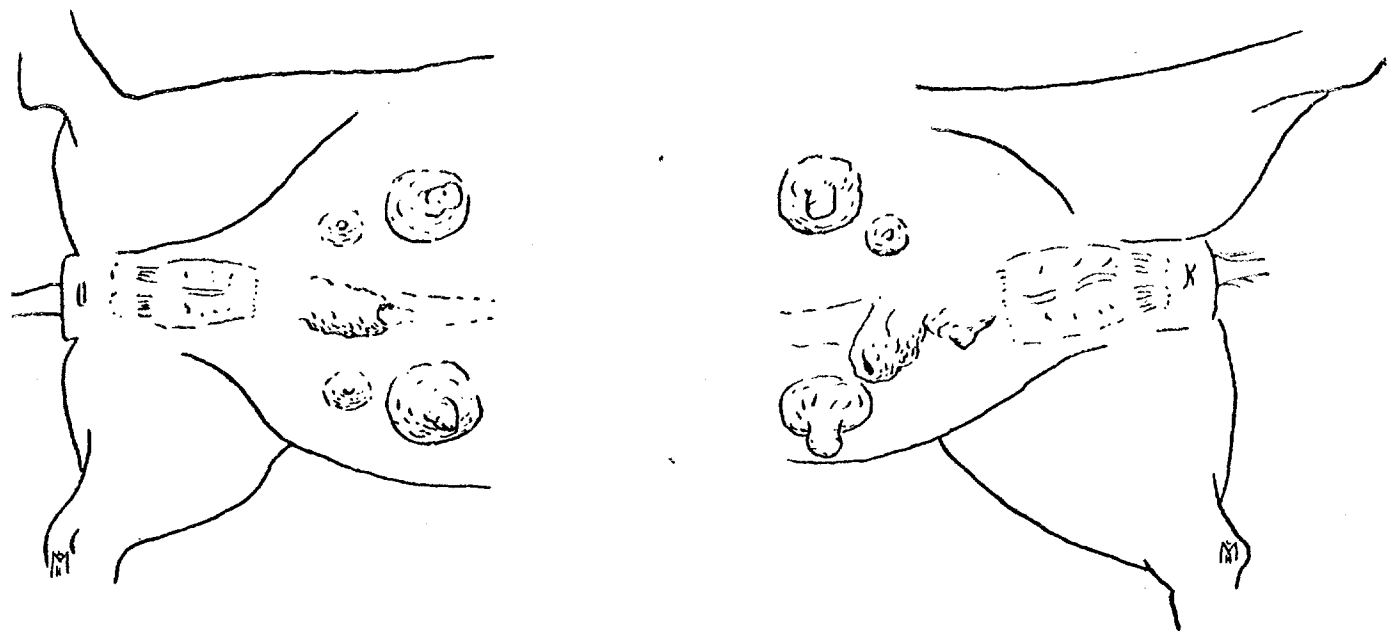

FIG. 7. Position of supernumerary nipples.

After lactation is completed the nipples regress a little in size. The areolae become not more than about 2·0 mm. in height from the surface of the abdomen, and the nipples about 13·0 mm. in length and diameter. There is, however, considerable variation in the degree of involution undergone. At all times the large size of the nipple in the parous animal at once distinguishes it from the prepubertal one, and from the male.

MACROSCOPIC ANATOMY OF THE INTERNAL GENITALIA

Watson (1877, 1878, 1879, 1881) has described the gross anatomy of the internal genitalia of the spotted hyaena, from several menagerie specimens. His observations do not agree in all respects with the results of an examination of the present series. The brief sketch given below of the form and relations of the parts is based on a careful study of the latter animals. Where the present writer differs in his findings from those of Watson the divergence is pointed out: for fuller details of the macroscopic anatomy the papers of Watson referred to above may be consulted. In the main his descriptions agree with the present writer's observations.

(1) THE MALE (figs. 8, 9)

The penis consists of two corpora cavernosa and a corpus spongiosum (fig. 10). Each corpus cavernosum arises just in front of the ischial tuberosity, and unites with that of the opposite side to form a single body which makes up the bulk of the penis. The corpora cavernosa are invested with a thick tunica albuginea of tough fibrous tissue. The two corpora are united throughout the length of the penis dorsally, but are separated ventrally by the urethra, which lies between them. The corpus spongiosum is a much smaller structure, and lies on the ventral side of the penis, surrounding the urethra. Posteriorly it expands to form the bulb of the urethra, which is covered by the bulbo-cavernosi muscles, and anteriorly it expands to form the glans penis. Except at its expanded ends it forms a very small mass of tissue surrounding the urethra; so small as to be barely visible in the middle region of the penis of many specimens. The penis in the present series varies in length from 14·5 to 19·5 cm., measured from the anterior part of the insertion of the ischio-cavernosi muscles to the tip of the glans. The muscles

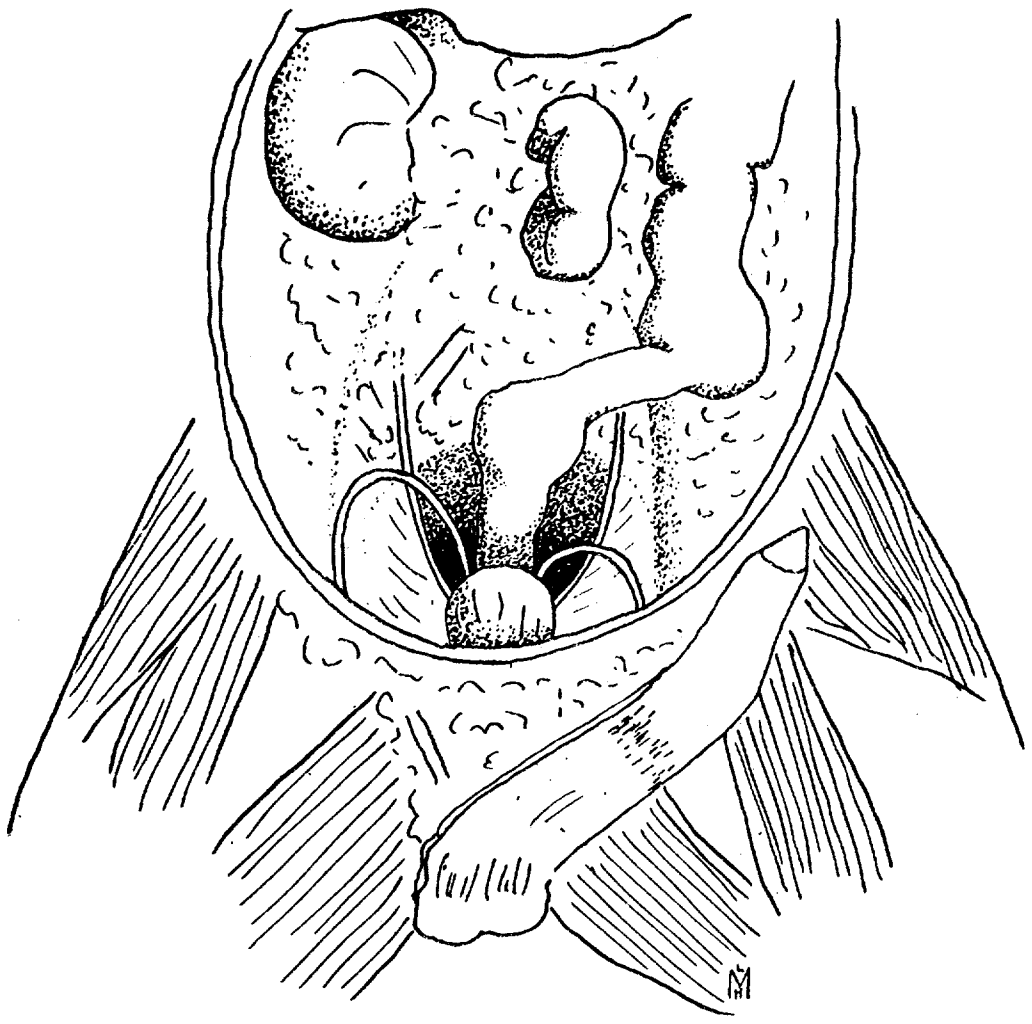

FIG. 8. General view of the pelvic contents in the male.

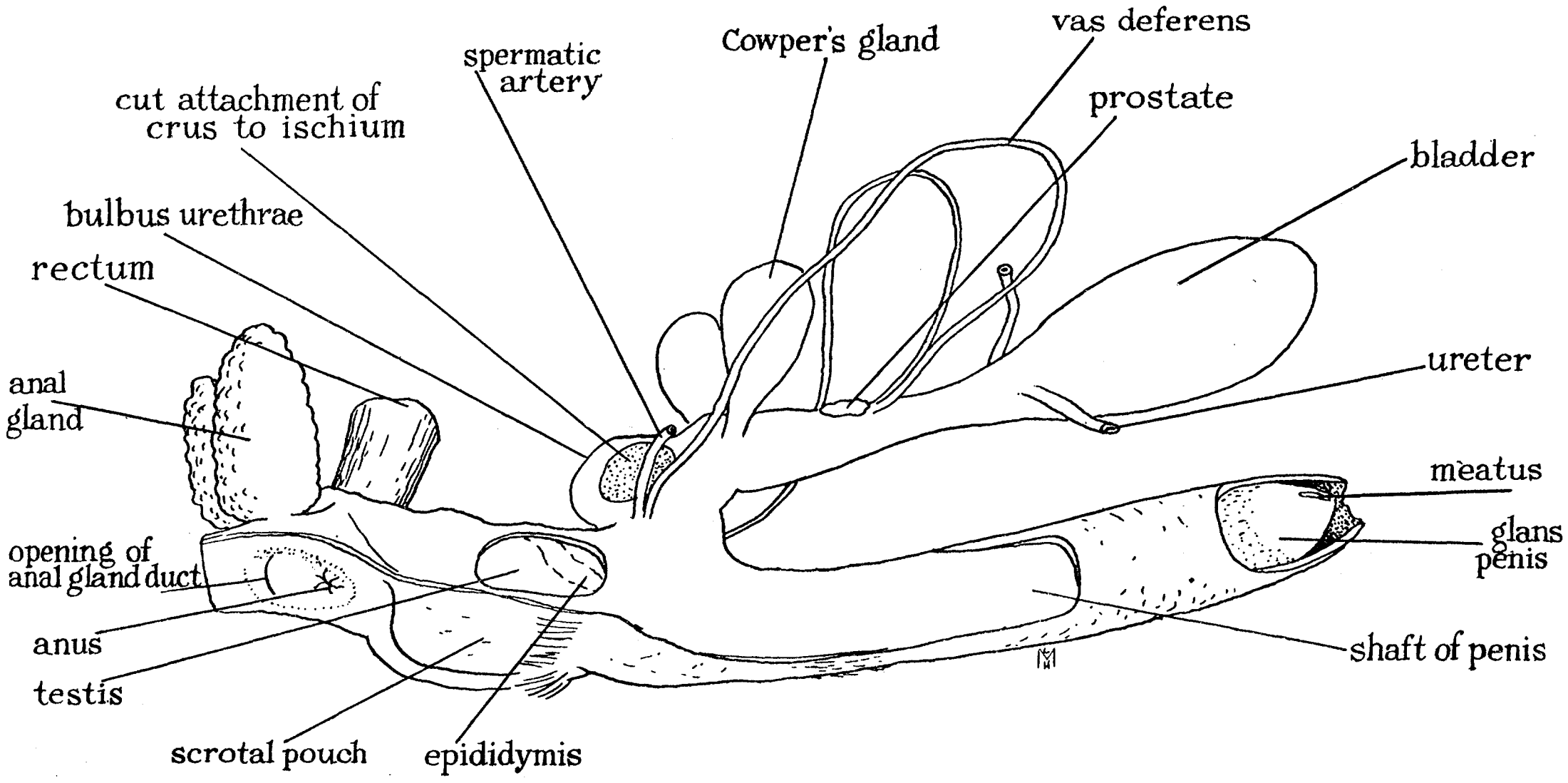

FIG. 9. Genitalia of the male.

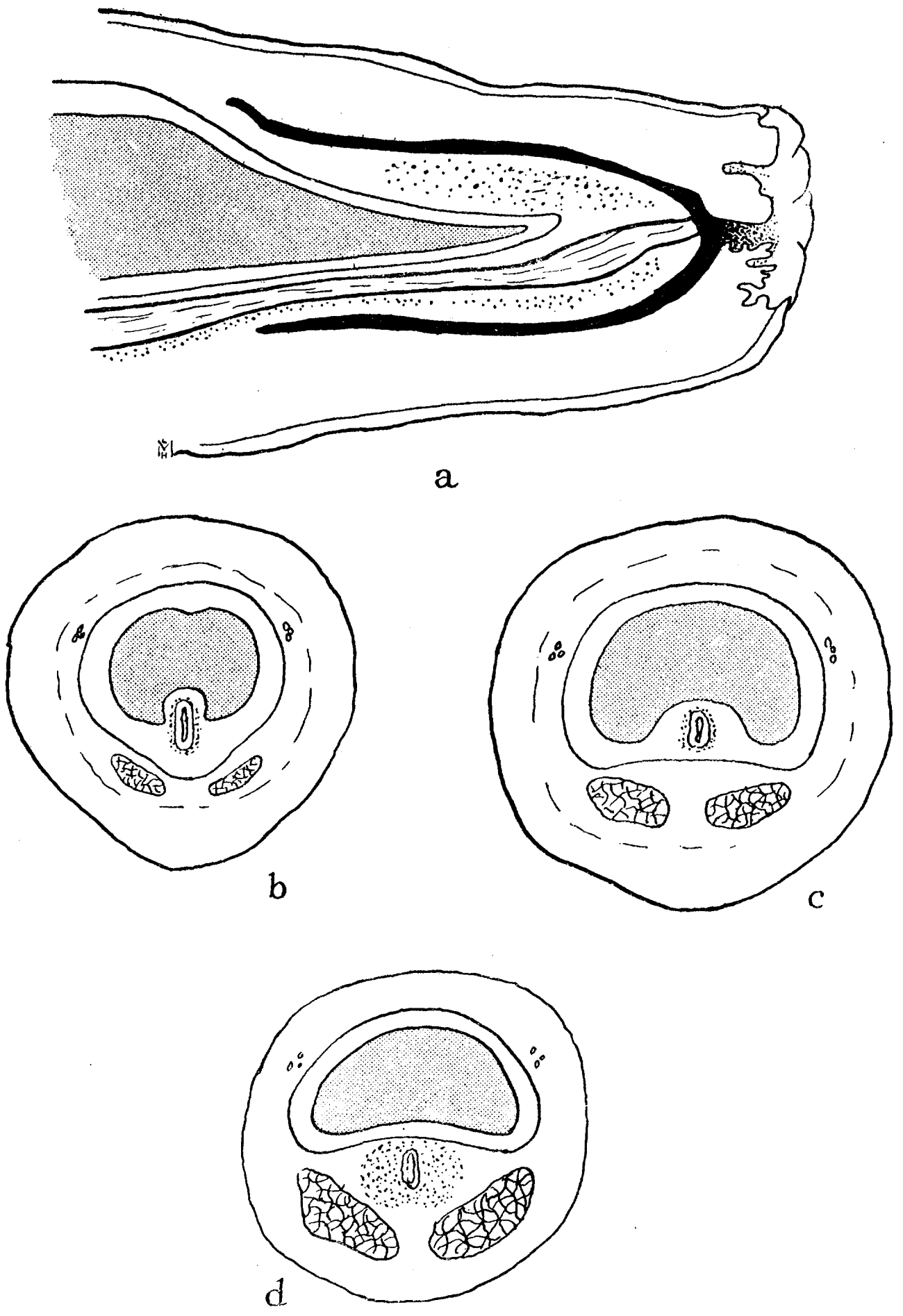

FIG. 10. Sections of the penis to show relations of structures. *a*, longitudinal section of end. *b*, *c*, *d*, transverse sections at base of glans, middle of shaft, and near base. Corpora cavernosa, fine stipple; corpus spongiosum, coarse stipple; m. retractor penis, cross-hatched.

of the penis, the ischio-cavernosus, bulbo-cavernosus, retractor penis and elevator urethrae, are, in the present series, as those described by Watson (1877), and call for no further comment here.

The membranous portion of the urethra measures about 8·0 cm. from the bulb of the penis to the neck of the bladder. The latter point, however, is not sharply delimited, for the bladder narrows gradually into the urethra, and the exact point of junction is indistinguishable. At about the middle of its length the membranous urethra receives the ducts of the large pyriform Cowper's glands. The glands are about 3·5 cm. in length and 2·0 cm. in width; their ducts are about 2·5 cm. long. About 2·0 cm. proximal to the neck of the bladder the ureters enter that organ, which measures, in the collapsed state, about 7·0 cm. from the termination of the ureters to its fundus.

The vasa deferentia enter the urethra about 1·0 cm. distal to the neck of the bladder. They unite just before entering the urethra, and form a minute common duct about 3 mm. in length. The duct terminates on the summit of a low longitudinal fold of the mucous membrane of the urethra. There are no vesiculae seminales. The vasa deferentia measure about 30·0 cm. in length, and pass through the inguinal canal, into the scrotal pouches, to join the tails of the epididymides. The cavity of the tunica vaginalis is continuous with that of the peritoneum, to which it is connected by a narrow duct.

The prostate varies greatly in size, as described below (p. 32). When fully developed it consists of two lobes, joined medially, lying dorsal to the urethra, at the junction of the vasa deferentia with it.

The scrotum is divided by a median septum into two pouches, each lined by the tunica vaginalis, which is reflected over the testis. The testis, in the fully mature adult, measures about 4·0 cm. in length and 2·0 cm. in width: the epididymis lies along its lower side, and consists of the enlarged head and tail joined by a narrow body.

The anal glands consist of a number of small lobes surrounding a central cavity. They measure about 6·0 cm. in antero-posterior length and about 3·0 cm. in width. They lie on each side of, and slightly above, the rectum, and are connected to the anal pouch by short ducts. Between them, and dorsal to the rectum, are a number of smaller glands, which open direct into the upper part of the anal pouch by separate ducts. The cavity of the anal glands contains a pasty secretion.

(2) THE FEMALE (figs. 11, 12, 13)

The clitoris, like the penis of the male, consists of two corpora cavernosa and a corpus spongiosum. The corpora cavernosa take origin immediately in front of the ischial tuberosity, and join to produce a single body, which forms the bulk of the clitoris. The dense fibrous tunica albuginea of the corpora cavernosa forms a septum between the two bodies for about the proximal third of their length. Distal to this it becomes incomplete, and then disappears, so that the two corpora are entirely fused towards their termination. They are more completely joined than in the male, and are not separated on their ventral surfaces by the urinogenital canal. Beneath the corpora cavernosa lies the corpus spongiosum. At its base it completely surrounds the urinogenital canal, forming a small bulb, comparable with the bulb of the urethra of the male. In the prepubertal animal the corpus spongiosum, through its course in the shaft of the clitoris, lies wholly above the urinogenital canal. It rapidly diminishes in size distal to its origin, so that towards the glans it is traceable only as three or four small veins, lying between the corpora cavernosa and the urinogenital canal. In the glans it is again expanded, and contributes a spongy mass towards the formation of the dorsal part of that structure,

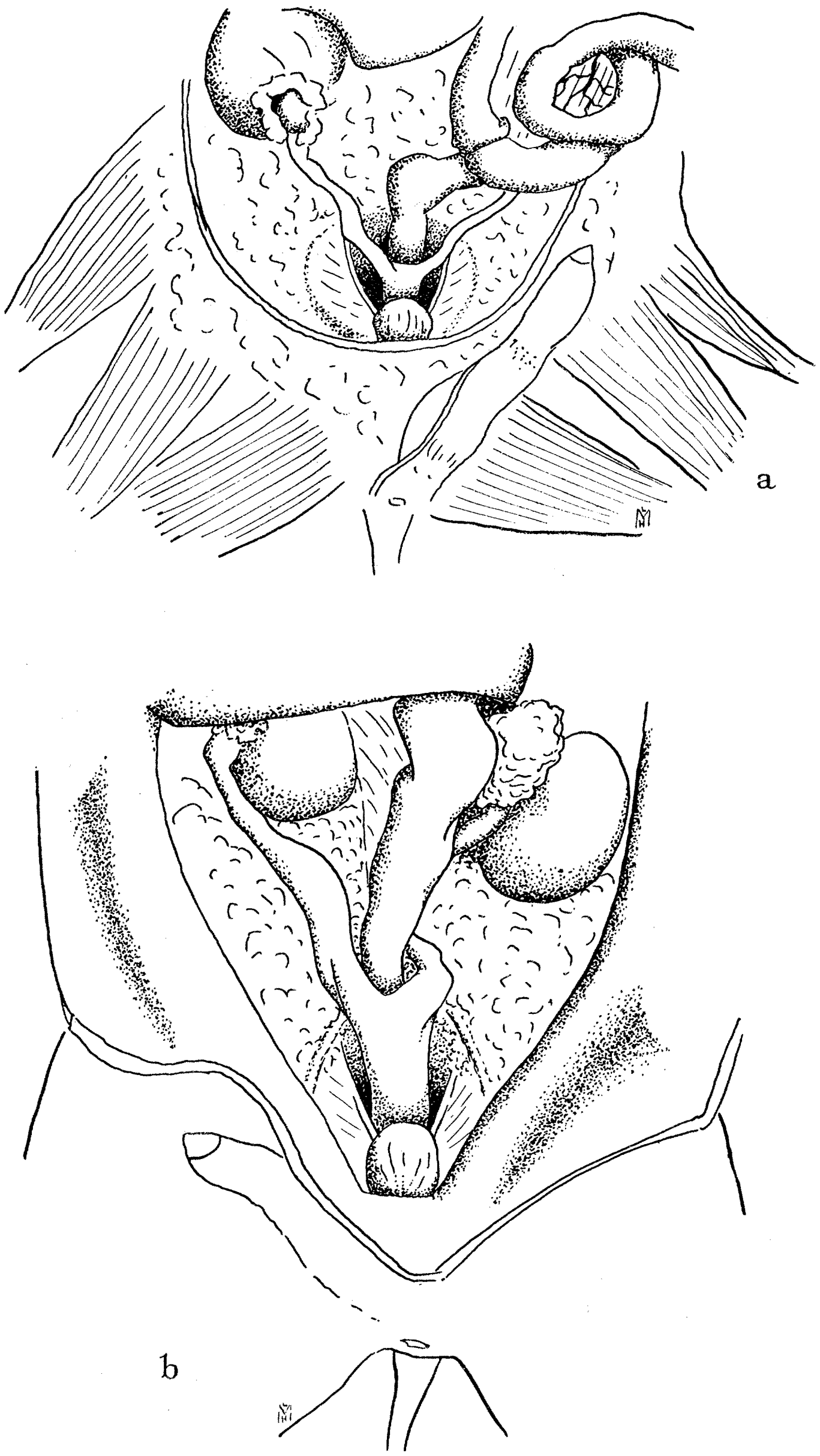

FIG. 11. General view of the pelvic contents of the female. *a*, prepubertal. *b*, parous.

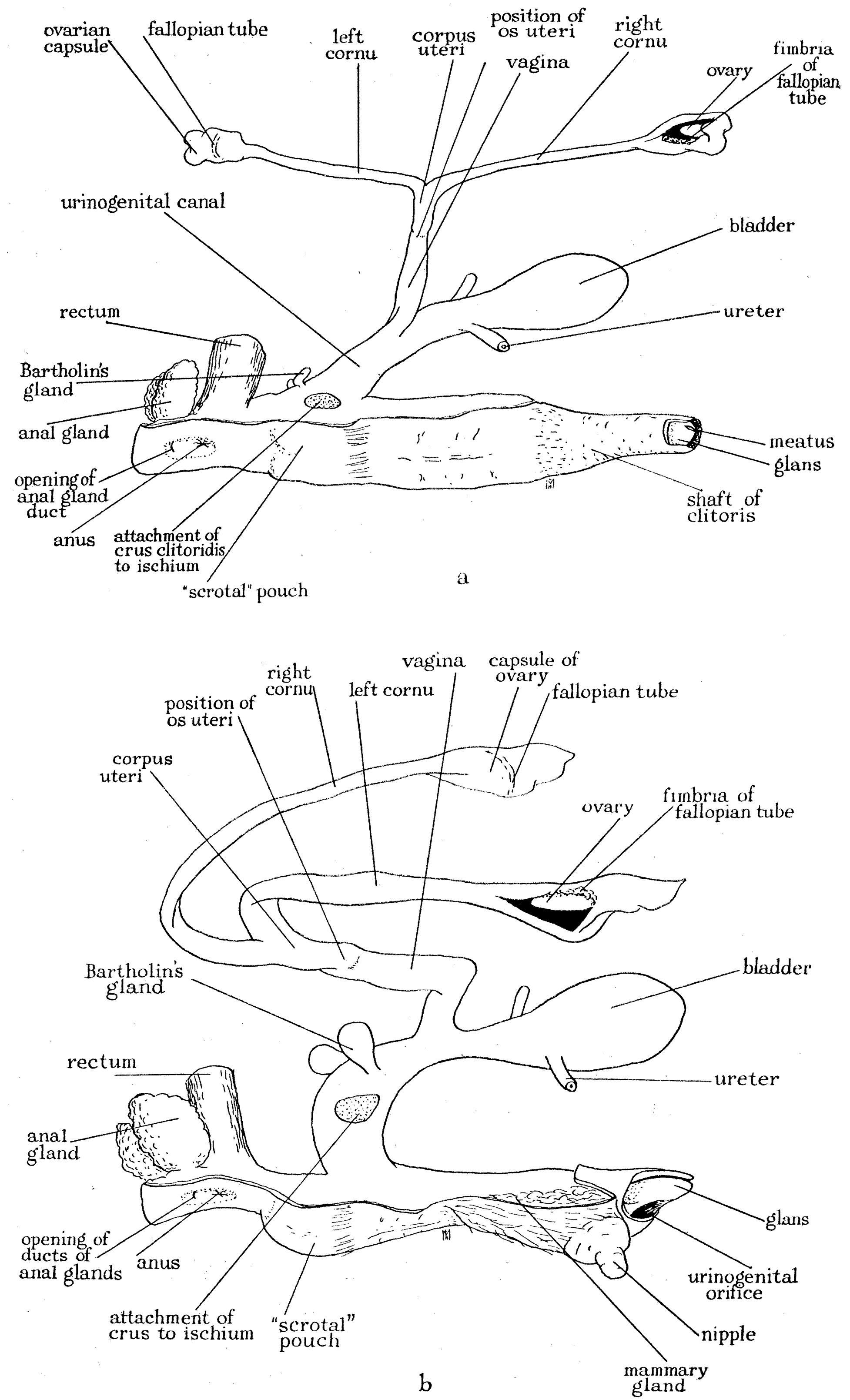

FIG. 12. Urinogenital organs of the female. *a*, prepubertal. *b*, parous.

above the corpora cavernosa. Watson (1877) was unable to make out the mode of termination of the corpus spongiosum, and stated that it did not contribute to the formation of the glans: he had examined only an immature specimen in which the structures were small.

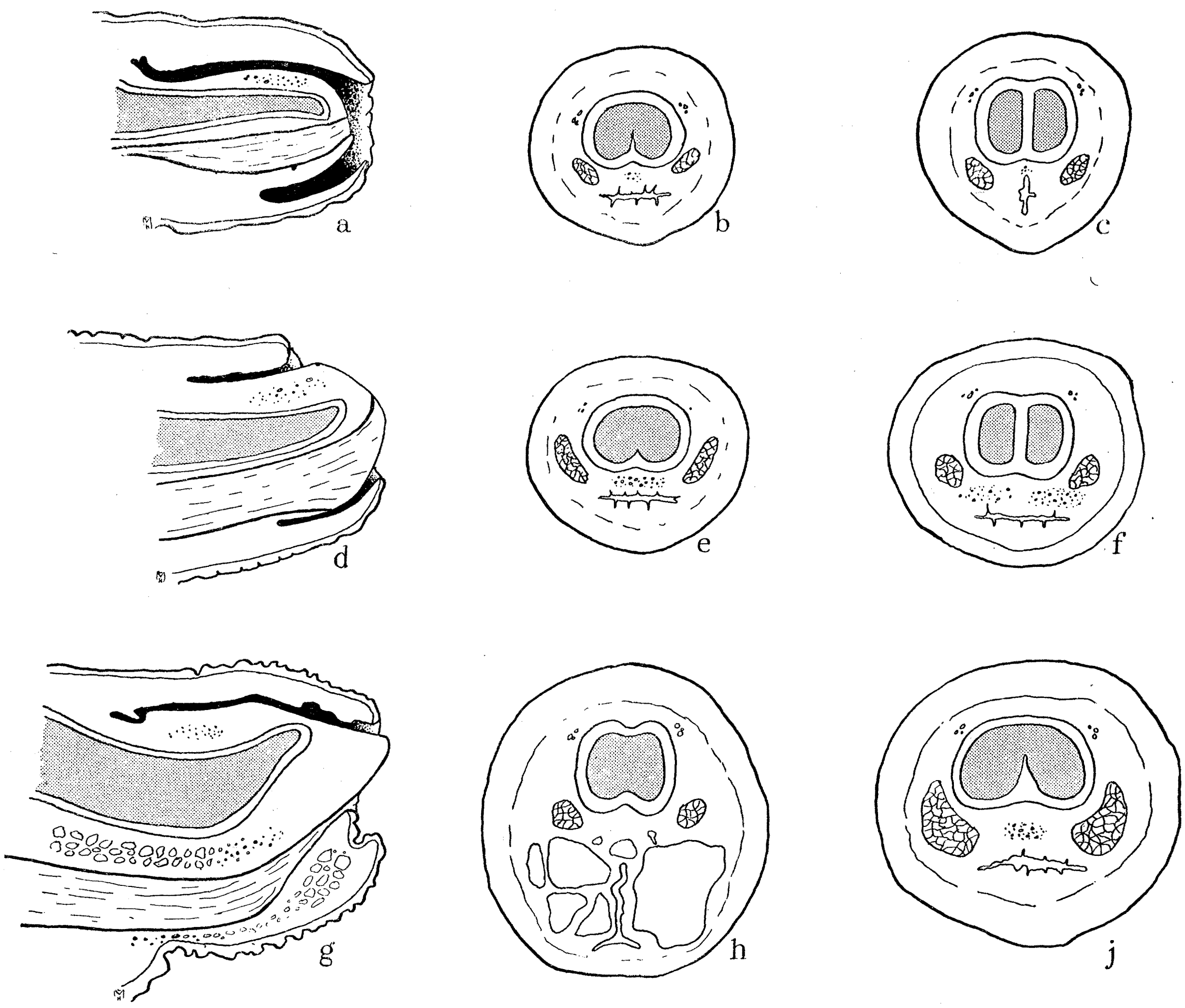

FIG. 13. The clitoris in section. *a*, *d*, *g*, longitudinal sections of the glans. *b*, *e*, *h*, transverse sections near the glans. *c*, *f*, *j*, transverse sections near the base. The corpora cavernosa are shown in fine stipple, the corpus spongiosum (except in *h* and part of *g*) by coarse stipple, and the m. retractor clitoridis by cross-hatching. In *h* and part of *g* the corpus spongiosum is shown as a number of venous sinuses surrounding the urinogenital canal. *a*, *b*, *c*, prepubertal; *d*, *e*, *f*, prepubertal on approach of first oestrus; *g*, *h*, *j*, parous.

The urinogenital canal is entirely ventral to the corpora cavernosa, and is larger in diameter than in the male, even in the prepubertal animal. It is expanded still further in the glans clitoridis. In the prepubertal animal the urinogenital canal fills the ventral part of the glans, beneath the end of the corpora cavernosa. The proximal portion of the dorsal part of the glans, above the corpora cavernosa, is filled by the termination of the corpus spongiosum. In the parous animal the dorsal wall of the urinogenital canal forms the ventral surface of the glans, between the halves of the longitudinally split fraenum preputii. The distal part of the corpus spongiosum surrounds the urinogenital canal with a mass of very loose spongy tissue or venous sinuses. In the distal part of the clitoris, then, it surrounds the urinogenital canal on all sides except the ventral. It thus approximates in its relationship with this structure to that of the corpus spongiosum with the urethra in the male. The corpus spongiosum thus contributes to the formation of the ventral part of the glans, below the end of the corpora cavernosa, which are sharply bent in a dorsal direction. Similarly, it contributes to the formation of the ventral part of the prepuce, which bounds the urinogenital orifice.

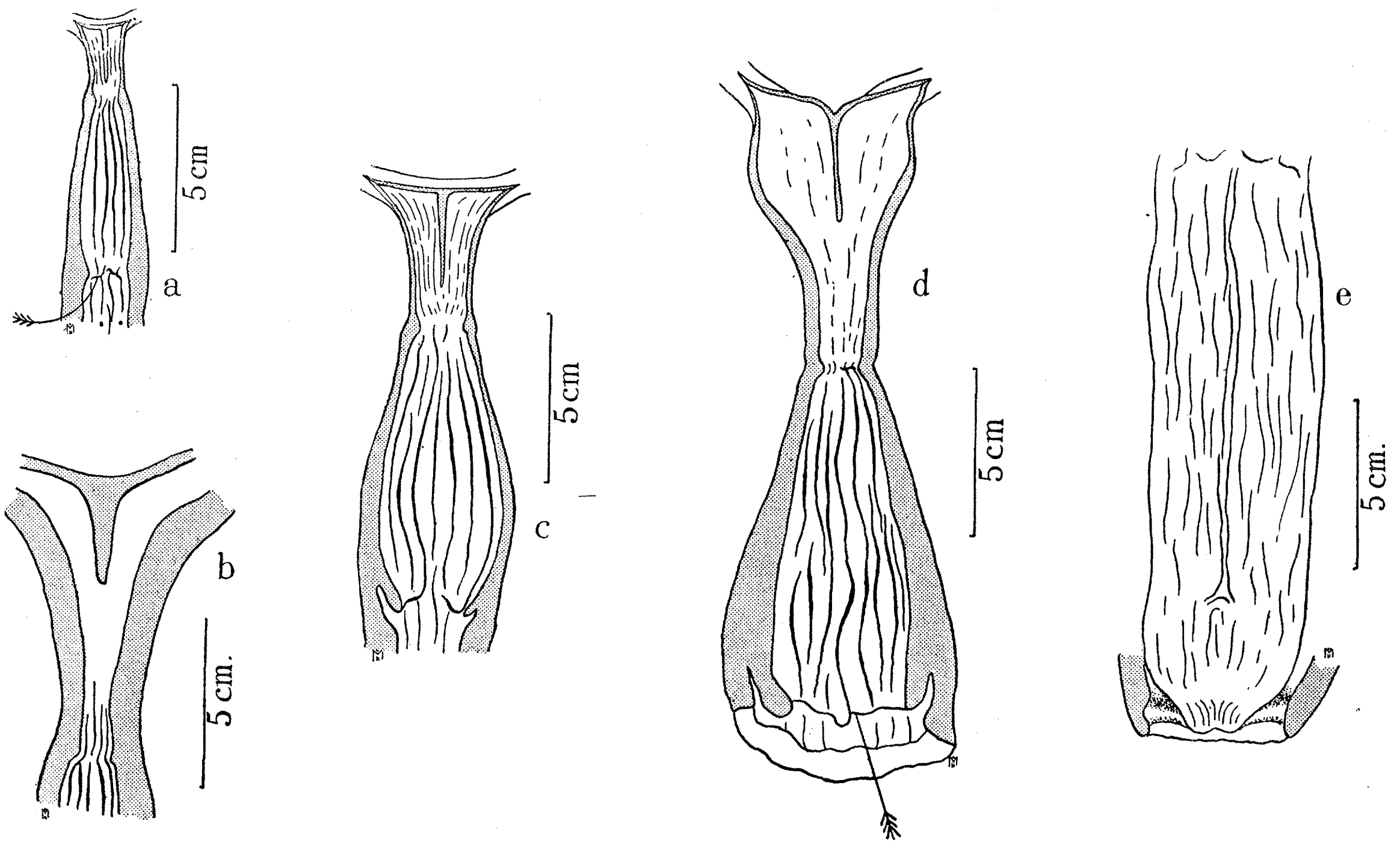

FIG. 14. Part of the urinogenital tract opened longitudinally, from the dorsal side (*a*, *b*, *c*, *d*) and ventral side (*e*). *a*, *c*, *d*, show the body of the uterus, with longitudinal septum, os uteri, vagina, hymenial fold, and part of the urinogenital canal. The arrows in *a* and *d* show the position of the opening of the urethra. *b*, the body of the uterus opened, showing an unusually short septum. *c*, the urinogenital canal from hymenial fold to external orifice opened on the ventral side. *a*, prepubertal; *b*, *c*, *d*, *e*, parous.

Proximal to the origin of the corpora cavernosa the urinogenital canal extends, for a distance of about 4·0 cm., to its junction with the urethra. In the parous animal its anterior and lateral surfaces are invested with a plexus of large venous spaces, which appear to communicate with the corpora cavernosa. At the junction with the urethra a large hymenial fold projects within the urinogenital canal, and appears to act as a valve preventing the contents of the bladder from penetrating into the vagina (fig. 14). The urethra is about 5·0 cm. in length, and passes insensibly into the bladder, without a definite constricted neck. The ureters enter the bladder 6·0–7·0 cm. proximal to the junction of the urethra and urinogenital canal. The bladder, when empty, is pyriform and about 7·0 cm. in length.

Watson (1877) was unable to determine at what point the body of the uterus ended, and thought that the junction of the urethra and the urinogenital canal represented the os uteri. Hence he reported that a vagina was absent in this animal, a statement that has been preserved in more general works (Marshall 1922). The part of the genital canal proximal to the junction of the urethra and urinogenital canal is, however, a true vagina. It varies in length from 6·0 cm. in the prepubertal female, to 13·0 cm. in the parous animal, its size depending upon the state of sexual activity in the individual. At its proximal end it is bounded by a low fold of mucous membrane which represents the os uteri. This fold is very much more conspicuous in some animals than in others: it is usually fairly obvious in the parous female, but in the prepubertal animal it may be very inconspicuous. That the part of the genital canal between the os uteri and the urinogenital canal is a vagina, and not part of the uterus, is shown definitely by a histological examination of its structure. The position of the os uteri can usually be made out externally by the presence of a slight thickening of the genital canal at its site. The mucous membrane lining the vagina is thrown into a number of longitudinal folds (fig. 14).

Between the os uteri and the junction of the uterine cornua lies the body of the uterus. Its cavity is divided by a longitudinal septum, of varying length, so that the lumina of the uterine cornua do not join until shortly before they reach the os uteri. The lining of the body of the uterus is thrown into a number of longitudinal folds, which are not, as a rule, nearly so prominent as those in the vagina. The body of the uterus ranges in length from 3·0 cm., in prepubertal animals, to 9·0 cm. in parous but not pregnant animals. This measurement is taken from the os uteri to the external junction of the cornua at the proximal end of the body of the uterus (fig. 14).

The uterine cornua join roughly at right angles to form the body of the uterus. The length of the two cornua together varies from 13·0 cm., in the prepubertal animal, to 27·0 cm., in the parous but not pregnant animal. This measurement is taken on fixed material, from the end of one cornu to that of the other when both are stretched out in a straight line on each side of the body of the uterus. Each uterine cornu is supported by a mesometrium forming the broad ligament, and by a round ligament which joins it towards its outer end. Each cornu diminishes gradually in diameter from the corpus uteri towards the outer end. Here it terminates abruptly, where it is joined by the fallopian tube and the uterine ligament of the ovary. The ovary lies within an ovarian capsule, the cavity of which communicates with that of the peritoneum through a slit-shaped opening 2·0–3·0 cm. in length, which faces dorsally, in the natural position of the parts. The walls of the capsule are almost invariably heavily loaded with fat. The ovary is attached to the uterine cornu and the posterior surface of the diaphragm by strong ligaments attached to one side of it. The fallopian tubes arise as much fimbriated funnels situated at the end of the capsular opening. They travel in a semicircular path down the anterior surface of the capsule, across its floor, and up its posterior surface, to join the ends of the uterine cornua. The fallopian tubes, when dissected out from the capsular wall and stretched out in a straight line, measure from 5·0 cm. in length, in prepubertal, to 13·0 cm., in parous, animals. The ovaries are ovoid in shape, and measure about 2·0 cm. in length in the parous animal when they contain no large corpora lutea. When young corpora lutea are present they are greatly increased in size.

The ducts of Bartholin's glands open into the urinogenital canal about 1·0 cm. proximal to the attachment of the corpora cavernosa to the ischium. The glands are large and pyriform, but, in parous animals, are only about half to three-quarters the size of the Cowper's glands of the male: in prepubertal animals they are very much smaller. Their ducts vary in length from about 1·0 to 1·5 cm.

The anal glands are similar in structure, position and size to those of the male; they are filled with a similar semi-solid secretion. Their ducts lead to the anal pouch, and open into it, as in that sex.

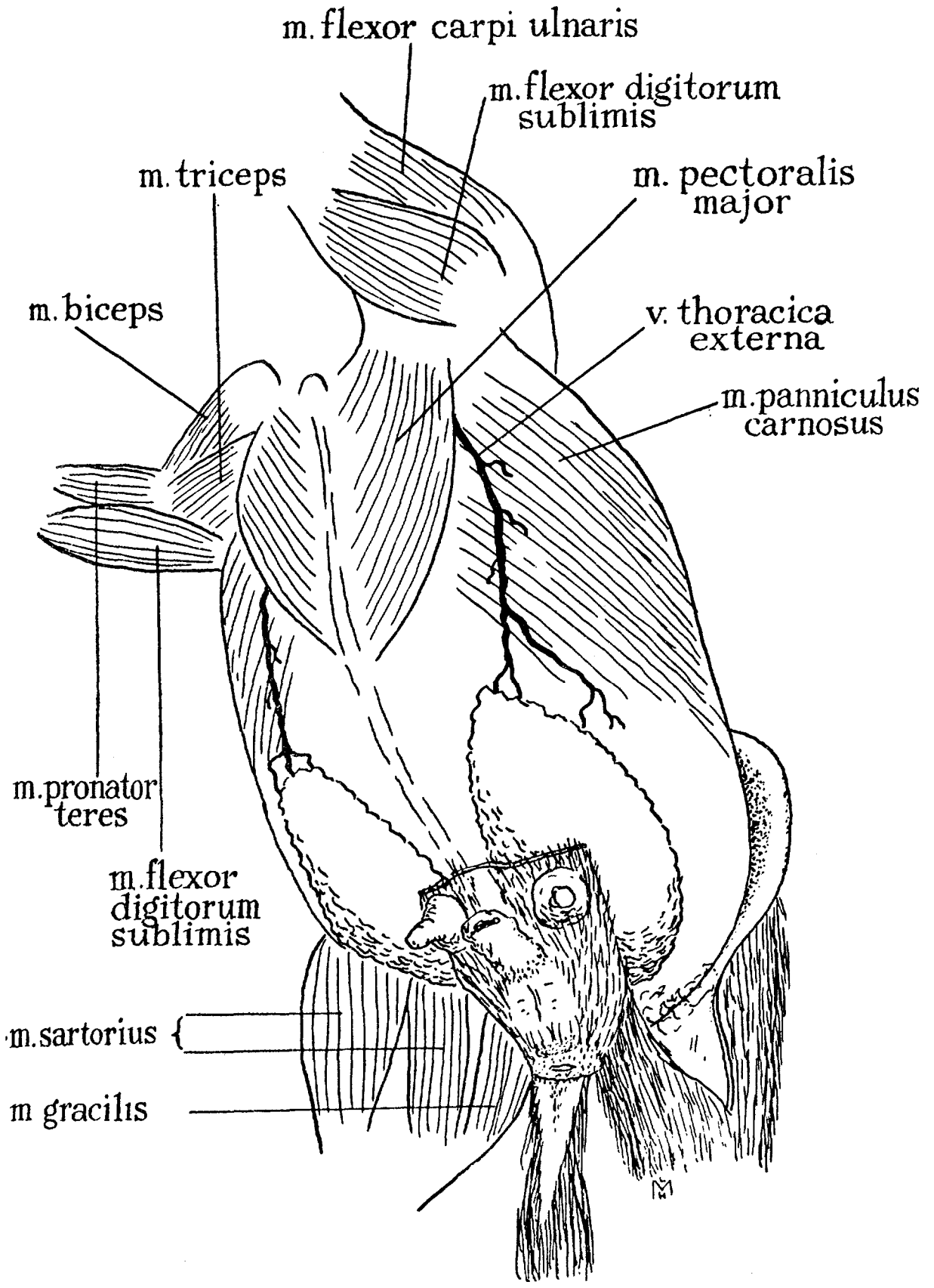

FIG. 15. Partly skinned carcase, showing the mammary glands and their relations during lactation.

The mammary glands in the prepubertal animal are indistinguishable by the naked eye. Only on microscopical examination can scattered strands of glandular tissue be made out, beneath the skin of the abdomen in the neighbourhood of the nipples. In the parous animal, with involuted mammary glands, they appear as small diffuse masses of glandular tissue scattered amongst the fat beneath the abdominal skin. When fully involuted they are very thin and difficult to recognize. During lactation they are greatly swollen (fig. 37, Plate 1). There is then a single mass of glandular tissue, lying on each side of the mid-line of the abdomen, and extending both anterior and posterior to the position of the nipple. The glands are longer than they are wide; they are flattened on the surface applied to the abdominal wall, and rise in a gentle convexity to the nipple on their outer surfaces. The mammary gland of an animal in full lactation measured 26·0 cm. in length, 10·0 cm. in breadth, and 5·0 cm. in thickness, after it had been hardened in formalin. The gland extended for a distance of 12·0 cm. posterior to the centre of the nipple, and 14·0 cm. anterior to it. It extended laterally 3·0 cm. from the centre of the nipple towards the mid-line of the abdomen, and 7·0 cm. outwards. A large vein, formed by the junction of several smaller tributaries, runs forwards from the anterior end of the gland on each side. It traverses the ventral surface of the abdomen and thorax, and dips inwards between m. pectoralis major and m. panniculus carnosus in the region of the axilla (fig. 15). It is very prominent and conspicuous during lactation.

THE SEXUAL CYCLE

(1) The male

Sexual activity in relation to age and size

Microscopic examination of sections of the testes and epididymides of the male hyaenas of the present series shows that some of the animals were in full sexual activity and some were not. There does not, however, appear to be any definite sexual season, and the degree of sexual activity depends thus upon individual factors, two of which are the age, and the size, of the animal. Examination of the skull throws some light on the age of the animals. In particular, the state of closure of the fronto-parietal and basilar sutures, and the amount of tooth-wear are helpful. As physical maturity is approached the basilar suture first closes, and later the fronto-parietal, when the occipital crest is developed. It was found convenient to divide the stages of tooth-wear into arbitrary groups from nil to 3/4, the last stage including aged individuals in which those teeth that had not been lost were worn down practically to the gum. Table I shows the relationship between suture closure and the amount of tooth-wear, the numbers in each box showing the numbers of specimens in each category. It shows that physical maturity, as shown by the closure of both the fronto-parietal and basilar sutures, occurs when the teeth have reached the stage of at least one-quarter worn, and usually when they are between one-quarter and one-half worn. This does not necessarily imply that physical maturity is reached at a late age, because the teeth begin to show signs of wear almost as soon as the series is completely erupted.

Using the above criteria, the material falls into the following groups:

(1) *Sexually inactive.*

No spermatozoa are present in testis or epididymis. Body size usually small: only three specimens with head-and-body length over 1100 mm. come within this class. Both basilar and fronto-parietal sutures open; tooth-wear small, never more than 1/4.

(2) *Sexually active.*

Testis and epididymis full of spermatozoa.

(*a*) Adults not physically mature. The basilar suture closed, but the fronto-parietal suture open. Tooth-wear about 1/4.

(*b*) Adults, physically mature. Both basilar and fronto-parietal sutures closed; tooth-wear at least 1/4, usually more.

TABLE I. MALES: SUTURE CLOSURE AND TOOTH-WEAR

Both closed			2			14		4
Basilar suture closed, fronto-parietal open		3	26		1			
Both open	5	1	3					
Tooth-wear	0	1/4 –	1/4	1/4 +	1/2 –	1/2	1/2 +	3/4

(3) *Intermediate.*

Testis and epididymis with little or only a moderate quantity of spermatozoa; or testis full, but epididymis with few or no spermatozoa; or epididymis full, but testis with few or none.

(*a*) Immature physically. Both basilar and fronto-parietal sutures open. Tooth-wear 1/4, or less.

(*b*) Adults not physically mature. The basilar suture closed, but the fronto-parietal suture open. Tooth-wear about 1/4.

(*c*) Adults, physically mature. Both basilar and fronto-parietal sutures closed. Tooth-wear at least 1/4, and usually more.

The number of animals falling within these groups is shown in Table II. A consideration of these groups shows that sexual activity is reached before physical maturity, and that closure of the basilar suture is associated with the attainment of puberty, whereas closure of the fronto-parietal does not occur until later. Three-quarters of the younger animals with both sutures open are prepubertal, and the remaining quarter are not in full sexual activity. Two-thirds of the animals having the basilar suture closed are in full activity, the other third is in the intermediate stage: none of them is completely inactive. These results are shown graphically in fig. 16 where the percentages of the total numbers falling into the three classes are plotted separately against the three divisions of sexual activity. This figure shows clearly that all the pubertal adults, whether they had reached complete physical maturity or not, were in some stage of sexual activity, and that most of the animals still showing active body growth were prepubertal.

TABLE II. MALES. NUMBERS OF ANIMALS, EXPRESSED AS PERCENTAGES OF THE TOTAL, FALLING WITHIN THE THREE GROUPS ACCORDING TO SEXUAL ACTIVITY, AND ACCORDING TO CLOSURE OF THE CRANIAL SUTURES

	Sutures		
Group	Both open	Basilar closed, fronto-parietal open	Both closed
Sexually inactive. No sperm in testis or epididymis	15·8	—	—
Intermediate. Testis and/or epididymis with no sperm	5·2	21·0	5·2
Sexually active. Testes and epididymes full of sperm	—	24·8	28·0

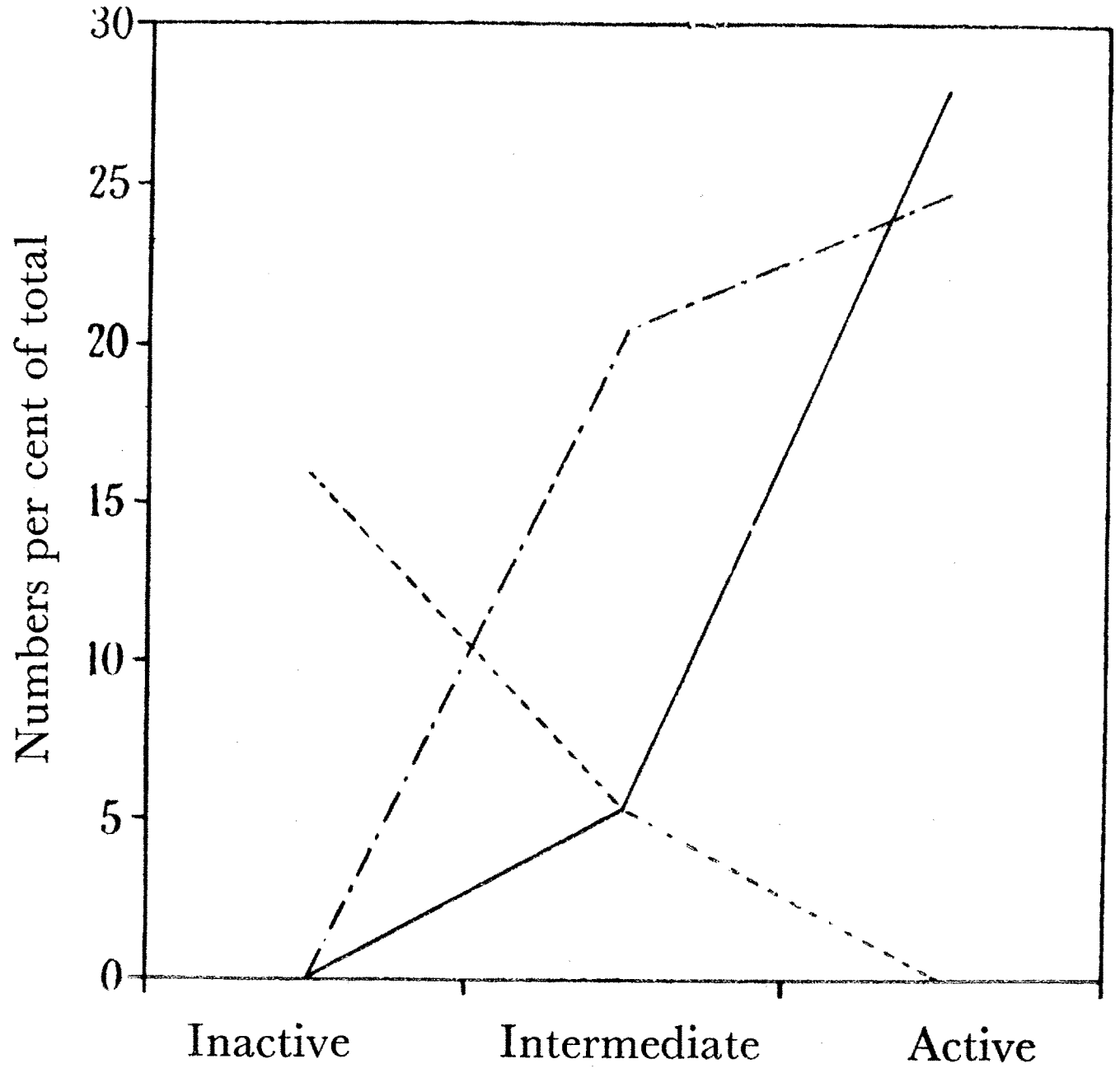

– – – – – Basilar and fronto-parietal sutures open.
—·—·— Basilar suture closed but fronto-parietal suture open.
———— Both sutures closed.

FIG. 16. Males. Numbers in the different classes of sexual activity.

Turning now to the relationship between the length of body and the amount of tooth-wear, Table III shows this correlation for all the animals, irrespective of sexual maturity. This information is further analysed in Tables IV and V, in which the numbers of prepubertal and mature animals are separated, those in full and intermediate sexual activity being further separated in Table V. This shows that the prepubertal animal may be separated by the small amount of tooth-wear, and that sexual activity is reached at a head-and-body length of about 110 cm., and physical maturity at about 120 cm. These values are confirmed by the figures given in Table VI, which shows the mean value, and the range of variation, of the head-and-body length in the three classes of sexual activity.

TABLE III. MALES. RELATION OF TOOTH-WEAR TO LENGTH OF HEAD AND BODY

Length of head and body in cm.	Tooth-wear: 0	1/4−	1/4	1/4+	1/2−	1/2	1/2+	3/4
120–130			9			8		2
110–120	1	2	16		1	4		2
100–110	4	1	5			2		
90–100								
80–90	1							

Sizes and weights of the genitalia

Turning now to the weights of the various organs of the genitalia, it will be convenient to take the weight of the testes as the standard with which to compare the other organs. The testis weight used is that of the two testes of each animal after removal of the epididymides, vasa deferentia, and the fat and connective tissue at the origin of the spermatic cord.

Comparing this value first with the body size, fig. 17 shows the testis weight plotted against the head-and-body length. Figures of body weights are not available, and so the head-and-body length, measured in a straight line from tip of snout to the insertion of the tail, is taken as the best indication of body size. This figure shows that the size of the testes increases with increasing body size. The growth is rapid at first until sexual maturity is reached, at a head-and-body length of about 110 cm., and continues at nearly the same rate until physical maturity is reached at a corresponding value of about 120 cm. Thereafter further growth does not take place. As would be expected, the testis weight is much less in sexually inactive than in sexually active animals. The average weight of the two testes in those animals having no spermatozoa in the testes or epididymides is 4·07 g., with extremes of 2·32 and 7·45 g. The corresponding figures for animals in the intermediate stage of sexual activity are, average 8·84 g., extremes 4·32 and 17·67 g.; those for animals having both testes and epididymides full of spermatozoa are, average 10·35 g., extremes 5·85 and 16·00 g. The weight of the testes thus delimits the inactive class fairly well. The other classes, though the average weights show a progressive increase, are not so sharply marked, owing to the very wide range of variation within each of them. In fact, it may be said that after reaching puberty the weight of the testes bears little relation to their state of activity.

TABLE IV. MALES. RELATION OF HEAD-AND-BODY LENGTH IN PREPUBERTAL AND SEXUALLY MATURE ANIMALS: NUMBERS OF ANIMALS

Head-and-body length in cm.		0	1/4 −	1/4	1/4 +	1/2 −	1/2	1/2 +	3/4
Mature	120–130			9			7		2
	110–120	1	2	13		1	4		2
	100–110	1	1	3			2		
	90–100								
	80–90								
Prepubertal	120–130								
	110–120	1		2					
	100–110	3		2					
	90–100								
	80–90	1							

Tooth-wear

Considering now the testis weight when compared with that of the other organs of the genitalia, we find that a diagram similar to that of fig. 17 is shown in fig. 18, where the testis weight is plotted against the weight of the penis. The ratio thus demonstrated shows that the weight of the penis is fairly closely correlated with the general increase in body size as the animal grows up. The slightly steeper location of the points near the origin may indicate a more rapid growth on reaching puberty.

TABLE V. MALES. RELATION OF HEAD-AND-BODY LENGTH TO TOOTH-WEAR IN ANIMALS IN FULL AND INTERMEDIATE SEXUAL ACTIVITY: NUMBERS OF ANIMALS

Head-and-body length in cm.		Tooth-wear: 0	1/4−	1/4	1/4+	1/2−	1/2	1/2+	3/4
Full activity	120–130			5			7		1
	110–120			9		1	3		
	100–110			2			2		
	90–100								
	80–90								
Intermediate	120–130			4					1
	110–120	1	2	4			1		2
	100–110	1	1	1					
	90–100								
	80–90								

TABLE VI. MALES. HEAD-AND-BODY LENGTH ACCORDING TO SEXUAL ACTIVITY

	Head-and-body length in cm.		
Group	Minimum	Maximum	Average
Prepubertal	86·4	117·0	106·5
Intermediate activity	104·2	125·8	116·0
Full activity	106·7	129·5	119·1

The growth of the epididymides shows a close correlation with that of the testes, as is well brought out in fig. 19, though there is some indication that the epididymides reach their maximum weight slightly before the testes. Similarly fig. 20 shows a fairly close correlation between the weight of the vasa deferentia and that of the testes, though fewer values are available for constructing the diagram. On comparing this figure with fig. 19, the vasa deferentia are seen to have a much slower relative growth rate than the epididymides.

The other organs weighed do not show any conspicuous correlation in size with that of the testes. Fig. 21 shows the weights of Cowper's glands plotted against those of the testes. There is some degree of correlation between the weights of the two organs in the lower values, but the points for the higher values are very scattered and show no obvious relationship. In one specimen Cowper's glands appeared to be absent. The animal was

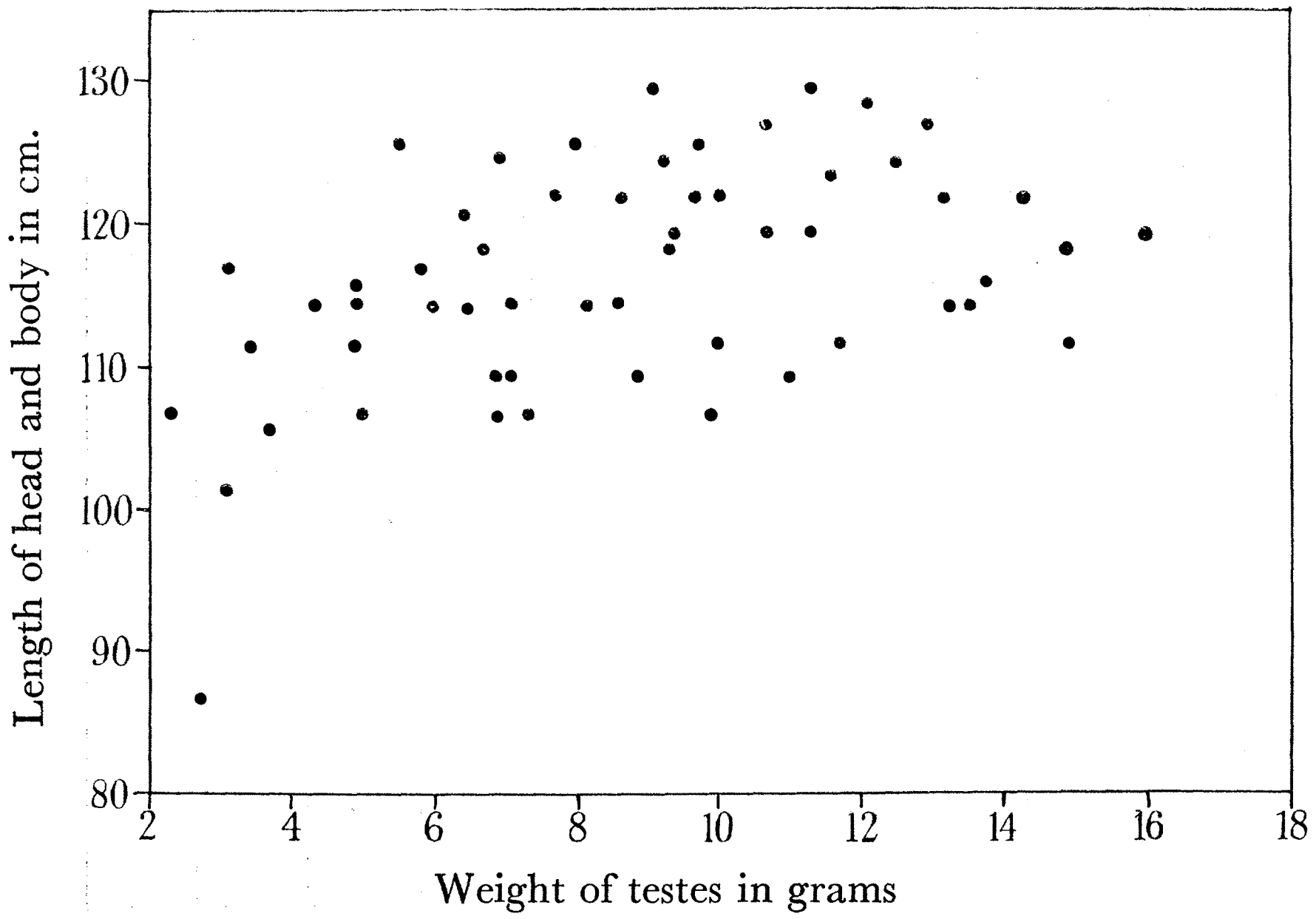

Fig. 17. Males. Weight of testes in relation to length of head and body.

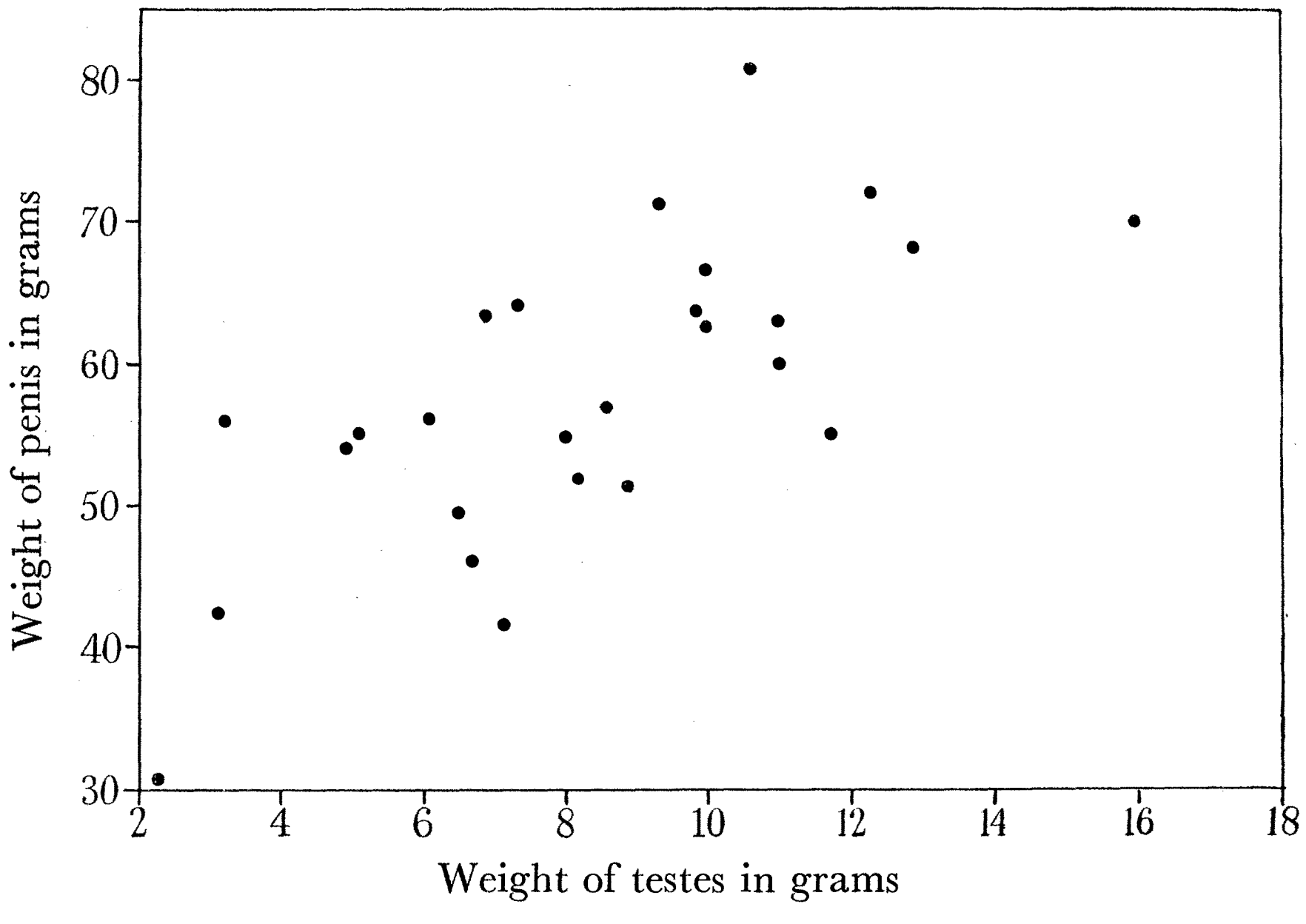

Fig. 18. Relation between weights of testes and of penis.

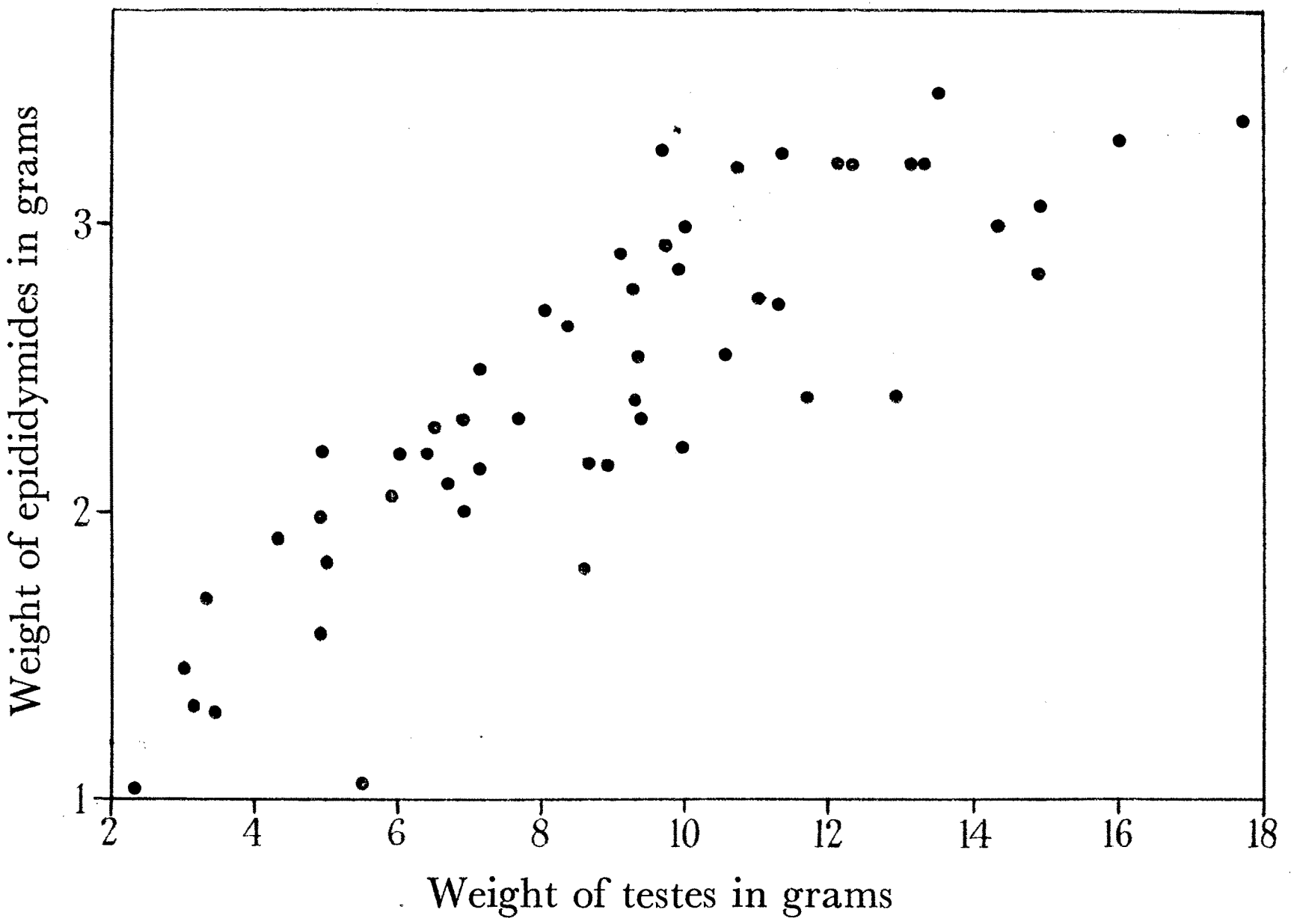

FIG. 19. Relation between weights of testes and of epididymides.

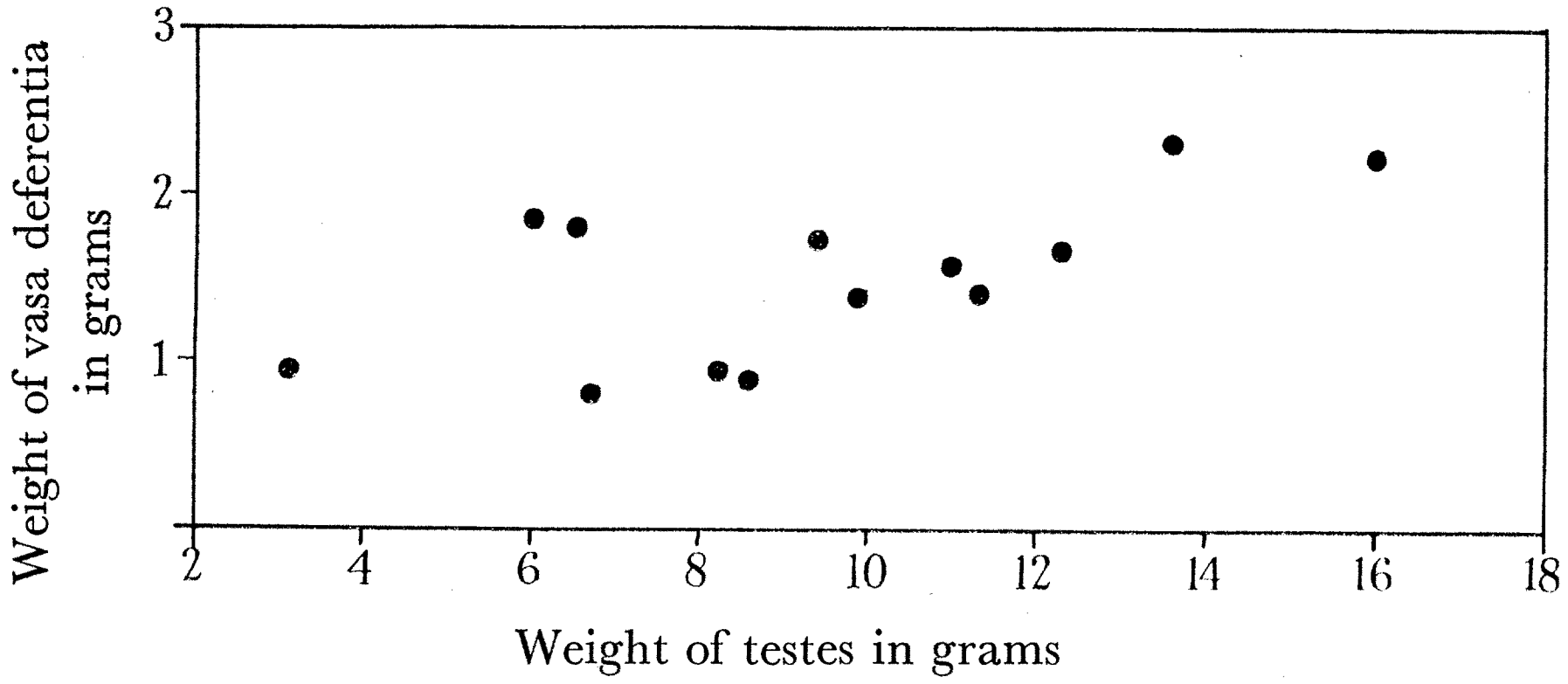

FIG. 20. Relation between weights of testes and of vasa deferentia.

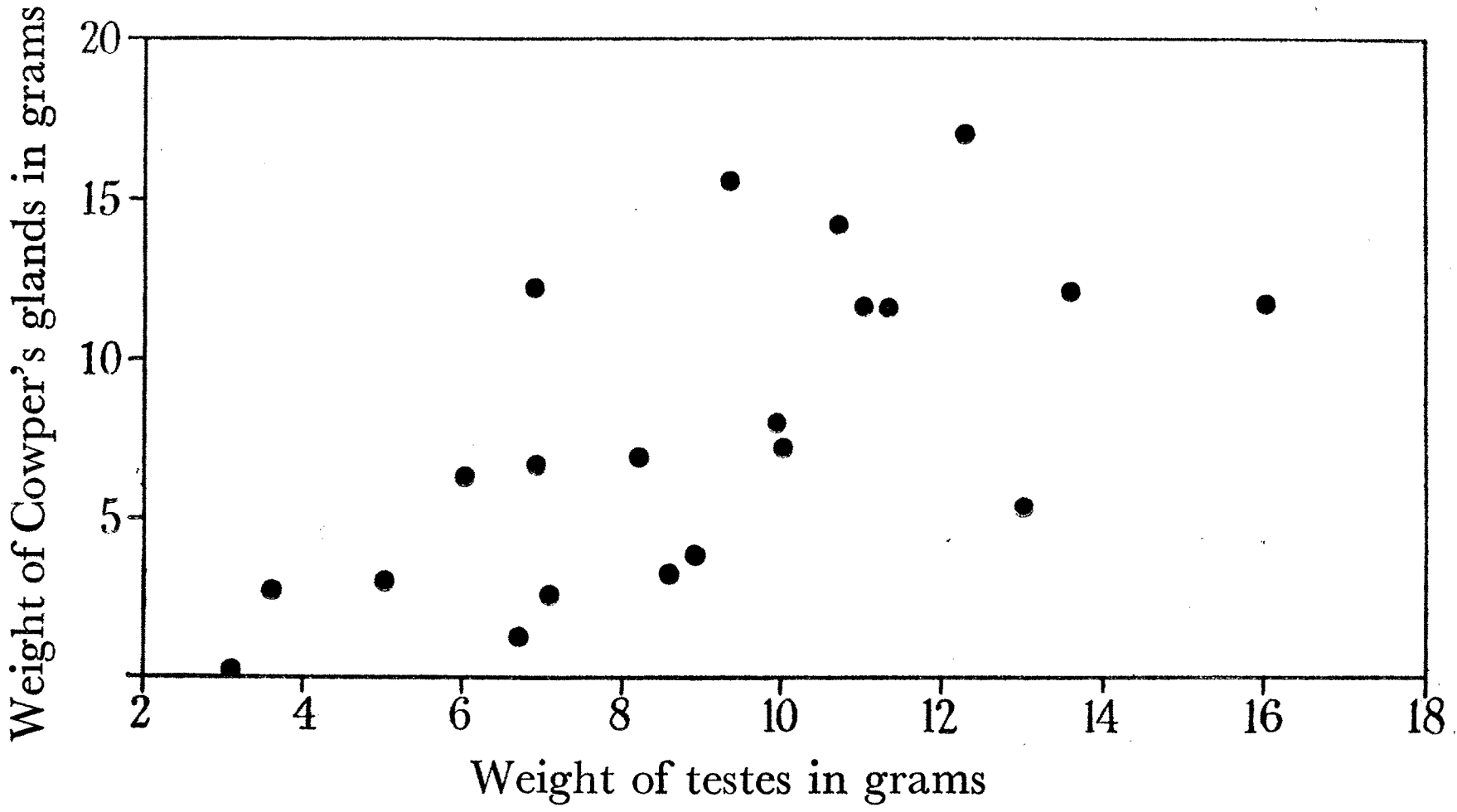

FIG. 21. Relation between weights of testes and of Cowper's glands.

a young one, with head-and-body measurement of only 101·7 cm., no tooth-wear, and open basilar and fronto-parietal sutures. It had not reached puberty. The glands may have been present as very small structures, obscured by the large quantity of connective tissue surrounding the urethra, but careful dissection failed to display them.

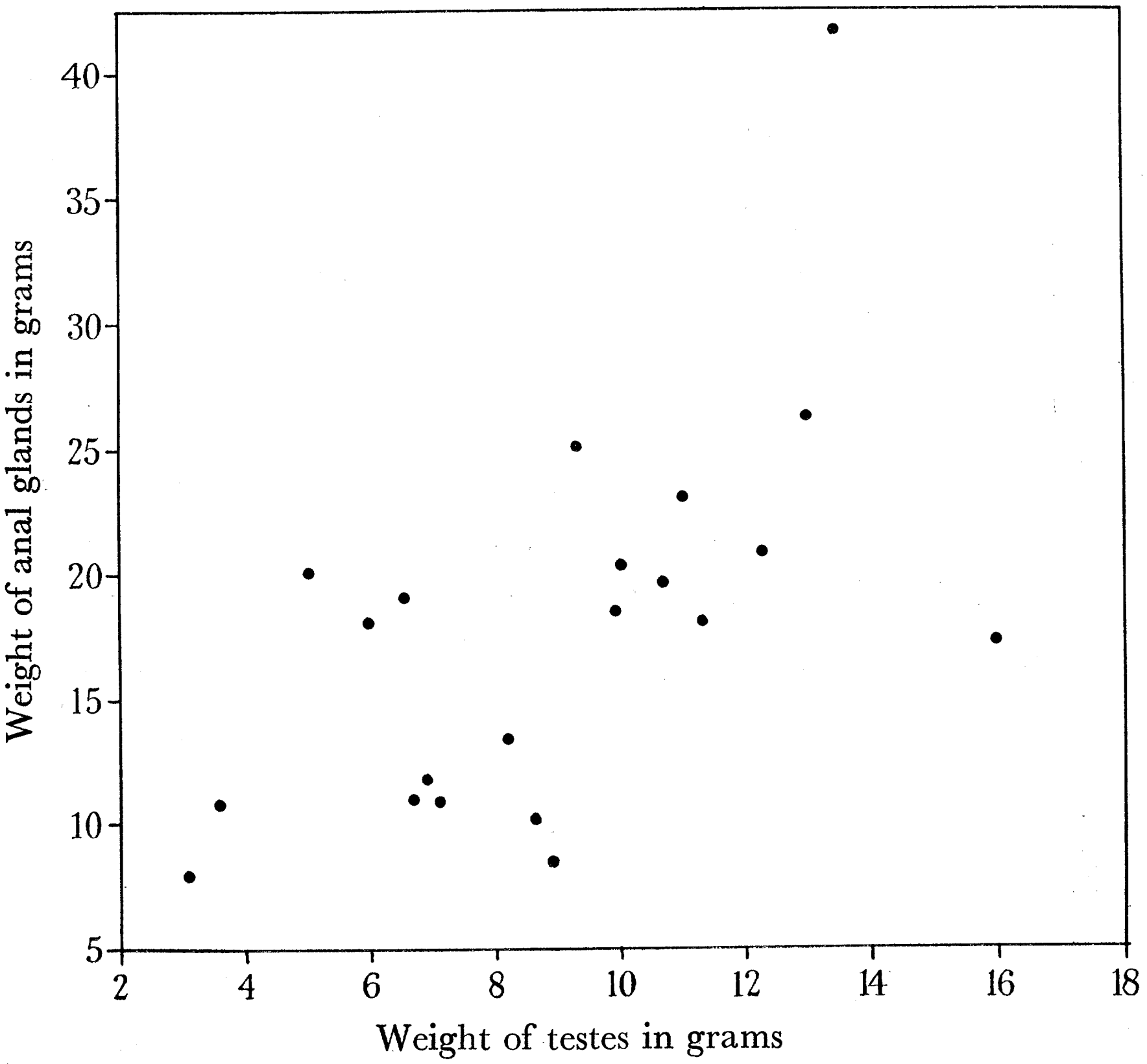

FIG. 22. Relation between weights of testes and of anal glands.

The weights of the anal glands, like those of Cowper's glands, show no more than a very rough correlation with those of the testes. Fig. 22 shows the values for the weights of these organs plotted against each other. Though there is a general indication of an increase in weight of the anal glands with increasing weight of the testes, the variation of the weights of the anal glands at any given testis weight are very wide. Further, no correlation can be found between the weight of the anal glands and the state of sexual activity after the attainment of puberty. The average weight of the anal glands in animals which are sexually inactive is 13·8 g., in those which are fully active it is 18·4 g., and in those which are intermediate it is 17·5 g.; but the variations within each class are very wide.

The prostate is very variable in its development. It is usually very small in size. In 64·7 % of the animals examined it was not distinguishable as a separate organ lying on the urethra, but was buried in the connective tissue surrounding it. In these animals it could only be revealed by cutting across the urethra so that it appeared in the cross-section. Fig. 23 shows its appearance in some of these specimens. Because of its small size, and its close investment by the urethral connective tissue, it was not found to be practicable to dissect out and weigh this organ separately. The scale of the drawings in fig. 23 gives an indication of its size.

In the remaining 35·3 % of animals the prostate was considerably larger, and was clearly recognizable as a distinct organ, often composed of two lateral lobes, lying on the dorsal surface of the urethra. Fig. 24 shows the appearance and size of the organ in some of these animals. The largest specimen was dissected out whole and weighed. It measured 8·0 mm. in length, and each lobe was 12·0 mm. wide and 12·0 mm. thick: the total weight was 1·3 g.

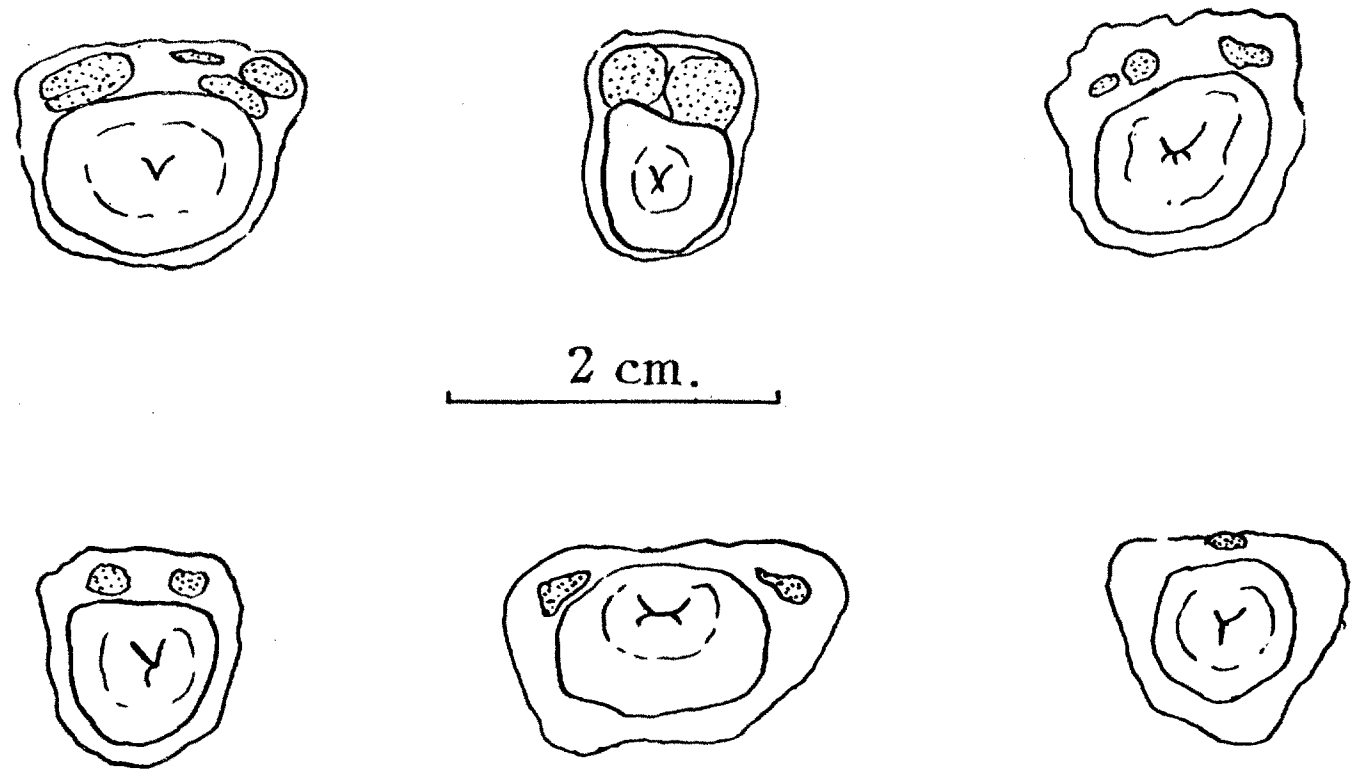

FIG. 23. The prostate and urethra in transverse section: from animals with small prostates. The glandular tissue is stippled.

In three animals the prostate could not be found, and appeared to be absent. One of these was a young animal with both basilar and fronto-parietal sutures open, and practically no tooth-wear. Nevertheless it had reached sexual maturity, and was in the intermediate stage of sexual activity, for the testes contained a moderate amount of spermatozoa and the epididymes were full. No trace of the prostate could be found in spite of careful dissection. The second specimen was a young adult, with the basilar suture closed, but the fronto-parietal suture still open, and the teeth worn about one-quarter. It was in full sexual activity, but here again no trace of the prostate could be found. The dissection was, however, much obscured by the urethral connective tissue, and it is just possible that a minute lobe was overlooked. The third specimen came from a physically mature unilateral cryptorchid animal, which was, nevertheless, in full sexual activity, the descended testis and epididymis being full of spermatozoa. No sign of the prostate could be found in the course of a careful dissection.

The occasional absence of the prostate is of interest because Watson (1877), as a result of his examination of a young adult specimen, reported that the prostate is absent in the spotted hyaena. In a later paper, however, he corrected this statement when he had dissected another, older animal (Watson 1878). He suggested that the prostate is not developed until sexual maturity is attained. The present series of specimens lends support to this view, the true position probably being that the prostate is an extremely small urethral gland until the animal approaches sexual maturity. It then usually, but not always, undergoes a degree of development which may be comparatively large or small.

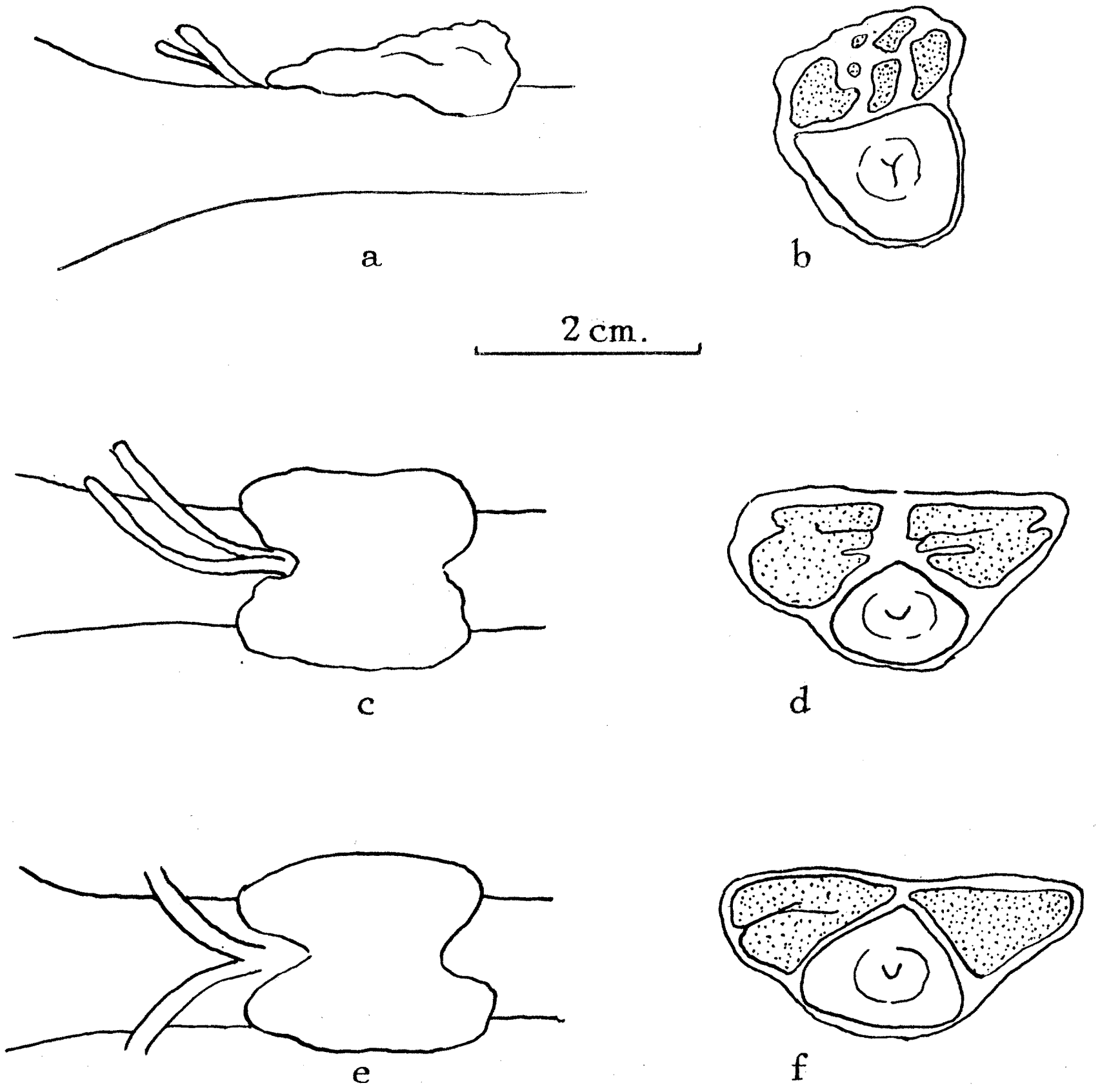

FIG. 24. The prostate in side view (*a*) and dorsal view (*c* and *e*). It lies on the dorsal side of the urethra near the junction of the vasa deferentia. *b*, *d*, *f* show transverse sections of the respective glands. The glandular tissue is stippled. From animals with large prostates.

The amount of development undergone by the prostate appears to be entirely uncorrelated with the age or size of the animal, or with the state of sexual activity. There is no indication that it increases or diminishes in size with any fluctuation in sexual function. Of the 35·3 % of animals with large, readily visible prostates, some were fully adult, with both cranial sutures closed, and others intermediate, with the basilar suture closed but the fronto-parietal suture open. In both categories some were in full sexual activity, and some intermediate. The 64·7 % of animals with small, inconspicuous prostates provide examples which fall into similar stages of sexual activity. The amount of growth undergone by the prostate thus appears to be quite haphazard, after the attainment of puberty, and the organ can be assumed to be of little importance in the physiology of the animal. It may, perhaps, be regarded as a vestigial, or disappearing, organ, though, as is shown below from an examination of its histology, it is not reduced to a state of functional atrophy.

Histology of the genitalia

The minute structure of the testis and epididymis does not differ materially from what may be termed the typical mammalian condition.

In the inactive state the tubules of the testis are about 200 μ in diameter, and have comparatively large lumina. Adjacent to the basement membrane of the tubules lies a layer of spermatogonia, about 10 μ in diameter. Further, within the tubules lies a layer, one or two cells deep, of spermatocytes, about 10 μ in diameter. The innermost layer, two to four cells deep, consists of a number of spermatids about 5 μ in diameter. The lumina of the tubules are quite clear, and no spermatozoa are present. The interstitial tissue is fairly abundant, and consists of a number of interstitial cells packed in the spaces between adjacent tubules (fig. 38, Plate 1).

In the active state the tubules of the testis are about 200–250 μ in diameter, and the lumina are completely filled with spermatozoa. The spermatogonia, forming a layer next to the basement membrane, are about 10 μ in diameter. The spermatocytes, forming a layer one or two cells deep within the layer of spermatogonia, are about 10 μ in diameter. The spermatids, about 5 μ in diameter, form a layer three to six cells deep, lining the tubules. The lumen of the tubules is filled by a mass of spermatozoa, lying with their heads amongst the cells of the spermatid layer, and their tails occupying the lumina of the tubules. The interstitial tissue is small in amount, and consists only of a few interstitial cells, filling the small space formed at the point where the boundaries of three adjacent tubules meet (fig. 39, Plate 1).

In the intermediate stage the tubules are of about the same size as those in full activity, and are lined by similar layers of cells. The layer of spermatids, however, is not so deep, and the lumen of most of the tubules is clear. Spermatozoa in various stages of development lie amongst the spermatid and spermatocyte layers, with their heads connected to large Sertoli cells, lying amongst the spermatogonia adjacent to the basement membrane. Their tails project a short way into the lumina of the tubules. The interstitial tissue is relatively large in amount, and fills the spaces between the tubules, which in this stage of activity are rather loosely packed (fig. 40, Plate 1).

In the inactive state the tubules of the epididymis are 200–250 μ in diameter. Their lumina are entirely free from spermatozoa, and are usually quite empty, only occasionally containing a few leucocytes. The tubules are lined with a single layer of columnar cells, about 40 μ in length, with oval nuclei. At the base of the columnar cells is a layer of smaller polyhedral cells, with round nuclei. The ends of the columnar cells facing the lumina are ciliated (fig. 41, Plate 2).

In the active state the tubules are about 250–300 μ in diameter, and are lined by cells similar to those found in the inactive state. The columnar cells are, however, about 50 μ

in length, and their inner ends appear to be considerably more heavily ciliated than in the inactive state. The lumina of the tubules are filled with a mass of spermatozoa (fig. 42, Plate 2).

The Cowper's glands are similar in structure to those of other mammals, but are, comparatively, rather large in size. They are tubo-racemose glands, the lobules of which are surrounded by a membrane of connective tissue. The acini are lined by a single layer of large columnar secreting cells, whose nuclei lie near their bases. Different states of activity are recognizable in the gland, but it has not been found possible to correlate these states with the stages of sexual activity shown by the testes. In the prepubertal animal the gland appears to be less active than in the majority of those showing full sexual activity. But in some of the animals with fully active testes the Cowper's glands appear to be in a state of activity little, if any, more pronounced than in the prepubertal animal. These different states of activity in the Cowper's glands, of animals in full sexual activity, may possibly be explained by the statement of Stilling (1885), that the secretory epithelium of the glands undergoes histological changes which depend upon the occurrence of coitus.

Four states of activity of the gland are recognizable in the present series. In the prepubertal animal the acini are small, about 50μ in diameter, so that the secretory cells fill most of the lumina, which are in consequence rather inconspicuous in a section of the gland. The nuclei lie close to the bases of the cells, of which the bodies are filled with a large number of minute granules. The acini are separated from each other by narrow strands of connective tissue about 10μ thick (fig. 43, Plate 2).

In some of the sexually mature animals a somewhat similar state of activity is recognizable. The acini are small so that the cells fill most of the lumina. The cells are filled with a large quantity of minute granules. But, as compared with the first state of activity described, the relative amounts of glandular and connective tissue are greatly different. The acini are here separated by broad bands of connective tissue, 20–50μ wide. The connective tissue thus appears to form a background in which the acini are embedded, rather than thin strands separating them (fig. 44, Plate 2). Sections of the gland in a further state of activity, found in some sexually mature animals, show the acini so filled with large cells that the lumina are frequently completely obliterated. The cells are packed with granules, which are much coarser than those present in the states previously described. The acini are packed closely together, and separated from each other only by narrow strands of connective tissue (fig. 45, Plate 3).

Finally, in the state most commonly found in the mature animal, the acini of the gland have conspicuous lumina. They are lined by cubical cells with clear contents, and the nuclei lie close to their bases. The granules, so conspicuous in the states already described, are here entirely absent. The acini are separated from each other by narrow strands of connective tissue, only 5–10μ wide (fig. 46, Plate 3).

The histological state of the prostate varies considerably in the present series of animals. As pointed out above, no correlation between the size of the prostate and the state of sexual activity can be made out, but there is a definite histological difference between the large and the small prostates. The extremes of activity are here described and figured, but it must be emphasized that there is no sharp demarcation between the two, and that many intermediate phases connect them.

The smallest glands, in the least active state, consist of a stroma of connective tissue and plain muscle fibres, through which run the widely scattered tubular alveoli. The alveoli are small, from 20 to 30μ in diameter, and are lined with a layer of epithelium consisting of closely packed cubical and polyhedral cells, one cell thick. The cells are small so that their nuclei fill the greater part of them; their protoplasm is free of granules. The lumina of the alveoli are very small, and, in many specimens, almost completely absent (fig. 47, Plate 3).

In the larger glands the alveoli are very much more numerous, and in consequence the connective and muscular tissue is very much reduced. The alveoli are from 30 to 60μ in diameter, and have conspicuous lumina (fig. 48, Plate 3). They are lined by large columnar cells, whose nuclei lie near the basement membrane. The cells project irregularly into the lumen so that the epithelium is very much thicker in some places than in others. The cells are closely packed with large granules, which are rather more concentrated towards the free ends of them. Small blood vessels are conspicuous in the connective tissue between the alveoli (fig. 49, Plate 4). In many specimens numbers of the alveoli are filled with hard concretions, which fill most of the lumen. The concretions occur, not only in the prostates of old individuals, but also in those of physically immature ones which have reached sexual maturity at an early age (fig. 50, Plate 4).

Some specimens are very highly vascularized, and these are not necessarily those showing a high state of activity of the gland. Fig. 51, Plate 4, shows an example in which, though the alveoli are small, the stroma of connective tissue is filled with a large number of small blood vessels.

The anal glands consist of a number of roughly spherical lobes surrounding a central cavity. Each lobe is about 5 mm. in diameter, and each opens into the central cavity by its own duct. The central cavity opens into the anal pouch by a single separate duct. A number of isolated lobes, lying dorsal to the rectum and between the two large compound anal glands, open directly into the dorsal part of the anal pouch by their own individual ducts.

The anal glands are, essentially, modified and highly developed sebaceous glands. Each lobe is a compound racemose gland, consisting of a number of lobules separated from each other by connective and muscular tissue. The lobules contain a large number of acini, $30–40\mu$ in diameter, which open into the ultimate branches of the duct. The acini have no lumina, and consist of a solid mass of cells. At their proximal ends the acini, in cross-section, are seen to contain from two to five polyhedral cells, with conspicuous circular nuclei. The walls of the acini contain a single layer of flattened connective tissue cells. The acini are continuous with the subdivisions of the ducts.

At their distal ends, near their junction with the ducts, their contents consist of cells which have been pushed out of the proximal part. These are considerably swollen, and their contents are clearer, but show a darker staining reticulum. In consequence of the swelling of the cells the nuclei occupy a proportionally smaller part of the cell volume. The spaces between the cells are filled with dark-staining matter (fig. 52, Plate 4).

As the acini pass into the ducts their walls become thicker. The smallest subdivisions of the ducts are lined with epithelium similar to that of the acini, but two or three layers of cells in thickness. The division between duct and acinus is not sharply marked: the one passes imperceptibly into the other. For convenience the number of cell layers in the epithelium is here taken arbitrarily as the distinction. The acini thus have one layer of cells, and the ducts two or more layers, in their epithelium.

As the cells pass down the ducts they increase in size. Thereafter the nuclei begin to shrivel and degenerate, and then the cell outlines become irregular. Finally the nuclei disappear entirely, and the ducts are filled with a mass of distorted cells, without nuclei, whose contents appear quite clear.

As the duct gets wider its walls become thicker. The flattened epithelium passes into a layer of polyhedral cells, and this in turn into two further layers. These are, an external one of polyhedral cells, several cells thick, and an internal one of flattened cells, many cells thick in the lower parts of the ducts. In the distal parts of the ducts the flattened cells become cornified, and are desquamated into the lumen, where they are added to the mass of degenerated cells which form the "secretion". The cavity of the anal glands is filled by a pasty mass, which, on microscopical examination, is revealed as consisting entirely of the degenerated cells described above, held together by a greasy or waxy substratum.

The absence of a seasonal sex cycle

The present series of specimens gives no indication of the occurrence of any seasonal sexual cycle. Animals in different stages of sexual activity occur together at the same time, and in the same place. Sexual maturity is reached before physical maturity. All physically mature animals show some degree of sexual activity, and, in the majority of instances, are fully active. It would appear, then, that the male spotted hyaena, at least in the district of Tanganyika Territory where the present series was collected, is capable of breeding at any time. Breeding would thus be limited only by the occurrence of oestrus in the female: as is shown below, oestrus in that sex is not a seasonal phenomenon, but may occur at any time. The male is thus not only capable of breeding at all times, but in fact actually does so.

(2) The female

Physical and sexual maturity

The criteria of amount of suture-closure, and of tooth-wear, used in considering the onset of maturity in the male, are now applied to the female. Table VII shows the correlation between suture-closure and tooth-wear in this sex. The sutures do not start closing until the teeth are one-quarter worn, and closure, of both the fronto-parietal and basilar sutures, is not commonly complete until the teeth are nearly half worn. On comparing these conclusions with the data shown in Table VIII, it is seen that the head-and-body lengths corresponding with these stages are 115–120 cm. and 120–125 cm.

Table VII. Females. Relation between tooth-wear and suture-closure

Both closed	—	—	—	3	5	6	3	3
Basilar suture closed, fronto-parietal open	—	—	10	1	—	—	—	—
Both open	4	1	2	—	—	—	—	—
Tooth-wear	0	1/4−	1/4	1/4+	1/2−	1/2	1/2+	3/4

Table VIII. Females. Relation between tooth-wear and length of head and body

Length of head and body in cm.	0	1/4−	1/4	1/4+	1/2−	1/2	1/2+	3/4
130–135			1			1		1
125–130						3		
120–125		1	5	1	3	2	2	2
115–120	1		3	2	2		1	
110–115			1					
105–110		1	1					
100–105								
95–100	2							
90–95	1							

Tooth-wear

Female hyaenas are much more easily divided into groups according to the state of sexual activity than are the males. The groups into which they naturally fall are prepubertal, pregnant, lactating, and parous but not pregnant nor lactating. The prepubertal animals can be immediately separated from all others, except those early in their first pregnancy, by the size of the nipples. Further, the prepubertal animals can be subdivided into two well-marked groups. These are group A, in which there is no sign of approaching sexual maturity, and group B, adolescents nearing the onset of puberty.

Table IX shows the numbers of specimens in each group, per cent of the total number of females, falling within the three categories of skull suture-closure. It shows that puberty and physical maturity much more nearly coincide in this sex than in the male.

TABLE IX. FEMALES. SUTURE-CLOSURE IN GROUPS ACCORDING TO SEXUAL ACTIVITY

Group	Both open	Basilar suture closed, fronto-parietal open	Both closed
1. Prepubertal, A	15·8	5·3	—
2. Prepubertal, B	2·6	15·8	—
3. Parous	—	—	34·2
4. Lactating	—	7·9	7·9
5. Pregnant	—	—	10·5
Groups 3, 4 and 5 together	—	7·9	52·6

Table X shows the head-and-body lengths, and the numbers of specimens, within the five groups. It shows that all the animals under 115 cm. in head-and-body length are completely immature, that all those over 125 cm. are mature, and that puberty occurs at a head-and-body length of about 120 cm. These data are further analysed in Table XI, in which the average head-and-body length, and the range of variation, within each group are shown. On comparing these values with those given above for the male, it is seen that, in the female, puberty and physical maturity both occur at a head-and-body length about 5·0 cm. greater than in that sex. This is due to the fact that the adult female is a larger animal than the male, as is shown by fig. 25, in which the size frequencies for each sex are plotted separately. If the sexes grow at the same rate the female must be older than the male on reaching puberty, whereas, if puberty is reached at the same age in both sexes, the female must grow more rapidly. If the amount of tooth-wear can be taken as roughly indicating comparative ages, a proposition which appears to be reasonable, the data in Table XII show that the first of these two alternatives is the correct one. In this table the numbers of prepubertal and mature animals, per cent of the total of each sex, are arranged according to the amount of tooth-wear (= age), and the earlier onset of puberty in the male is clearly seen.

TABLE X. FEMALES. HEAD-AND-BODY LENGTHS ACCORDING TO SEXUAL ACTIVITY

Length of head and body in cm.	Group A	Group B	Parous	Lactating	Pregnant
	Prepubertal				
130–135				1	1
125–130			2	1	
120–125		6	8	2	2
115–120	1	2	3	2	1
110–115	1				
105–110	2				
100–105					
95–100	2				
90–95	1				

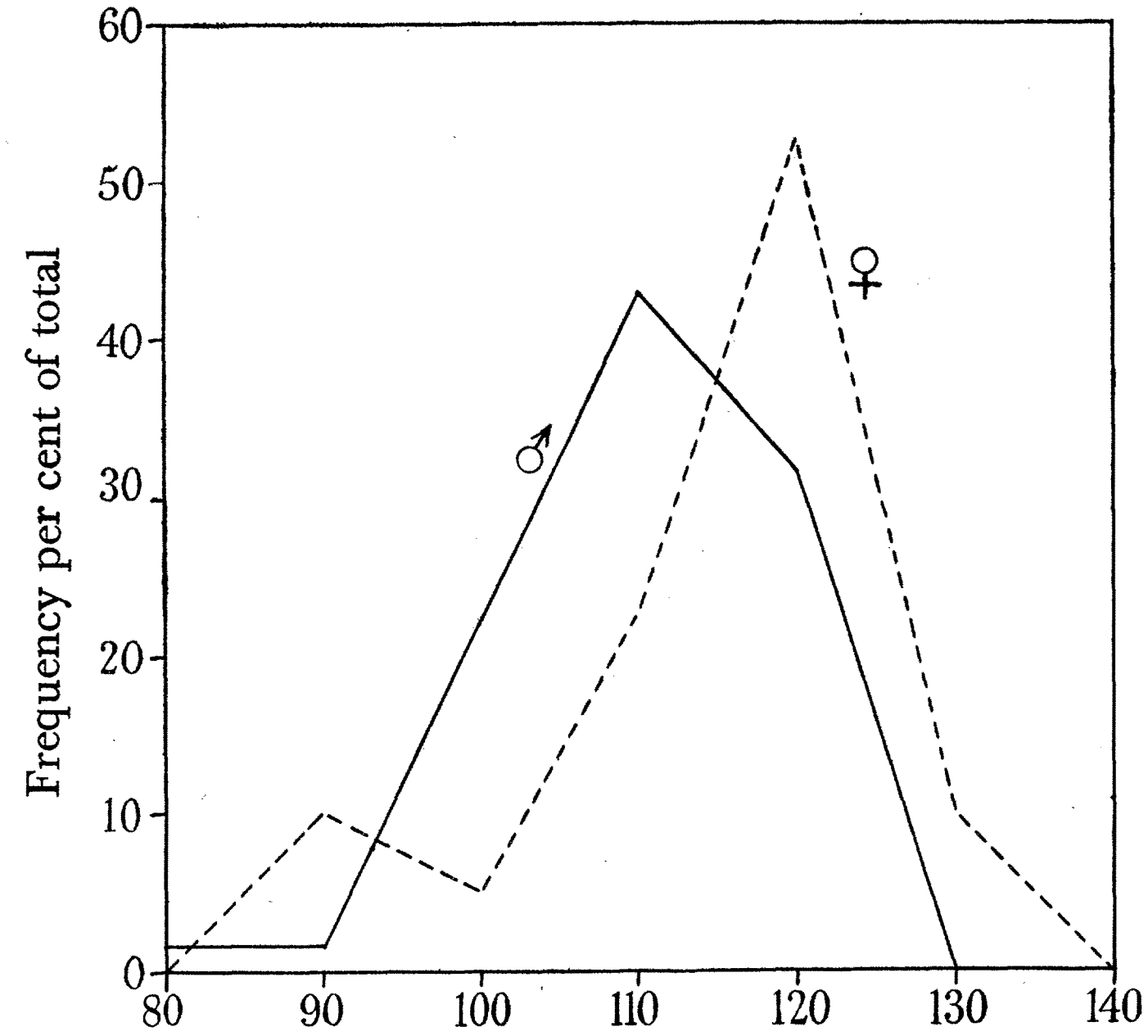

FIG. 25. Frequency curves of head-and-body length for males and females.

Table XI. Females. Head-and-body lengths of groups according to sexual activity

Group	Head-and-body length in cm. Minimum	Maximum	Average
1. Prepubertal, A	92·8	117·0	104·4
2. Prepubertal, B	115·6	123·3	121·5
3. Parous	118·3	127·0	122·4
4. Lactating	119·5	133·3	125·1
5. Pregnant	118·3	132·0	124·2
Groups 3, 4 and 5 together	118·3	133·3	123·9

Table XII. Males and females grouped according to tooth-wear (= age) and sexual maturity. Numbers are the values percentage of the totals for each sex

Tooth-wear	Males: Prepubertal	Males: Sexually mature	Females: Prepubertal	Females: Sexually mature
0	8·7	1·7	8·1	—
1/4 –	1·7	7·0	5·4	—
1/4	5·3	44·0	24·3	8·1
1/4 +	—	—	—	8·1
1/2 –	—	1·7	—	13·5
1/2	—	23·0	—	16·7
1/2 +	—	—	—	8·1
3/4	—	7·0	—	8·1
Percentage of totals for each sex below 1/4 +	15·8	52·7	37·8	8·1

Size variation in the genitalia

Three factors are of importance in considering the ovaries: the weight, the number and size of the follicles, and the number and size of the corpora lutea. The ovary weight recorded for each specimen is that of the two ovaries taken together: the ovaries of the two sides are often markedly unequal in size. For macroscopical examination the ovaries were divided into a number of thin slices some 2–3 mm. thick. The cuts separating the slices were stopped short of complete severance, so that the slices remained joined at one edge. The slices could then be separated like the pages of a book, and the whole substance of the ovary examined; the parts required for microscopic examination were afterwards removed.

Examination of the ovaries in this way revealed a high degree of luteinization in all the females which had reached sexual maturity: the main bulk of the ovary was made up of comparatively large corpora lutea. Follicular tissue was small in amount, and large follicles very few in number (figs. 53, 54, Plate 5). In parous animals, then, the greater part of the weight of the ovaries represents, in most cases, the weight of the corpora lutea present. In prepubertal animals the weight of the ovaries represents the weight of the ovarian stroma and follicles alone. There are two subdivisions of prepubertal animals, as mentioned above—group A, which shows no sign of approaching sexual maturity, and group B, adolescents nearing the onset of puberty. The weight of the ovaries of those in group A is less than 1·0 g.; that of those in group B is from 1·0 to nearly 2·0 g. That these groups are real, and not merely arbitrary, is shown by an inspection of Table XIII. This table shows the ovary weight of each specimen in groups A and B, together with the number of follicles visible to the naked eye. The difference between the follicular content of the ovaries of the two groups is well marked. Differences in the physical development between the two groups have already been pointed out: the difference in sexual development, as shown by the ovaries, will be found to be confirmed when considering the other organs of the genitalia.

TABLE XIII. OVARY WEIGHTS AND NUMBERS OF VISIBLE FOLLICLES; IN PREPUBERTAL ANIMALS

Prepubertal group A		Prepubertal group B	
Wt. of ovaries in g.	Follicles visible to the naked eye	Wt. of ovaries in g.	Follicles visible to the naked eye
0·50	None	1·30	Many, up to 2·5 mm. in mean diameter
0·70	None	1·30	Many, up to 2–3 mm. in mean diameter
0·50	A few, very minute	1·05	Many, up to 3 mm. in mean diameter
0·55	A few, very minute	1·60	Many, up to 3 mm. in mean diameter
0·50	One, 2 mm. in mean diameter	1·80	Many, up to 3–4 mm. in mean diameter
0·60	A few, up to 1·5 mm. in mean diameter	1·25	Many, up to 4 mm. in mean diameter
0·65	A few, up to 3 mm. in mean diameter: some smaller	1·00	Two large, 6 mm. in mean diameter: many smaller
0·90	Several, up to 3 mm. in mean diameter		

TABLE XIV. NUMBER OF SPECIMENS, AND OVARY WEIGHTS, IN GROUPS ACCORDING TO SEXUAL ACTIVITY

Pregnant										1	3	
Lactating					2	2	1			1		
Parous					4	2	2	4			1	
Prepubertal group B			5	2								
Prepubertal group A		8										

0 1 2 3 4 5 6

Weight of ovaries in g.

Turning now to the ovary weights of the animals in each of the five groups, Table XIV shows that the ovary weight of each group falls within well-defined limits. Disregarding for the moment the two isolated cases of very high ovary weight in the groups parous, and lactating, the ovary weight of group prepubertal A shows the weight of ovarian stroma and minute follicles: that of prepubertal B shows the increase due to the growth of the follicles: those of groups parous and lactating show a further increase due mostly to the development of corpora lutea, and that of pregnant animals the great increase due to the presence of the functional corpora lutea of pregnancy. The isolated case of high value in the parous group is found, on further inspection of the ovary, to be due, not to the presence of an unusually large amount of luteal tissue, but to the presence of large ripe follicles on the point of rupture. This animal had just come into oestrus: one ovary contained a follicle 10 mm. in diameter and several smaller ones up to 5 mm. in diameter; and the other contained one follicle 6·0 mm. in diameter and several smaller ones. The single case of high value in the lactating group is due solely to the large amount of luteal tissue. It refers to an animal which had quite recently given birth, in which the large corpora lutea of pregnancy had not yet had time to regress. These two ovaries throw some light on the events of the sexual cycle, and will be referred to again below. The mean value, and range of variation, of the ovary weight in each group, excluding these two extreme cases, are shown in Table XV.

TABLE XV. FEMALES. VARIATION IN WEIGHT OF THE VARIOUS ORGANS OF THE GENITALIA. WEIGHTS IN GRAMS

	Ovaries			Fallopian tubes			Uterus			Vagina		
Group	Min.	Max.	Mean	Min.	Max.	Mean	Min.	Max.	Mean	Min.	Max.	Mean
Prepubertal, A	0·50	0·90	0·61	0·35	0·90	0·52	1·00	4·80	2·31	4·60	9·80	6·99
Prepubertal, B	1·00	1·80	1·32	0·70	1·95	1·39	5·55	18·75	10·14	11·30	28·50	18·40
Parous	1·95	3·65*	2·95*	0·70	2·90	1·55	9·20	27·80*	17·85*	19·55	42·80	17·85
Lactating	2·30	3·30*	2·69*	0·95	2·20	1·47	8·85	16·60	11·87	18·15	31·10	23·99
Pregnant	4·80	5·15	5·02	1·25	1·40	1·34	—	—	—	26·70	39·10	31·90

	Clitoris			Bartholin's glands			Anal glands		
Group	Min.	Max.	Mean	Min.	Max.	Mean	Min.	Max.	Mean
Prepubertal, A	39·50	65·90	48·15	1·30	3·60	2·25	5·00	15·60	10·20
Prepubertal, B	48·50	80·00	68·60	0·55	0·94	0·70	9·20	28·40	20·80
Parous	58·50	118·00	80·30	1·20	4·70	3·24	23·60	46·00	30·70
Lactating	50·00	86·50	64·40	1·10	2·90	2·20	12·90	45·25	28·70
Pregnant	65·00	86·00	74·00	2·80	4·20	3·40	21·10	22·00	21·55

* Excluding the single exceptionally high value as mentioned in the text.

The high degree of luteinization found in the ovaries of all but prepubertal animals is usually due, not only to the size, but also to the number, of the corpora lutea. This is true even of the pregnant group, in which, however, the main bulk is due to the younger functional corpora lutea. Inspection of macroscopic sections of the ovaries shows at once that the corpora lutea, if more than three or four in number, and sometimes when fewer, are obviously of different ages. The youngest corpora lutea are distinguished by their large size and light colour, which is some shade of yellow. Older and smaller corpora lutea are dull brown in colour, and a further group of still older ones is very dark brown, and small in size, frequently showing only as distorted remnants. It is, unfortunately, impossible to separate the corpora lutea into groups more closely defined than these three. Evidently the older corpora lutea of different ages are indistinguishable from each other by colour and size. Microscopic examination, as is shown below, is of no avail in attempting any closer subdivision. It appears probable that the remains of old corpora lutea are never completely resorbed, and that they persist as dark-coloured remnants in the ovary throughout the life of the animal. They are thus persistent corpora albicantia, though that name is anything but descriptive of them.

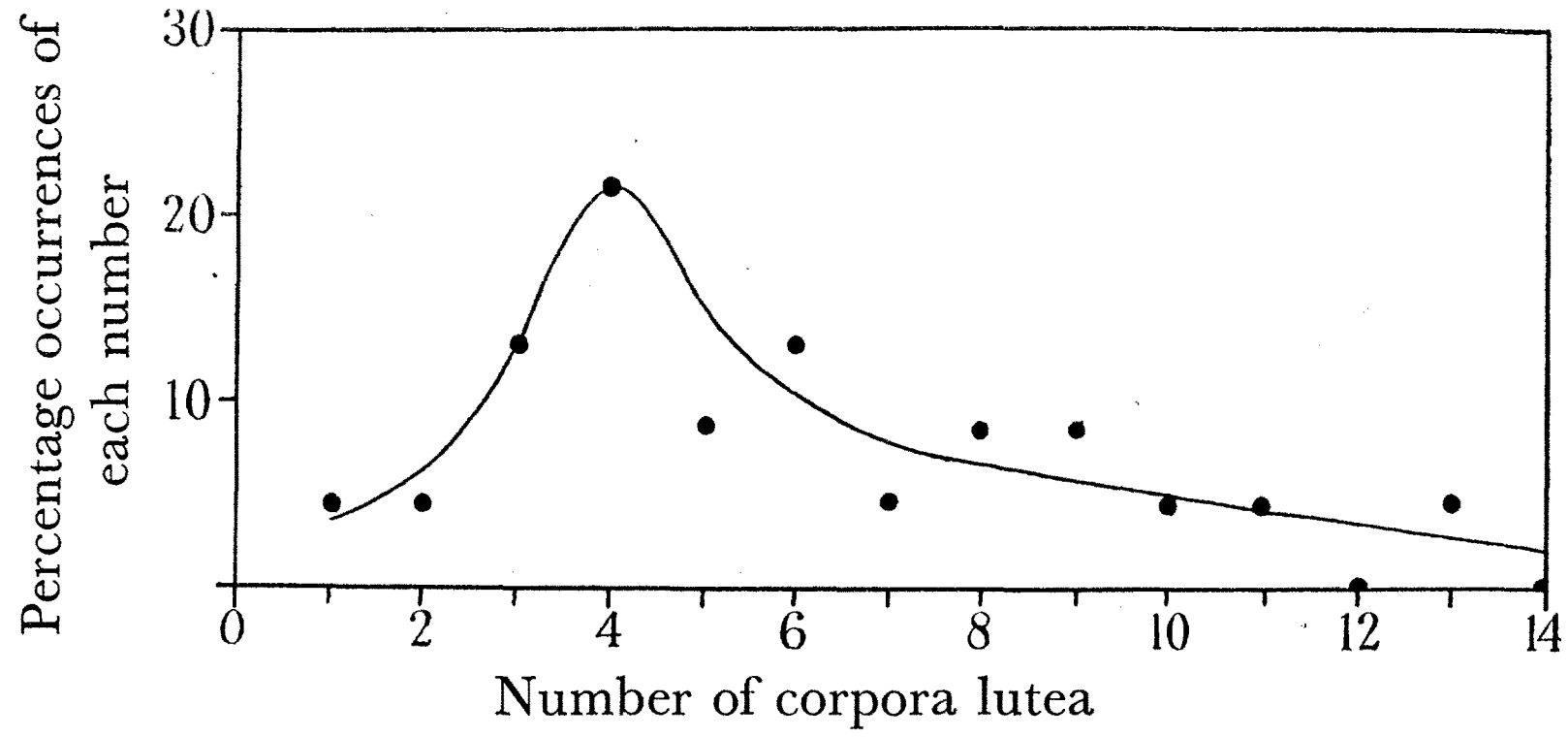

FIG. 26. Frequency curve for different corpus luteum numbers.

The proposition that traces of the old corpora lutea persist indefinitely is supported by the curve shown in fig. 26. In this figure the percentage of occurrences is plotted against the total number of corpora lutea in the ovaries. The line joining the points is irregular, but the curve representing the mean value is a skew frequency distribution curve. This is precisely the type of curve that would be expected if the number of corpora lutea in the ovaries depended upon the age of the animal. If the corpora lutea were not persistent this curve would be expected to be more nearly symmetrical about a peak at that number representing the most frequent number of ovulations at each oestrus. These conclusions, that the corpora lutea persist throughout the animal's life and that their number depends upon its age, are confirmed by an inspection of Table XVI. Here the occurrences of the different numbers of corpora lutea are correlated with the degree of tooth-wear, which, as pointed out above, is a prima facie indication of age. The table shows that the ovaries of the oldest animals contain the largest numbers of corpora lutea. The question of the number and ages of the corpora lutea will be referred to again in the section below dealing with the oestrous cycle.

The weight of the fallopian tubes in each group is plotted separately against that of the ovaries in fig. 27. In prepubertal group A the weight is small, but in the others it lies most commonly between 1·0 and 2·0 g. After the attainment of puberty it lies between these limits and shows no particular correlation with the state of sexual activity, except in one case. This is the high value in the parous class: it is the greatest weight of the series, and shows the weight of the tubes in an animal at oestrus. The highest weight of the fallopian tubes in the lactating group is not markedly in excess of the others, nor would it be expected to show a high value, because the weight in pregnant animals is no more than that in prepubertal group B. Table XV shows the mean weight, and the range of variation, of the fallopian tubes in each of the five groups.

Table XVI. Numbers of corpora lutea in groups according to tooth-wear (= age)

Number of corpora lutea	0	1/4−	1/4	1/4+	1/2−	1/2	1/2+	3/4
13								1
12								
11							1	
10								1
9					1		1	
8						1		1
7						1		
6					1		2	
5				1		1		
4				1	2	2		
3			2	1				
2			1					
1			1					
0	5		9	1				

Tooth-wear

The weight of the uterus in the different groups is plotted against the ovary weight in fig. 28. This shows that the weight usually lies between 10 and 25 g. in prepubertal animals. The weights in prepubertal group A are small, but those in group B show a progressive increase to values equal to those of sexually mature animals. The weights of the uterus in the lactating group show the size of the involuted organ, which is comparatively small even in the animal in which parturition has recently occurred.

The weights in the parous group show a variation from complete anoestrus, through higher values as oestrus approaches, to the extreme shown by the animal in oestrus. The mean weight of the uterus, and the range of variation, are shown for the different groups in Table XV.

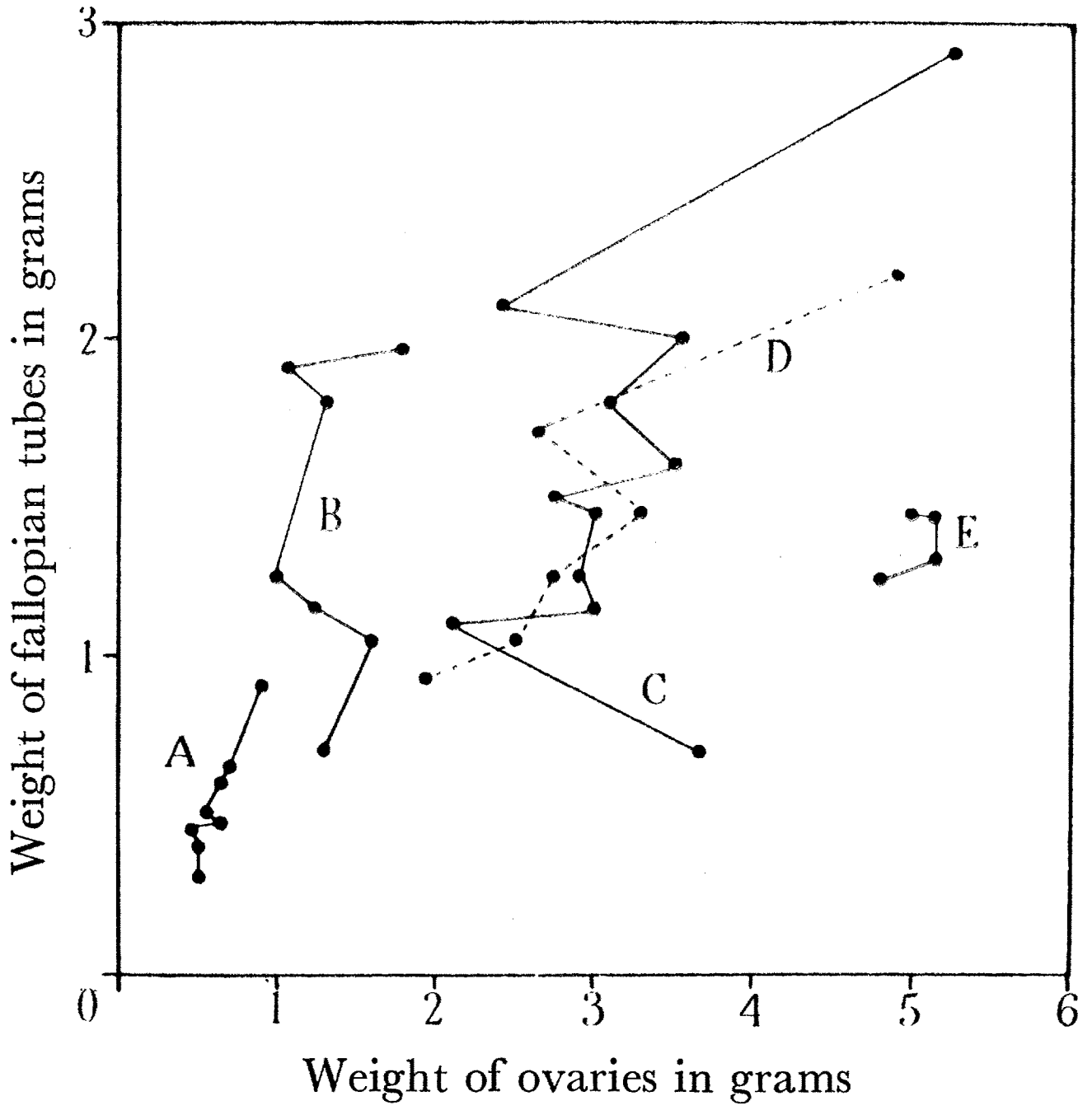

FIG. 27. Relation between weights of ovaries and of fallopian tubes.

In figs. 27–32 inclusive: A, prepubertal group A; B, prepubertal group B; C, parous; D, lactating; E, pregnant.

The weight of the vagina in the five groups is plotted against ovary weight in fig. 29. Prepubertal group A show a very small degree of development of the organ, but prepubertal group B shows an increase as maturity is approached. The weight in the lactating group lies between 18 and 32 g. It is of interest to note that the weight in the most recently parturient animal of the group lies well within the upper limit, showing that the involution of the vagina after birth is rapid. In the pregnant group the weight is also within these limits for two specimens about half-way through their pregnancies, but it is considerably greater in one specimen containing foetuses ready for birth. The parous group shows a much greater range of variation. In the majority of the specimens the weight is between 20 and 30 g. Others show an increase in weight the nearer they approach to oestrus, with a maximum of 42·8 g. in an animal at oestrus. Table XV shows the mean, and range of variation, of the weight of the vagina.

The weight of the clitoris would be expected to show some degree of correlation with that of the vagina, but it is not found to do so. Fig. 30 shows the weight of the clitoris plotted, separately for each group, against that of the ovary. Apart from the low values in some of the prepubertal A group, the weight of this organ shows a wide variation,

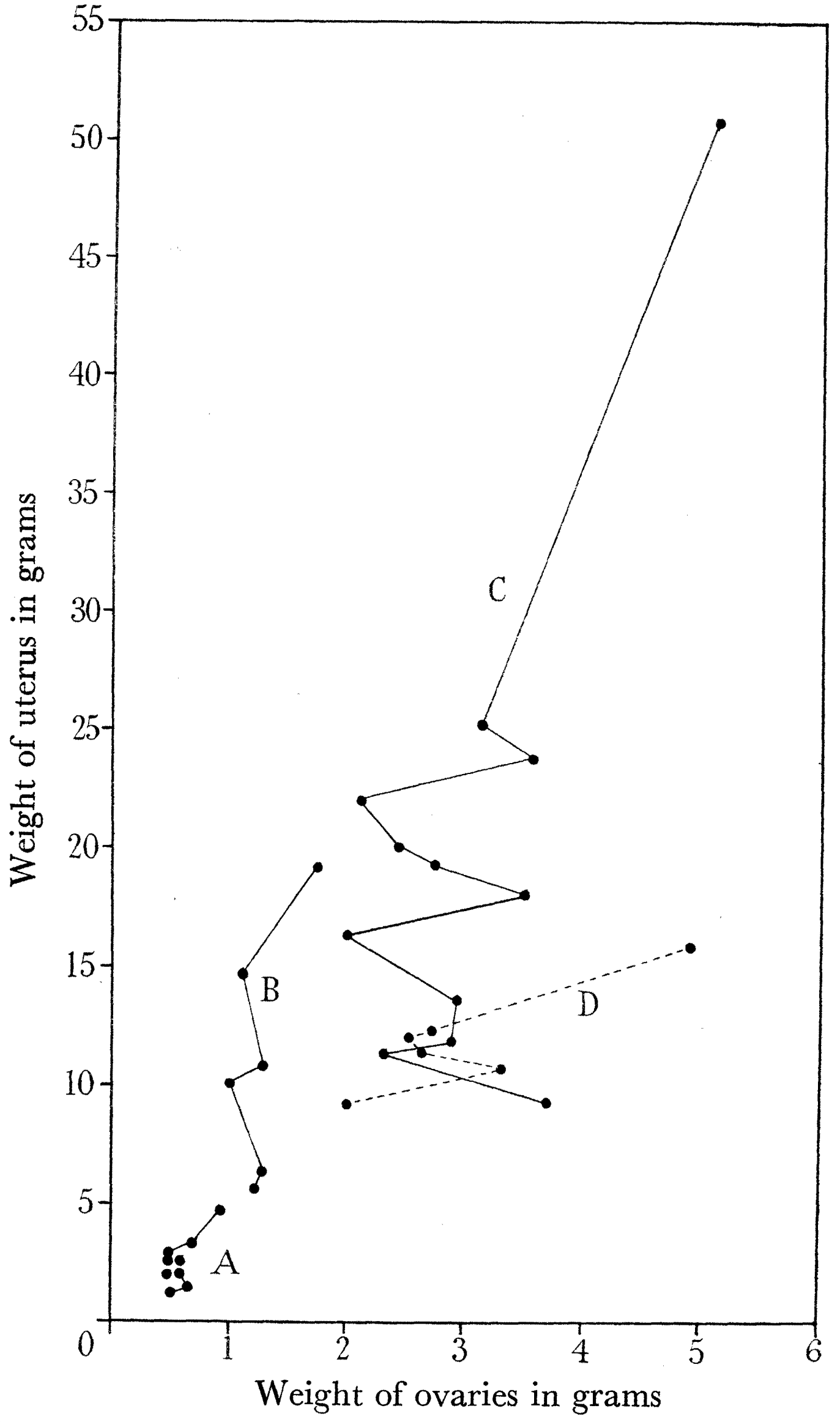

FIG. 28. Relation between weights of ovaries and of uterus.

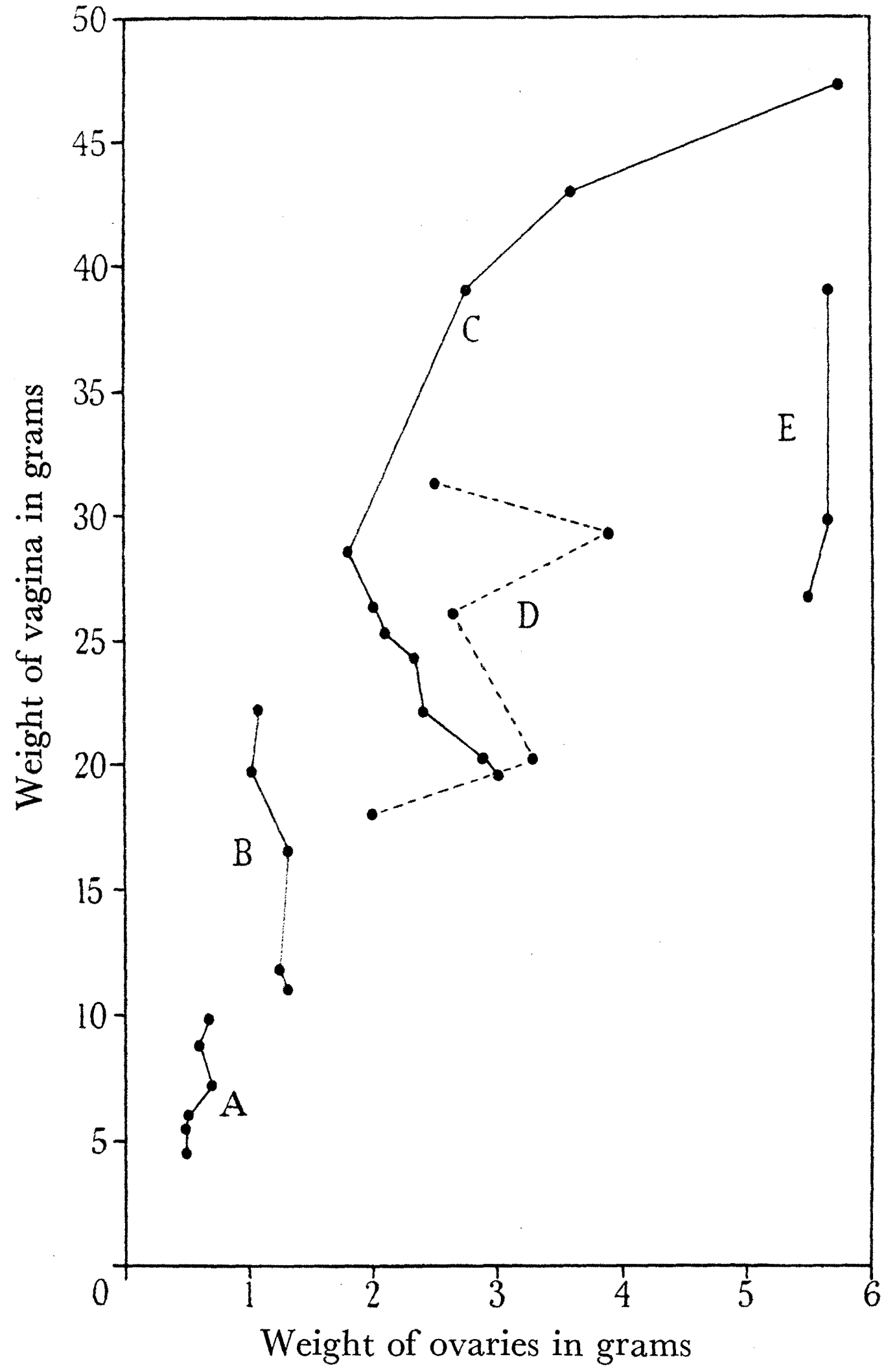

FIG. 29. Relation between weights of ovaries and of vagina.

and no correlation with the different states of sexual activity. Its apparent increase in size in the parous animal is due therefore to the increase in slackness of the preputial tissues, and not to any great addition of weight to its structure. The mean weight and range of variation in each group is shown in Table XV.

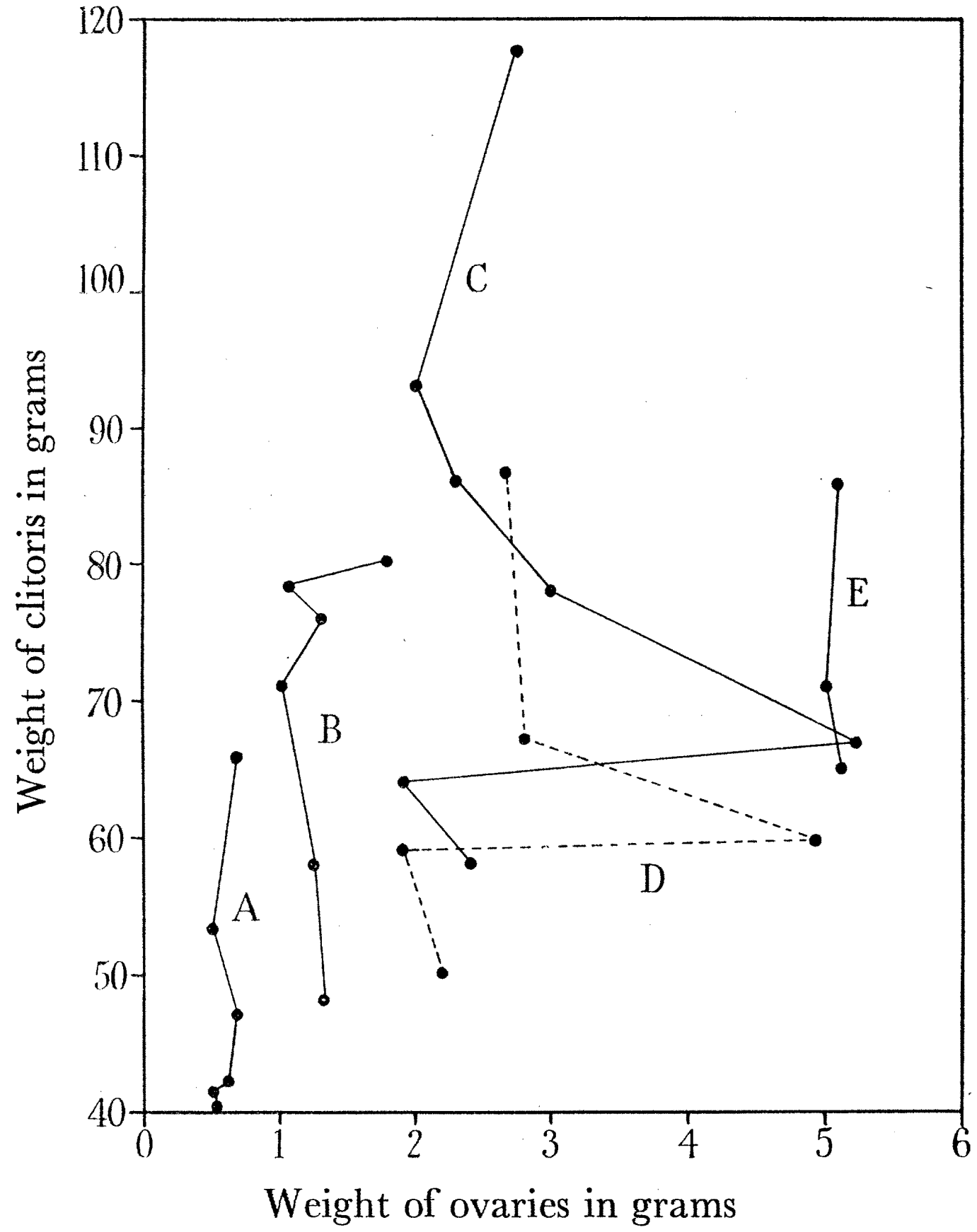

FIG. 30. Relation between weights of ovaries and of clitoris.

The weight of Bartholin's glands varies between 1·0 and 5·0 g. in all groups, except prepubertal group A. In the latter it is less than 1·0 g., but fig. 31, in which the weight of Bartholin's glands is plotted against ovary weight, shows that the glands reach their full size shortly before puberty. Thereafter they show considerable individual variation in size, with little correlation with the different states of sexual activity. There may be some indication that the weight in the lactating group is rather lower than the mean value, but the points are too few to give definite conclusions. As with the weights of the other organs of the genitalia, the parous group, which contains animals in more widely varying degrees of sexual activity than the others, shows the greatest variation. The mean values, and the range of variation, of the weight of Bartholin's glands in the five groups are shown in Table XV.

The weight of the anal glands is plotted separately against that of the ovaries for the five groups in fig. 32. The mean values and range of variation are shown in Table XV.

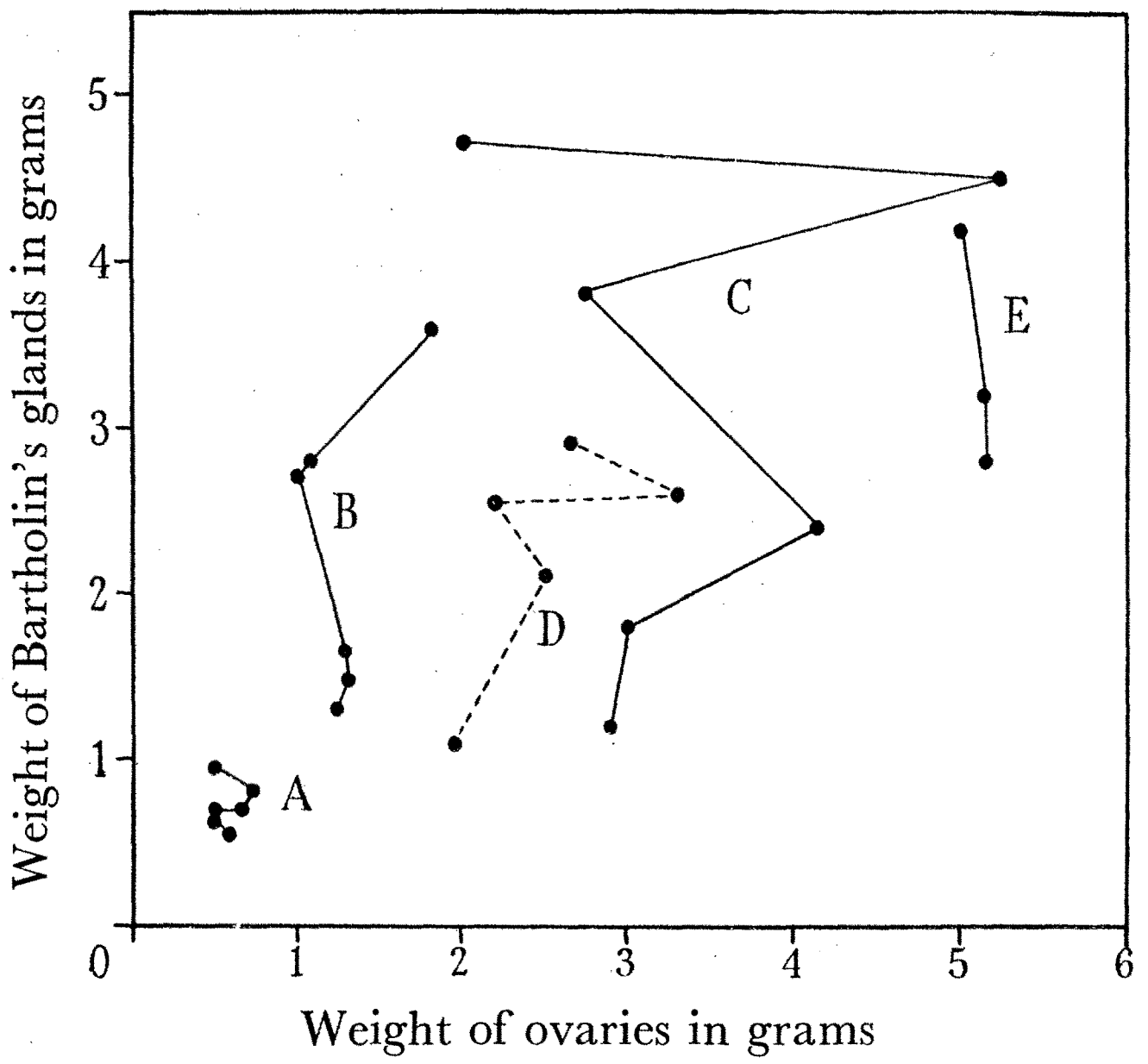

FIG. 31. Relation between weights of ovaries and of Bartholin's glands.

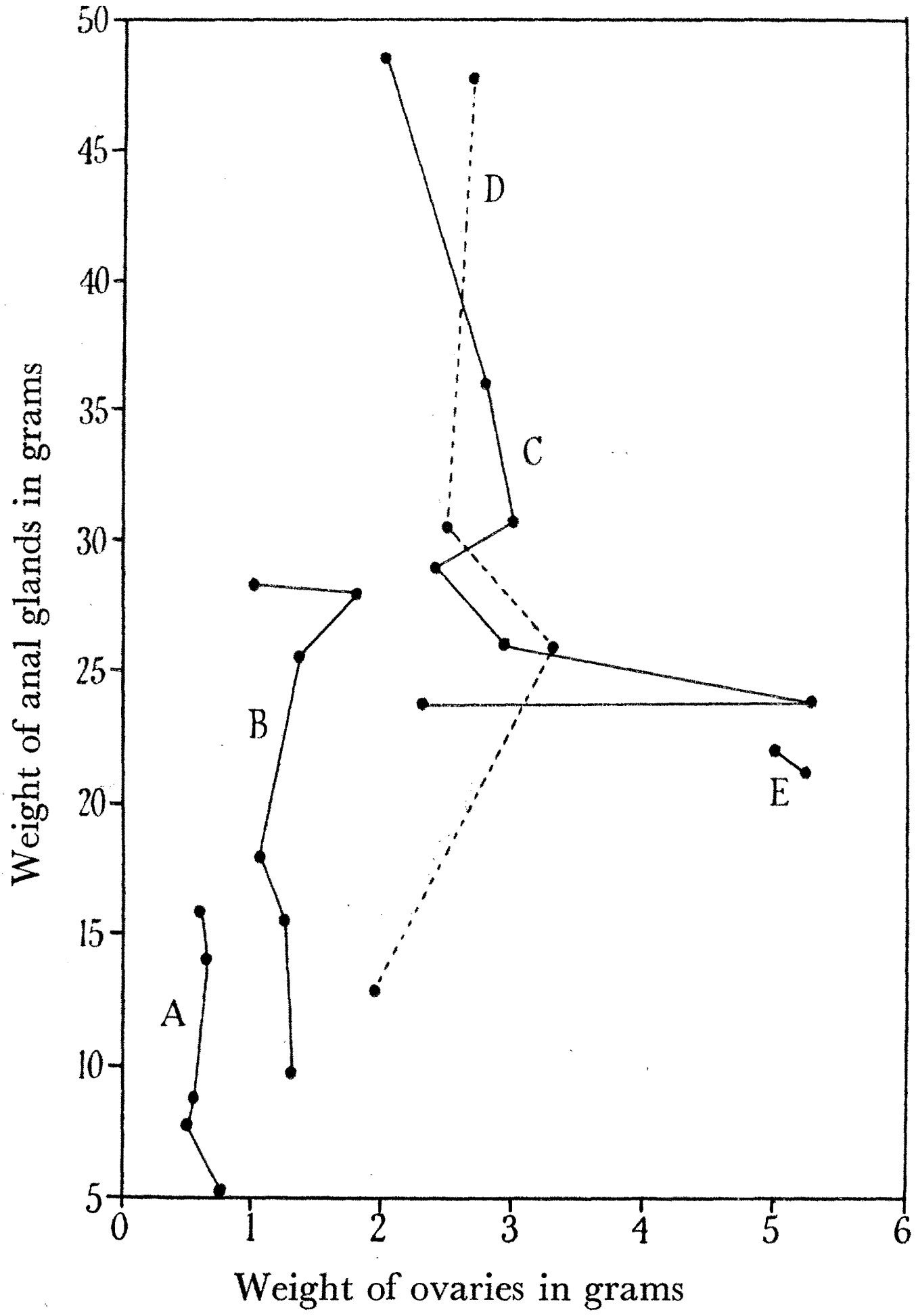

FIG. 32. Relation between weights of ovaries and of anal glands.

The prepubertal group A shows the lowest values, but the other groups have a wide range of variation, and show no correlation with the state of sexual activity. The weight of the glands evidently depends to some extent upon body size and they appear to have no special sexual significance. In view of the fact that the glands are present, and developed to an equal extent, in both sexes, and are thus not secondary sexual characters, this is rather to be expected.

Histology of the genitalia

The ovaries.

General remarks (fig. 55, Plate 6). The ovary is divided into three well-marked regions, the cortex, the peripheral stroma, and the central fibrous stroma. The cortex is covered externally by the germinal epithelium, consisting of a single layer of columnar cells. Immediately internal to the germinal epithelium lies a layer of fibrous tissue 50–70 μ thick, the tunica albuginea. The fibres run approximately parallel to the surface of the ovary, and are gathered into bundles which cross each other in different directions. Within this fibrous coat lies a layer of spindle-shaped connective tissue cells, among which are scattered the youngest follicles, and a few polyhedral interstitial cells similar to those of the stroma. This layer is from 50 to 70 μ thick. Next to it, and bounding the cortex internally, is another layer of fibrous tissue from 50 to 100 μ thick. The fibres of this layer are also arranged approximately parallel to the outer surface of the ovary. At frequent intervals the connective tissue of the cortex is interrupted by strands of fibrous tissue passing through it from the inner fibrous layer towards the outer one.

Within the cortex lies the peripheral stroma. It is composed mostly of polyhedral interstitial cells with large nuclei. Smaller numbers of spindle-shaped connective tissue cells, with elongated nuclei, lie between them. Infrequent strands of fibrous tissue ramify amongst these cells. In the region close to the cortex there are lesser numbers of large polyhedral cells, with smaller nuclei. They are scattered singly, or gathered into irregular masses close to the fibrous layer bounding the inner edge of the cortex, and extend into the stroma as small cords of cells placed side by side. Vessels are not numerous in this part of the stroma. Its thickness varies according to the amount of bulging caused by large follicles or corpora lutea. In ovaries in which it is not distorted by other structures it is from 1·3 to 1·7 mm. in thickness. When follicular growth takes place the follicles migrate from the cortex, through the inner fibrous layer, into the peripheral stroma. It is in this part of the ovary that growing follicles and corpora lutea are found.

Internal to the peripheral stroma lies the central fibrous stroma. It consists of fibrous tissue, with some unstriped muscle fibres, and contains only small numbers of the connective tissue and interstitial cells characteristic of the peripheral stroma. Where these cells occur they are usually clumped together in small islands. This part of the stroma is highly vascular.

Microscopic examination of the present series of ovaries reveals several salient facts.

The most obvious is the very small number of young follicles to be found in the cortex. In every section examined this dearth of young follicles is very striking. The number of growing follicles is likewise few, though when they reach a large size they may occupy a great part of the bulk of the ovary. The corpora lutea are large in size, and their remains persist throughout the life of the animal, as already mentioned. These remains do not consist merely of fibrous tissue, but of luteal cells, which appear to lose their function only very gradually, though they diminish in size soon after parturition. Finally, large numbers of follicles undergo atretic degeneration, usually without the formation of any luteal tissue: sometimes a few luteal cells are recognizable. The atresia, which is described fully in a later section, affects not only small follicles, but large ones that are approaching maturity.

The ovary in group A prepubertal animals differs from that in group B mainly by the smaller degree of development of the follicles. The cortex is from 150 to 200 μ thick. In both groups A and B it contains more small follicles than in the parous animal. In group A a moderate number of growing follicles are to be found in the peripheral stroma, but they rarely reach a size as great as those in group B. Even in group A there are usually a number of atretic follicles in the peripheral stroma. They appear to be derived from follicles which have not reached any great degree of development. In prepubertal animals of group B the cortex is similar, but the peripheral stroma contains follicles which have reached a considerably greater size. Atretic follicles and their remains are of constant occurrence.

Maturity is marked by the onset of the first oestrus and the ripening and rupture of follicles. The largest follicle found in a prepubertal ovary was about 6·0 mm. in diameter: this was in a group B animal which was obviously approaching maturity. When ripe the follicle is 10·0 mm. or a trifle more in diameter. The dearth of small follicles in the cortex is even more pronounced in the mature ovary than in the prepubertal one.

During pregnancy large corpora lutea fill most of the bulk of the ovary. Follicles with antra were found in the ovaries of only one pregnant animal. The foetus in this specimen was the smallest of the series, and measured 80·0 mm. from vertex to rump. The ovaries contained several healthy follicles up to 2·5 mm. in mean diameter, and a number of atretic ones. The healthy follicles were probably those undergoing growth at the last oestrus. Their fate would probably have been to undergo atresia, as a number of others had already done. In the ovaries from all the other pregnant animals no follicles larger than those just beginning to develop antra were found, but atretic follicles were always present. The animals all contained foetuses larger than that previously mentioned: their lengths varied from 145 to 290 mm. from vertex to rump. When pregnancy occurs, then, the maturation of follicles ceases, and the larger ones undergo atretic degeneration.

During lactation the ovary shows some signs of renewed activity. In the earlier stages, as judged by the degree of regression of the corpora lutea, it is no more active than during pregnancy, but in the later stages the growth of the follicles starts. Ovaries from animals in the later stages of lactation show healthy follicles up to 4·0 mm. in diameter, as well as atretic remains. This gradual resumption of activity during the later part of lactation shows that there is no post-partum oestrus.

In the ovaries of parous animals, neither pregnant nor lactating, there is, naturally, a much greater range of activity, depending upon the stage in the sexual cycle through which the individual animal is passing. In the least active state the ovary presents an appearance differing little from that seen in later stages of lactation. As oestrus approaches follicular growth increases, and there is some diminution in size of the corpora lutea, though the rate of regression of the latter is very slow. Comparatively few follicles reach maturity. Though there may be many up to 3 or 4 mm. in diameter present, there are never more than two or three from 6 to 10 mm. in mean diameter in the two ovaries together. There is in consequence always a number of atretic follicles, in various degenerative stages, present in the ovaries.

Growth of the oocyte and follicle. A large number of oocytes and follicles were measured, and the calculated regression lines of the mean diameter of the oocyte on that of the follicle are shown in fig. 33.

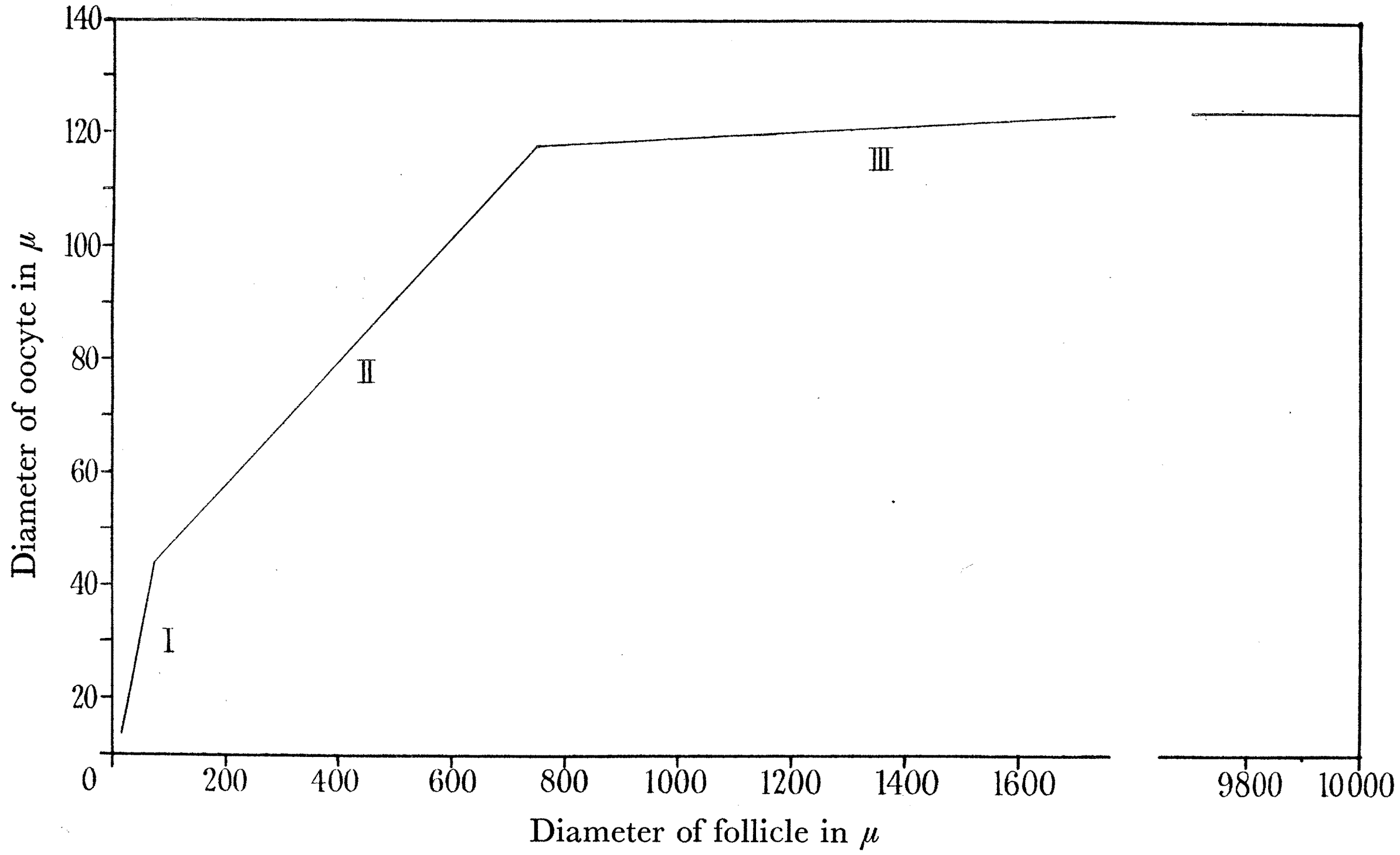

FIG. 33. Regression lines of mean diameter of oocyte on mean diameter of follicle.

The growth of the oocyte and follicle falls into three stages. In the first the oocyte increases in diameter, but throughout it the follicle consists of a single layer of cells only. In consequence the rates of growth of the follicle and oocyte do not differ greatly. In the second stage the growth of the oocyte continues, but follicular growth becomes much more rapid, owing to the proliferation of the follicular epithelium, which becomes many layered. During the third stage the growth of the oocyte stops, but the follicle increases greatly in size with the development of the antrum.

The regression formulae for these stages are:

Stage 1. $y = 4{\cdot}84 + 0{\cdot}5695x$, where $x = 18\text{–}80\,\mu$ (follicle a single layer of cells).

Stage 2. $y = 35{\cdot}4 + 0{\cdot}1109x$, where $x = 80\text{–}800\,\mu$ (proliferation of follicular epithelium).

Stage 3. $y = 113{\cdot}49 + 0{\cdot}0056x$, where $x = 800\text{–}10{,}000\,\mu$ (development of antrum).

The lines derived from these formulae are significant for stages 1 and 2, but not for stage 3. The latter can therefore be represented with equal accuracy by a horizontal line. The average mean diameters of the oocyte and follicle at the end of the second stage of growth are 120 and 800 μ respectively. The ratio of the diameter of the follicle at the beginning of the third stage of growth to that at the end of it is 1 : 12·5.

The first stage of growth (figs. 56, 57, Plates 5, 6). The mean diameters of the smallest oocyte and follicle measured were 14 and 24 μ respectively. At this stage the oocyte contains a large nucleus with well-marked nucleolus, and the follicle consists of a few very flattened cells arranged in a single layer. During the first stage of growth the oocyte increases up to 40 μ in diameter, and the number of cells forming the follicle is greatly increased. They increase in size, so that they are no longer flattened, but form a single layer of polyhedral or cubical cells with conspicuous nuclei, surrounding the oocyte. Outside them a very thin layer of flattened cells represents the theca.

The second stage of growth. The second stage of growth is characterized by the proliferation of the epithelium, while the oocyte increases from a mean diameter of 40 to one of 100–120 μ. In the earlier part of this stage the follicle consists of two layers of cubical cells. The nuclei are placed at the bases of the cells; those of the inner layer are at the bases of the cells adjacent to the oocyte, and those of the outer layer at the bases of the cells adjacent to the theca. A zone of clear cytoplasm thus separates the nuclei of the two layers. In the later part of this stage the inner layer gives rise to the discus proligerus and the outer one to the membrana granulosa. The theca is represented only by a thin layer, one or two cells thick, of very much flattened cells with elongated nuclei.

As growth continues a reticulum of polyhedral cells, with rather large nuclei, is developed between the two layers of the follicle cells, so that the distance between them is greatly increased. The nuclei of the two primary layers remain at the bases of the cells, forming one layer lining the follicle, and another surrounding the oocyte. During this proliferation of the epithelium the zona pellucida, surrounding the oocyte, becomes defined. At this period of growth the theca has increased in thickness and shows differentiation into separate parts. The membrana propria lies internally and consists of a layer of flattened cells, one or two cells thick. The theca interna and externa are not readily separable. Together they form a zone 5 μ thick in a follicle 200 μ in mean diameter. They consist of a number of flattened cells with elongated nuclei, interspersed with larger polyhedral cells with round nuclei and abundant cytoplasm. The two different kinds of cells are not separated into individual layers (fig. 58, Plate 6).

The third stage of growth. The third stage of follicular growth is characterized by the formation of the antrum, and the termination of the growth of the oocyte. When the mass of cells, lying between the layer surrounding the oocyte and that lining the follicle, is six to eight cells thick, the follicular fluid appears and splits the mass into two portions of roughly equal thickness. The first trace of the antrum appears at a single point, and extends, as it splits the two layers apart, until it almost surrounds the oocyte, which is left attached to one side of the follicle wall. The membrana granulosa and the discus proligerus are thus separated and only remain in contact in the region of the cumulus (fig. 59, Plate 7).

The membrana granulosa now consists of a basal layer of columnar cells with the nuclei close to the wall of the follicle, and an inner layer of polyhedral cells, with large central nuclei, three to ten cells deep. In stained preparations the cytoplasm of the internal ends of the basal cubical cells forms a band of clear tissue between the peripheral nuclei and the inner cells. The discus proligerus consists of an inner layer of more or less cubical cells surrounding the oocyte. Their nuclei lie nearer the inner ends than the outer, so that there is a marked concentration of the nuclei at one end of the cells, similar to that seen in the outer layer of the membrana granulosa. Outside the inner layer lies a layer of polyhedral cells, with large nuclei, three to five cells deep. At the cumulus the polyhedral cells of the membrana granulosa and the discus proligerus are both greatly increased in numbers, and join to form a continuous mass of cells, all of exactly similar character.

The theca interna consists of a mixed layer of spindle-shaped flattened cells, with elongated nuclei, and polyhedral cells, with round nuclei. Within it lies a very thin layer of flattened cells forming the membrana propria. At the outer surface of the theca the polyhedral cells are reduced in number, so that the theca externa is formed of a thin layer, about four cells thick, of flattened cells with elongated nuclei. The division between the theca externa and interna is not, however, distinct, the two layers merging into each other.

The following measurements were taken from a follicle 700μ in mean diameter, which was in the earlier part of this stage of growth. The membrana granulosa was 50μ thick, the discus proligerus 180μ in diameter, the oocyte 100μ in diameter, and the theca 80–100μ in thickness. The distance from the oocyte to the follicular wall, measured through the cumulus to the outer edge of the membrana granulosa, was 200μ.

The conditions in the mature follicle measuring 1 cm. in diameter are essentially similar. The histology of the various parts of the follicle and its contents is unaltered, and the only difference of importance is that in the mature follicle the theca is slightly thickened, measuring 150–200μ in thickness.

Atresia. Follicular atresia is very common in the ovaries of the spotted hyaena. It occurs both in small follicles and in large ones approaching maturity. Two kinds of atresia were observed. In the commonest type, which was found in animals of all ages, both prepubertal and adult, atresia starts with a degeneration of the follicular epithelium (fig. 60, Plate 7). First the membrana granulosa degenerates, the cell walls disappear, and the nuclei become scattered in the swollen cytoplasm. Invasion of the mass by the connective tissue cells of the theca then takes place. The process, starting in the membrana granulosa, gradually extends to the discus proligerus, the outer parts of which are the first to suffer. At the same time the nucleus of the oocyte degenerates and the cytoplasm becomes shrunken and vacuolated. The zona pellucida, however, remains very prominent throughout the process. In the larger follicles the antrum remains filled with fluid until a late stage in the degeneration (fig. 61, Plate 7).

After the membrana granulosa and the discus proligerus have both entirely disappeared the follicle becomes completely filled with connective tissue (fig. 62, Plate 8). At the same time it shrinks in size, but the cytoplasm of the oocyte, with a well-defined zona pellucida, yet remains intact. It is not until the connective tissue becomes invaded by interstitial cells, so that the remains of the follicle become indistinguishable from the stroma of the ovary, that the oocyte finally degenerates and disappears.

In the second, and much more rarely observed, type of atresia, formation of tissue closely resembling that of the corpus luteum takes place. The first stages of degeneration are similar, but a number of enlarged cells are to be found among the proliferating connective tissue cells of the theca. It was not possible to trace the origin of these cells exactly, but the presumption is that they are cells of the membrana granulosa, which undergo hypertrophy instead of atrophy. The oocyte appears to degenerate at an earlier stage in this type of atresia. The follicle finally shows a thin wall of connective tissue surrounding a mass of cells of the same general shape, appearance and staining reactions as true luteal cells. They are, however, smaller in size than the young luteal cells of a functional corpus luteum. The size of such an atretic follicle is only a minute fraction of that of a true corpus luteum. This type of atresia occurs in prepubertal as well as adult animals. Fig. 63, Plate 8 shows such an atretic follicle in the ovary of a prepubertal animal (group B), which was virgin and had never ovulated.

The corpus luteum. The life of the corpus luteum can be traced in the present series of specimens, from an early stage, through pregnancy, lactation and anoestrus, to a degenerate state in later pregnancies.

The youngest corpus luteum was found in an animal which had very recently ovulated. The ovum was not found, but no trace of the implantation of the blastocyst was apparent in the uterus. If fertilization had occurred the blastocyst was either in the fallopian tube or, if in the uterus, was as yet unattached. The corpus luteum measures 10 mm. in mean diameter, and is characterized by a large central space filled with blood clot, composed of fibrin and red corpuscles. The whole of the remaining follicular space is filled with luteal cells, which are bunched together in large masses separated by narrow strands of connective tissue arranged radially. Numerous spindle-shaped connective tissue cells are scattered among the luteal cells. The luteal cells are irregularly polyhedral in shape, and measure 20–30 μ in diameter. They have large nuclei, with well-defined nuclear membranes, and the chromatin is usually gathered into a conspicuous nucleolus. The cytoplasm of many of the luteal cells shows a vacuolated appearance (fig. 64, Plate 8).

In the corpus luteum, 11 mm. in diameter, from the ovary of the animal carrying the youngest pregnancy, a foetus 80 mm. in length from vertex to rump, the central space is reduced in size, and the clot of fibrin and red corpuscules has been resorbed. The cells are more evenly spaced and not clumped into islands, as in the younger state. The organ is now highly vascular and contains numerous blood vessels. The cells are much more regular in shape, and each lies, separated from its neighbours, in a network of connective tissue cells. The luteal cells are now 30–60 μ in diameter. The cell contents are more homogeneous, and do not commonly show a vacuolated structure. The nuclei, still frequently characterized by a well-marked nuclear membrane and nucleolus, usually lie to one side of the cell, as though pushed there by the abundant contents (fig. 65, Plate 9).

In a later stage of pregnancy, about half-term, the mean diameter of the corpus luteum is 14 mm. The central cavity is practically obliterated, and the peripheral cells are similar to those just described. The more central cells are, however, smaller and rather lenticular in shape, measuring only 30–40 μ in mean diameter. The characters of their nuclei and contents appear to be unaltered (fig. 66, Plate 9).

The corpus luteum in a late pregnancy, nearly at full term, is 9 mm. in mean diameter. Many of the luteal cells are somewhat shrunken, and there is a considerable degree of proliferation of connective tissue cells filling the spaces between them. The nuclei have undergone no change (fig. 67, Plate 9).

In the early stages of lactation no further degenerative changes are to be found; in fact the corpus luteum often presents a surprisingly healthy appearance (fig. 68, Plate 9). As lactation progresses the central part of the corpus luteum first shows signs of decreasing activity. Here the cells are shrunken to a mean diameter of 20 μ or less, and become comparatively widely scattered in a background of connective tissue. At the same time the peripheral parts of the corpus luteum remain functional in appearance. As lactation proceeds these changes become progressive, and at the end of lactation the luteal cells are only 15–20 μ in mean diameter, and are widely separated by connective tissue. At the same time their contents become darker, both in their staining reaction, and in the tint that they impart to the corpus luteum when viewed by the naked eye (fig. 69, Plate 10).

After weaning the process of regression continues, but at a slow rate. The luteal cells gradually shrink in size and decrease in number, while the proportion of connective tissue increases. Macroscopically, the corpus luteum decreases in size to only a few millimetres in diameter, and becomes very dark brown in colour. But it appears that as the corpus luteum grows older its rate of regression decreases. The process of regression is marked by the development of numerous vacuoles in and between the luteal cells (fig. 70, Plate 10). The development of vacuoles is not regular in its onset, for though they are always present in old corpora lutea, they are sometimes present in much younger ones (fig. 71, Plate 10). The vacuoles are not post-mortem products, as is shown by their occurrence only in the older corpora lutea from ovaries showing excellent fixation of the other structures, including younger corpora lutea. The very old corpora lutea, composed of shrunken luteal cells, with dark contents, and large quantities of connective tissue, exist in ovaries which contain younger corpora lutea and follicles in all stages of maturation (fig. 72, Plate 10). No further degenerative stages have been found, so that it appears likely that after reaching this state the process of regression becomes so slow that the corpora lutea never completely disappear.

The fallopian tube.

The fallopian tube is from 1·5 to 3·0 mm. in diameter and presents no unusual features of interest. It is provided with the usual muscular coats, and the mucous membrane is thrown into folds of considerable complexity in transverse section. It is lined by a columnar ciliated epithelium. In consequence of the larger diameter of the tube in the adult, the complexity of the folding of the mucous membrane is greater than in the immature animal. The present material affords no evidence of any cyclical change in the histological structure of the fallopian tube during the sexual cycle: the slight differences between specimens appear to be nothing more than individual variations.

The uterus.

The uterine cornua show, in transverse section, a longitudinal muscle layer, a vascular layer, a circular muscle layer and the mucosa. The longitudinal and circular muscle layers are not sharply separated, and fibres from the two intermingle where they meet. The vascular layer lies in the neighbourhood of the junction, but is rather diffuse, and tends to invade the circular muscle layer. The mucosa has a poorly developed muscularis layer, and consists mostly of stroma which contains many spindle-shaped cells. It is lined by a layer of cubical epithelium, one cell thick, which is continuous with the epithelium lining the glands. The body of the uterus consists of essentially the same layers. The circular muscle layer is, however, very much thicker than in the cornua, especially on the dorsal side, the organ being flattened dorso-ventrally as it lies in its natural position in the body. On this side too the muscularis mucosae is greatly thickened and forms a layer of fibres, many of which are directed vertically towards the lumen of the organ. The bases of the glands penetrate this layer, which is sharply defined from the rest of the mucosa by the small number of spindle-shaped cells within it. The rest of the mucosa is thinner than in the cornua, and the glands are more infrequent. There is, however, no sharp distinction between cornua and body, and the conditions typical of the one pass gradually into those of the other.

In animals of prepubertal group A the layers of the cornu are thin, and the glands are few and small (fig. 73, Plate 11). The longitudinal and circular muscle layers are about equal in thickness, and, together with the vascular layer, measure 200–350 μ in thickness. The mucosa is also from 200 to 350 μ in thickness; the glands do not extend far below its surface, and follow straight paths with no convolutions. They are about 20 μ in diameter, and are usually without lumina. The surface of the mucosa is, for the most part, smooth. There is, however, some tendency, in the older examples, towards the formation of ridges, especially at the mesometrial, and, to a less extent, at the anti-mesometrial, sides. The lumen thus frequently appears Y-shaped in transverse section. In the body of the uterus the part of the mucosa thickened by the great development of the muscularis mucosae measures up to 500 μ, and the circular muscle layer up to 1000 μ, in thickness. The glands are few in number and mostly small in size. The surface of the endometrium is thrown into a few low ridges only at the lateral borders of the lumen.

In animals of prepubertal group B the uterine cornu shows considerable growth changes in both muscle and mucous layers. There is, however, little increase in the number or size of the glands. The mucosa and the circular muscle layer are from 250 to 500 μ in thickness, and there is a corresponding increase in the thickness of the vascular and longitudinal layers. There is a further formation of ridges in the mucosa, the most constant of which are a median and a pair of lateral ones at the mesometrial side, giving a Y-shaped lumen in transverse section. In those animals which are approaching sexual maturity there is a very high degree of vascularity. This is seen not only in the vascular layer, but also in the mucosa itself, which is filled in all directions by numerous blood vessels (fig. 74, Plate 11). On the other hand, in the animal which appears to be nearest to its first oestrus, this excessive vascularity is absent, and the lumen of the uterus is distended with secretion. The mucosa here is not increased in thickness, but there is a striking increase in the number of the glands, though their size is unaltered. In the body of the uterus the circular muscle layer measures up to 1500 μ in thickness, and the mucosa about 500 μ, of which more than half is occupied by the muscularis mucosae. The glands in most examples are still few and small, but in those specimens most advanced towards sexual maturity there is a notable increase in their numbers. In most of these, too, the surface of the endometrium is thrown into well-marked longitudinal ridges. In the animal furthest advanced towards the first oestrus the mucosa measures up to 800 μ in thickness on the ridges, the bulk of which is produced by an increase in thickness of the muscularis mucosae.

Coming now to the adult, the uterus during lactation is first considered, because it presents an extreme degree of involution and is typical of anoestrus. In the cornu the mucosa presents an appearance closely similar to that seen in the young prepubertal stage. Its surface is smooth and not thrown into longitudinal ridges: the glands are small and few in number. Its thickness varies from 150 to 500 μ. Its circular muscle layer is from 200 to 400 μ, and the longitudinal layer from 300 to 400 μ thick. The vascular layer is from 100 to 200 μ thick, and the enlarged blood vessels are all strongly hyalinized so that their lumina are eventually obliterated. The main difference from the prepubertal cornu is, then, the greater thickness of the muscular and vascular layers. The condition seen in the body of the uterus is very similar, except that glands are scarcer and the muscularis occupies a proportionally greater part of the mucosa (fig. 75, Plate 11).

During anoestrus in the parous animal the uterine cornua and body differ in no essential from the state found during lactation, except that the hyalinized blood vessels tend to be reduced in size. Involution is evidently completed during lactation, and the process can go no further thereafter, either in the mucosa or the muscular layers.

At pro-oestrus considerable growth changes take place (fig. 76, Plate 11). The mucosa increases to a thickness of 600–800μ, and there is a great increase in the number of glands which are closely packed side by side in the outer half of the mucosa. The surface of the mucosa is divided into longitudinal ridges by the formation of deep intervening valleys. In the later stages the lumen of the cornu becomes filled with secretion, and the ridges come into prominence as the valleys between them open out under the distension. In the later stages, too, the glands increase in length and invade the deeper parts of the mucosa. The mucosa becomes highly vascularized, but the material available provides no evidence of the extravasation of corpuscles, nor of the shedding of epithelium. The epithelium, however, appears to be reduced in thickness, and is seen as a thin layer of cells 8–10μ thick. The muscular coats of the cornu increase with the growth of the mucosa and reach a thickness of 2–3 mm. The vascular layer does not greatly increase in thickness.

In the body of the uterus similar changes take place, but the main growth occurs in the muscular layers rather than in the mucosa. The latter reaches a thickness of not more than about 500μ, whereas the muscular layers increase to a thickness of about 5 mm. Glands are more plentiful than in the anoestrous state, but they are never so numerous nor so large as in the cornua.

At oestrus the growth changes are carried much further both in mucosa and muscle. In the cornua the mucosa is increased to about 1200μ in thickness, except in the valleys between the ridges where it is 300–400μ thick. The glands are greatly increased in number and size. They completely fill the mucosa, penetrating quite to its base. Their diameter is 30–40μ, and they have well-defined lumina. The strands of stroma separating the glands are about equal in width to the diameter of the glands. The glands are not convoluted, but pursue a nearly straight path to the base of the mucosa. The vascularity of the mucosa, so conspicuous in pro-oestrus, has now completely disappeared and blood vessels are small and few in number (fig. 77, Plate 12). The muscular layers are about 3 mm. in thickness, and the vascular layer shows a great increase in activity, all the vessels being much enlarged and engorged with blood.

In the body of the uterus most of the growth takes place in the muscular layers. The mucosa is increased in thickness to 500–800μ, and there is a considerable increase in the number and length of the glands. They do not, however, penetrate far into the muscularis mucosae. The muscular layers reach a thickness of 8 mm., most of the growth occurring in the longitudinal, rather than in the circular, layers. The vascular layer, too, shows a considerable increase in activity.

In very early pregnancy, before the implantation of the ovum, the uterus shows the changes which take place in response to the action of progestin. In later stages examination of the sterile cornu, or of the tip of the pregnant cornu which is unoccupied by the pregnancy, shows the characteristic changes of pseudopregnancy, whether or not that phenomenon ever occurs as such in nature. In the cornu the progestational proliferation is characterized by an increase in thickness of the mucosa to 1500–2000 μ, and by great development of the glands (fig. 78, Plate 12). These now entirely fill the mucosa and are separated from each other only by narrow strands of connective tissue. They increase in size towards their bases, where they reach a diameter of 60–70 μ. The mucosa in the body of the uterus shows similar changes, but it is not so thick, and the glands, though almost equally numerous, are smaller in diameter.

In a later pregnancy the non-pregnant cornu and the sterile part of the pregnant one are similar to each other, and show an increase in thickness of the mucosa to 3 mm. The glands are very much enlarged, and have wide lumina 100 μ in diameter. They are separated from each other by very narrow strands of tissue, within which run the capillaries. The glands in many places show a breakdown of the epithelium, the remains of which, together with their secretion and some extravasated blood, fills the enlarged lumen of the cornu. At the base of the mucosa lies the muscularis mucosae, forming a layer about 200 μ thick. At their bases the glands narrow abruptly in diameter from about 100 μ to about 20 μ, and turning at right angles, enter the muscularis, within which they run approximately parallel to the surface (fig. 79, Plate 12). The junction of the muscularis with the highly glandular part of the mucosa is the line of division between the deciduous part of the mucosa and that part which regenerates after parturition. The two lateral ridges, which gave the lumen of the cornu a Y-shaped section in the stages of lesser activity, are now prominently developed, and their bases are composed largely of muscularis, into which the narrow ends of the enlarged glands extend. The diameter of the cornu is here about 10 mm. There is a wide lumen, and the muscular coats are reduced in thickness to 1–2 mm.

A later stage of pregnancy shows these changes carried further. The cornu measures 20 mm. in the mesometrial-antimesometrial axis, and about 10 mm. in the axis at right angles. The lumen is large: the muscular coat is reduced to 1–2 mm., and the mucosa to little more than 1 mm., in thickness. The glands are still wide in diameter, but show gross degenerative changes. Many of them are filled with colloid secretion and cell debris, and all are actively degenerating. The lumen of the cornu is distended by a pasty mass consisting of this secretion together with the glandular remains and some extravasated blood corpuscles. The strands of tissue lying between the glands degenerate with them. The whole of the glandular part of the mucosa is thus in process of being shed into the lumen of the uterus, but the epithelium of the flattened bases of the glands remains behind (fig. 80, Plate 13). The uterine epithelium is regenerated by the proliferation of the epithelium of the gland bases, which bridges the spaces intervening between the glands, covering the sites of the strands of tissue that formerly separated them. The narrow tails of the glands extending into the muscularis are lined by epithelium continuous with that of the new surface of the mucosa.

The thickened glandular part of the mucosa has, presumably, completely degenerated by the time of parturition (or the end of pseudopregnancy) and the debris would then be expelled. The uterus would then be left with a very thin mucosa, containing a small number of tiny glands which, as soon as the muscular layers had involuted, would present the completely anoestrous condition typical of lactation. Fig. 34 summarizes diagrammatically the cycle in the mucosa.

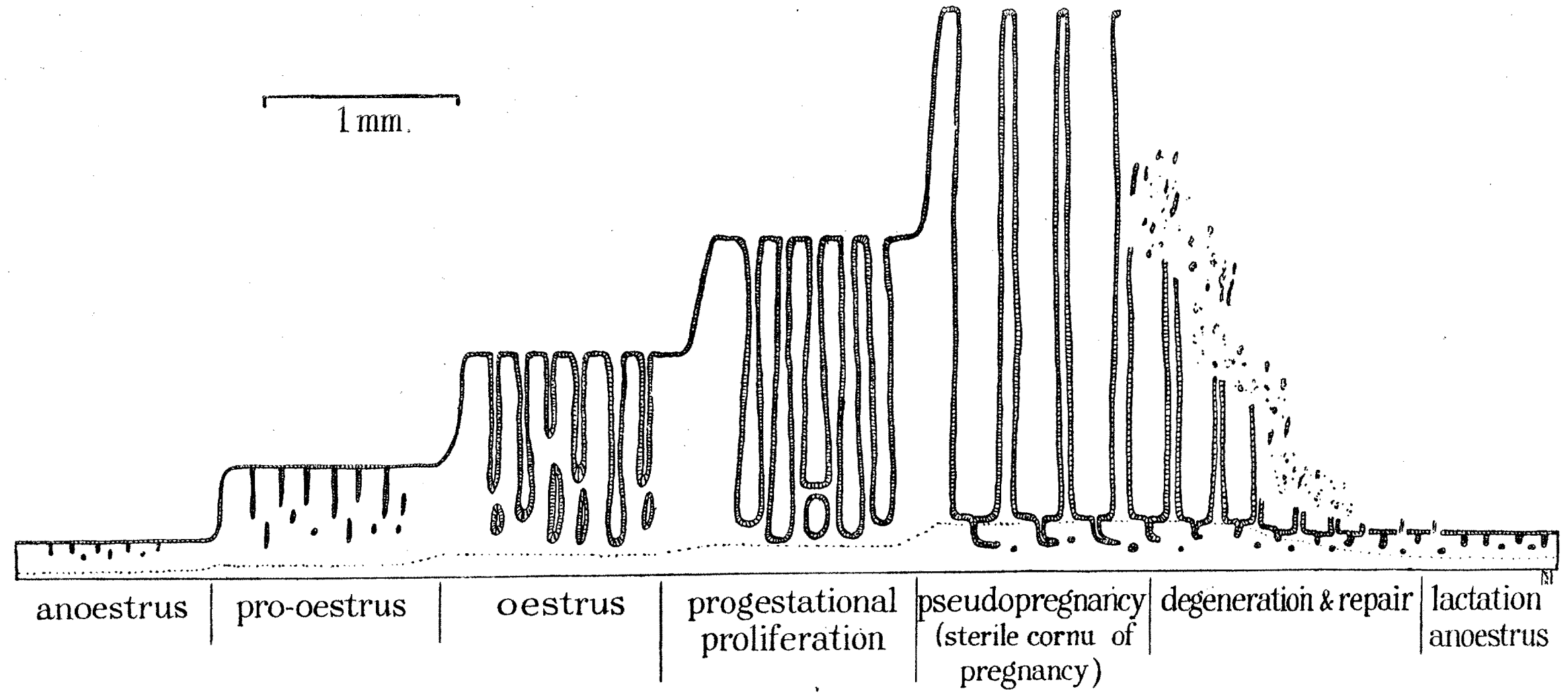

FIG. 34. Diagram of the cycle in the uterine mucosa, with pseudopregnant changes in the sterile cornu.

The vagina.

The vagina consists of an outer muscular coat, containing both longitudinal and circular fibres, and a mucous membrane with a vascular corium. The changes occurring in the corium and epithelium during the sexual cycle are those of chief interest.

In all the prepubertal animals the organ is small and its muscular coat is comparatively thin, not exceeding 2 mm. in thickness in any specimen. The muscle consists almost entirely of circular fibres, very few longitudinal ones being present. The corium is 100–200μ in thickness and very poorly vascularized. The epithelium, 20–30μ thick, consists of one or two layers of columnar cells, bounded at the lumen of the organ by low stratified cells. The wall of the lumen is thrown into a number of large longitudinal folds, but there are no microscopic papillae of the corium forming projections into the epithelium (fig. 81, Plate 12).

In the parous anoestrous animal the organ shows a great increase in size over that of the prepubertal animal (fig. 82, Plate 13). The muscular coats are 2–3 mm. thick, and the mucous membrane measures up to 2 mm. in thickness on the longitudinal ridges. Longitudinal fibres are now numerous in the muscular coat, especially towards its outer boundary. The corium, compared with that in the prepubertal condition, is highly vascularized, containing a great many small vessels. The epithelium is 30–40 μ in thickness, and consists of a layer of cubical and polyhedral cells with large nuclei, four or five cells in thickness, covered by a single layer of stratified cells. The boundary of the corium towards the lumen of the organ is now thrown into a number of microscopic papillae. The outer surface of the epithelium follows the outline of the papillae in some places; but in others it bridges the spaces between them, so that they are filled up and the epithelial surface above them is flat.

At pro-oestrus the muscular coat is increased a little in thickness, up to a maximum of about 5 mm. The vascularity of the corium is greatly intensified, and the numerous vessels are now widely engorged with blood. The number of papillae at the epithelial boundary of the corium is greatly increased, but the gaps between most of them are still bridged by the epithelium. The epithelium is now 100–200 μ in thickness and forms a layer eight to ten cells deep. The cells are mostly polyhedral and, owing to their increase in size and their clear contents, the nuclei appear to be comparatively smaller. The basal layer of cells, however, remains cubical or columnar, and is not thus enlarged: the nuclei consequently appear to be much more closely crowded. The cells of the surface layer, bounding the lumen, undergo a process of mucification and contain large vacuoles. Their nuclei are frequently pycnotic and they become detached in some numbers from the underlying epithelium. The outer surface is covered in many places by a thin layer of the flattened cornified remains of their predecessors.

At oestrus there is great hypertrophy of the inner layer of the vaginal wall (fig. 83, Plate 13). The muscular coat remains from 3 to 4 mm. in thickness, but there is a great proliferation of the corium and epithelium. The corium is from 6 mm. thick on the ridges to 2 mm. in the valleys between them, and is highly vascularized. The epithelium is from 300 to 400 μ thick and now consists of two distinct strata. It entirely fills the spaces between the papillae of the corium, so that their profile is not followed by the surface layer of the epithelium. The papillae are now narrower in diameter, as though squeezed out by the hypertrophy of the epithelium. The basal stratum of the epithelium, 100–150 μ in thickness, consists of two parts. There is a deep layer, one cell thick, of narrow columnar cells, containing darkly staining nuclei, butting on to the corium. Superficial to this is a layer, six to eight cells in thickness, of large polyhedral cells. They have clear contents and large clear nuclei containing faintly staining chromatin granules, either scattered or clumped together. The cells of this layer become more and more flattened the farther they lie from the basal stratum, and are lenticular in shape at the surface.

The second stratum of the epithelium, 150–300 μ in thickness, consists of cornified cells. Throughout most of its depth it consists of many superimposed layers of cornified cells without nuclei or other structure. At its base there is a transitional zone, which is quite sharply defined, where it joins the stratum already described. At this level the superficial lenticular cells of the first stratum become greatly flattened and their nuclei degenerate. The contents of the cells, however, are darker staining than those either of the cornified stratum, into which they are later transformed, or of the lenticular cells from which they are derived. After the degeneration of the nuclei the cornified cells are desquamated in larger or smaller masses into the lumen of the vagina, which becomes filled with a pasty mass composed of their remains together with the secretions received from the upper parts of the genital tract.

At the end of oestrus the whole of the cornified part of the epithelium is lost together with the superficial cells of the deeper layer. During pregnancy the muscular coat is 2–4 mm. in thickness, and the corium not more than 1–3 mm. thick (fig. 84, Plate 13). The vascularity of the corium is greatly decreased by the shrinking in the size of the blood vessels to inconspicuous capillaries, though their numbers do not appear to be diminished. The epithelium is no more than 50μ thick at its greatest, and, owing to the loss of its superficial layers, it no longer bridges the gaps between the papillae of the corium. The consequence is that the lumen of the organ now dips down between each of the papillae, and will thus be ready to undergo great distension at parturition. The epithelium is three to five cells deep, and again consists of cubical and polyhedral cells. These, in the more superficial parts, are larger and have clearer contents than those in the more basal one. In the outer part many of the cells contain vacuoles, presumably of mucin, and the surface is bounded by a single layer of very thin flattened and degenerate cells.

During lactation there is considerable involution of the vagina. The layers decrease in thickness, the muscular to about 2 mm. and the corium to about 1 mm. The large longitudinal ridges undergo much atrophy, and the papillae of the corium are much reduced in number. The epithelium is $30–40\mu$ in thickness, and its component cells are unchanged in character. The process of involution leads directly to the conditions found in anoestrus, as already described.

Bartholin's glands.

These, like the Cowper's glands of the male, are tubo-racemose glands, lined by secretory epithelium. In the prepubertal animal the alveoli are $20–30\mu$ in diameter, and are embedded in a mass of connective tissue, which separates adjacent alveoli from each other, and within which small capillaries are contained (fig. 85, Plate 14). The alveoli are lined by a cubical epithelium one or two cells deep, with large nuclei which fill most of the space within the cells. In the anoestrous parous animal the alveoli are of about the same diameter, but appear to be more numerous, so that the connective tissue separating them is smaller in amount. They are lined by a single layer of large cubical cells, whose conspicuous nuclei lie near their bases. The lumina of the alveoli are much reduced or absent, being largely filled by the outer ends of the epithelial cells. The contents of the cells, though not clear, do not contain obvious granules.

At pro-oestrus the connective tissue is much reduced and highly vascularized, being filled with large capillaries ramifying in all directions (fig. 86, Plate 14). The alveoli are about 50μ in diameter, and now have conspicuous lumina: the epithelium is unchanged in character and consists of cubical cells with prominent nuclei lying near their bases.

At oestrus the connective tissue appears only as very narrow strands separating the alveoli, and its vascularity has now disappeared. The alveoli have large lumina, and their epithelium is a single layer of large cubical cells, with clear cytoplasm, and small flattened nuclei lying closely pressed to the bases of the cells. The diameter of the alveoli is 50–100μ (fig. 87, Plate 14).

During pregnancy the gland remains active. The alveoli are little reduced in diameter, but the cells of the epithelium are smaller. The nuclei, which still lie near the bases of the cells, are again circular and conspicuous, while the cytoplasm is less clear than it was during oestrus.

In early lactation the connective tissue of the gland is again highly vascularized, but by the end of lactation the involution is complete, and the gland is indistinguishable from that typical of the anoestrous state.

The anal gland.

The histological structure of the anal gland differs in no way from that of the male already described. There is no evidence of any increased or decreased activity during any part of the sexual cycle. The gland must therefore be taken to be of social, rather than of sexual, significance, although, as recorded by Grimpe (1916) and Schneider (1926), it is undoubtedly of importance in the sex-play that precedes pairing.

The mammary glands.

In the prepubertal animal the mammary tissue is invisible to the naked eye. In sections, a very small amount of glandular tissue is seen amongst the areolar and fibrous tissue beneath the skin. It consists of ducts 30–50μ in diameter. They are lined by epithelium composed of a basal layer one cell thick, of large cubical cells with clear contents, and a superficial layer lining the lumen. This is composed of small cubical cells containing large nuclei filling most of the space within them.

In the anoestrous parous animal, the mammary tissue, though small in amount and difficult to recognize macroscopically, occurs in larger quantity. It is composed of ducts and closely crowded alveoli, the latter measuring 20–40μ in diameter. The alveoli are lined by a single layer of cubical cells having conspicuous nuclei of comparatively large size. The cells are large, so that the lumina of the alveoli are very much reduced in size, or altogether absent.

At pro-oestrus and oestrus, in the parous animal, the condition of the mammary gland appears to be exactly similar: no increased activity is indicated.

During pregnancy there is a great increase in the size of the glands, the number of lobules and alveoli. At about half term the alveoli are 40–50μ in diameter, with well-defined lumina, circular in transverse section. The epithelium is two to three cells deep, and consists of cubical cells with clear contents and well-marked nuclei: the superficial cells lining the lumina are cubical, like the underlying ones, and not flattened. At full term, but before parturition, the alveoli are in active secretion and are 50–120μ in diameter. They are lined by a single layer of flattened cubical cells, and the lumina, which are more or less circular in transverse section, are distended with secretion. The connective tissue between the alveoli is reduced to very much attenuated strands.

During lactation the alveoli are up to 200–250μ in diameter, and of very irregular shape in transverse section. They are lined by a single layer of much flattened epithelial cells. Here and there, alveoli in the resting stage can be seen, and in them the epithelium is composed of cubical or columnar cells with conspicuous nuclei. There is no evidence of the shedding of any epithelial cells from the walls of the alveoli: occasional cells seen lying in the milk in the alveoli appear to be leucocytes that have migrated through the epithelium. They are smaller in size than the epithelial cells, and their cytoplasm is much clearer.

In early anoestrus, before the involution of the gland is quite complete after the end of lactation, the alveoli are 30–100μ in diameter and of irregular shape in transverse section. They are lined by a single layer of cubical epithelial cells with dark-staining cytoplasm and conspicuous nuclei. The connective tissue strands between the alveoli are penetrated by numerous prominent capillaries.

The milk ducts are ten to twelve in number. In the nipple of the parous animal they are arranged in a ring amongst the fibrous and areolar tissue, and terminate at the summit of the nipple in a ring about 1 cm. in diameter.

Ovulation from alternate ovaries

The considerable difference in size between the ovaries of the two sides of the body gives the impression that ovulation may occur from one ovary only at each oestrus. Table XVII shows the average value, for each category of animals, of the weight of the smaller ovary expressed as a percentage of the larger. If the weights of the ovaries were equal the figures would be 100: the further the weights diverge, the lower is the figure. In all the animals of prepubertal group A the ovaries are approximately equal in size, but in the animals of prepubertal group B only one-quarter have ovaries approximately equal, and three-quarters have one very definitely larger than the other. The greater size of one ovary in this group is due to the larger size or number (or both) of the follicles in one ovary. The ovaries of the prepubertal animals that are approaching sexual maturity thus appear to show a marked inequality in their preparation for the first oestrus. They therefore support the view that ovulation commonly occurs from one ovary only at each oestrus. Further support is lent by the ovaries of a lactating animal, in which one ovary contained no corpora lutea and the other only one, and by those of an anoestrous parous animal, in which one ovary contained three corpora lutea and the other none. In the first of these pregnancy had occurred at the first ovulation of the first oestrus. In a pro-oestrous animal, too, one ovary contained two large follicles about 6 mm. in diameter and many smaller ones, while the other ovary contained only one or two very small follicles. In addition, one pregnant animal carried four large young corpora lutea in one ovary, while all the other corpora lutea in both ovaries were all obviously older and derived from previous oestrous periods.

TABLE XVII. AVERAGE WEIGHT OF THE SMALLER OVARY EXPRESSED AS A PERCENTAGE OF THAT OF THE LARGER, FOR EACH GROUP ACCORDING TO SEXUAL ACTIVITY

Prepubertal, group A	86
Prepubertal, group B	77
Parous (anoestrous)	67
Lactating	68
Pregnant	57

On the other hand, although one ovary was markedly larger than the other in nearly all the remaining parous animals, including those pregnant and lactating, it is by no means always certain that the largest corpora lutea in the larger ovary are younger than some of those in the smaller one. They may be, but neither macroscopic nor histological examination settles the point. It must be remembered, too, that the small number of foetuses in the litter (usually two) increases the chance of both being derived from one ovary, even if ovulation occurs from both. Further, in a specimen killed at oestrus, one ovary contained a 10 mm. follicle ready for dehiscence and several smaller ones up to 5 mm. in diameter, while the other contained a follicle 6 mm. in diameter and several smaller ones. In this animal, therefore, it appeared that ovulation would have occurred from both ovaries. To set against this negative evidence is the proposition that, if pregnancy occurs, there appears to be no reason why corpora lutea, derived from the follicles that have released ova which have missed fertilization, should not be developed to an equal extent as those derived simultaneously from the follicles which gave rise to the pregnancy.

Without further data it is impossible to come to any conclusion more definite than that ovulation sometimes occurs from one ovary only, and that the general appearance of the ovaries gives the impression that this may be so commonly.

Number of ova shed

The number of ova released at each oestrus appears fairly often to be in excess of the number of foetuses in the litter. The number of foetuses found in the present series was one or two; Schneider (1926) records one litter of three. The number of young, and apparently contemporary, corpora lutea in the ovaries of the pregnant animals, however, was from two to four. Similarly in the lactating animals the number of the youngest generation of corpora lutea was from two to five, except in the specimen, mentioned above, which contained only one corpus luteum between the two ovaries. The corresponding numbers in anoestrous parous animals were one to five. The frequency of occurrence of the different numbers of corpora lutea, for all these classes together, is shown in Table XVIII. In 41·6 % of occurrences the number of corpora lutea in the youngest generation, and thus of ova shed at the last oestrus, was in excess of the normal number of foetuses in the litter. Some of the ova must, therefore, commonly miss fertilization, or degenerate shortly after it has taken place.

TABLE XVIII. NUMBER OF CORPORA LUTEA DERIVED FROM THE LAST OESTRUS

No. of corpora lutea in the youngest generation	Occurrences per cent of total	
1	8·4	
2	50·0	
3	12·5	41·6
4	20·7	
5	8·4	

Transference of ova

One pregnant specimen showed that the transference of ova from the ovary of one side to the uterine cornu of the other can occur. One ovary contained four large corpora lutea, all young and of the same age. Further old corpora lutea were present in this ovary. All the corpora lutea in the other ovary were obviously older than the four young ones. The animal was pregnant with two foetuses, one in each cornu. As both were derived from the same ovary, one of them must have been transferred to the cornu of the other side. None of the other specimens gave any additional information on this point.

Gestation

The present series of specimens, of course, throws no light on the period of gestation; and the records in the literature are not consistent. Grimpe (1916) and Schneider (1926) observed several points in the reproduction of the spotted hyaena in animals living in the Zoological Gardens at Leipzig, and their work will be referred to in several sections below. When Grimpe's female was in oestrus he put the male with her for two days, and was thus able to demonstrate a period of gestation of 98 or 99 days. But Schneider gives the average duration as 110 days (109–111). He also gives records from the Dusseldorf Zoological Gardens varying from 97 to 132 days, but points out that the exact dates of pairing were not noted for them. There appears to be some irregularity, at least in captivity, for one of his females gave birth to a litter of two, and eight days later a third young one was born. Again, a young one was born after a gestation of 105 days: on the 111th day the mother died and was found to have another young one in the uterus. Schneider's figure of 110 days, being based upon a number of observations, is probably correct.

Lactation

Grimpe found that the mammary glands of his female, at her first pregnancy, showed a marked swelling a month before parturition, and that milk could be expressed from the nipples about a fortnight later. At her second pregnancy, when she was allowed to nurse her pups, lactation lasted nearly six months. The pups were then removed, but he does not state whether lactation had completely finished. The considerable length of the period of lactation is indicated by some of the specimens in the present series, for although most of them had some fairly young corpora lutea in the ovaries, one in particular had only comparatively old ones.

Copulation

From a consideration of the anatomy of the genitalia of the female spotted hyaena, copulation would appear to be a difficult feat. When in Africa, the writer tried to get information on this matter from some Masai who frequented his camp on the Balbal plains. Care was taken to put no leading questions, but the information obtained appeared to be merely guesswork, though these people, if any, should know. They demonstrated their ideas on the subject with hyaena carcases, and placed the female on her back, with the male on top. This is quite certainly incorrect. In the elephant, in which the vulva is situated in an unusually anterior and forwardly directed position, comparable with that occupied by the termination of the urinogenital canal in the spotted hyaena, copulation takes place in the usual position of quadrupeds (Evans 1910). Further, Grimpe notes, of three male hyaenas confined together, that reciprocal attempts at pairing were not more to be noticed than ordinarily appear to take place between hyaenas of the same sex. If there were anything unusual in the copulation position he would certainly have mentioned it. When, however, he placed a male and female together he did not observe copulation, nor does he describe the attempts at pairing which he notes. He states that on placing them together, "amid loud laughter, which is characteristic of hyaenas, attempts at pairing immediately began", and that both animals erected the penis (he designates the clitoris of the female a penis) in an equally strong manner. When the female was in oestrus, after the birth of her first litter, he placed the pair together again, but did not observe the pairing. He says that "long capering love play began, accompanied by hateful noises, in the course of which the anal glands played a part not to be ignored...in the first phases of this love play the penis of the female showed a full erection, not less than that of the male animal. Later the erection became less strong and must finally have quite ceased, or else the possibility of coitus cannot be understood." His diagram of the erected clitoris, which is presumably based on observation, shows the organ protruded in a downwards direction, with a pronounced curve, bringing its end into a nearly backwardly facing position (fig. 35). Grimpe's surmise that the clitoris becomes flaccid before copulation occurs appears to be upheld by the statements of Neuville (1936 *a*).

Schneider's records are, however, much more definite. In his paper published in 1926, to which the writer's attention was kindly drawn by Dr H. Neuville of Paris, he states that he has many times observed copulation in the spotted hyaena. He reports the noisy preliminary play, and the erection of the clitoris, as does Grimpe. He says that the anal pouch and the terminal part of the rectum are everted, covered with the yellow secretion from the anal glands. At the actual copulation he says that the clitoris is not erect, but that two small pointed ridges appear at the preputial opening of the female. There thus appears to be some tumescence, and the writer identifies the two ridges described by Schneider with the inflated sides of the urinogenital opening, as shown in fig. 6 above. Schneider continues, that the penis of the male when first erected, hangs down in a position similar to that shown for the clitoris by Grimpe (fig. 35): thereafter it assumes a position close to the belly wall so that its curve is reversed. At the tip of the glans a ring-shaped fold surrounds the meatus of the urethra and terminates in a point. The male mounts the female, clasping her lumbar region, in an almost sitting position so that his posterior region nearly touches the ground. The penis now moves to the second position, and, passing between the mammary glands, enters the urinogenital canal of the female between the two pointed ridges. The male then stands up, thereby dragging the urinogenital opening of the female back under the root of the tail. The penis at the same time enters deeper into the urinogenital passage of the female. Towards the end of pairing the male leans heavily on the female, and, taking the weight off his hind legs, hangs from her. Copulation lasts from eight to twelve minutes. As Schneider points out, the behaviour of the male is adapted to the form of the female urinogenital organs.

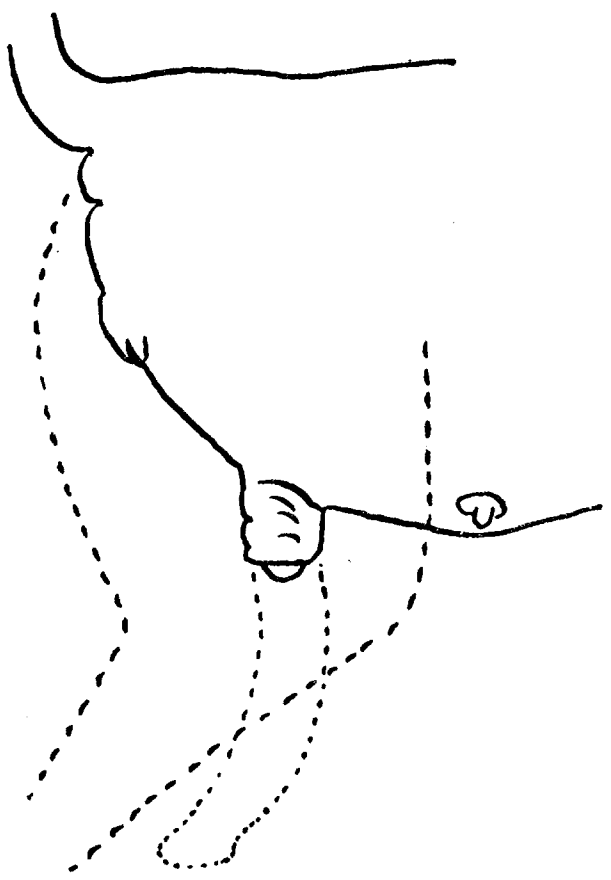
FIG. 35. Erection of the clitoris (after Grimpe).

Grimpe further notes that young hyaenas only a few days old show a capacity for the complete erection of the penis. Capt. C. R. S. Pitman informed the writer that a young spotted hyaena a few months old, that was kept in captivity in Uganda, erected the penis whenever it was approached or petted.

Parturition

Although Grimpe's captive female produced two litters, he was unable to observe the process of parturition. Schneider records that one of the keepers of the Leipzig Zoo was present at a parturition, but that nothing was seen of the clitoris, the young appearing at the greatly enlarged preputial opening. He points out that they must traverse the curved path of the urinogenital canal, for there is no retraction of the urinogenital opening in a backwards direction. It is surprising, considering the narrow passage through which birth takes place, that the young of the spotted hyaena are born in such an advanced state. They are large in size, have the eyes open, have erupted incisor and canine teeth, and can walk, whereas, according to Grimpe, those of the striped hyaena, in which there is nothing unusual about the female genitalia, are smaller, blind and completely toothless and helpless. At parturition there is evidently great stretching of the loose tissue of the ventral surface of the clitoris. The process is not always accomplished without laceration of the urinogenital orifice, as is shown by the presence of scars and tags in many of the specimens of the present series.

Breeding season

There is evidently no annual breeding season for the spotted hyaena, at least on the Masai steppe of Tanganyika, where the present series of specimens was collected. All states of the reproductive cycle were obtained in the course of a few weeks—animals in anoestrus, pro-oestrus, oestrus, all stages of pregnancy, and lactation. As gestation lasts over three months, and lactation about six, there is an interval of at least ten months between the beginning of consecutive pregnancies, and there can thus be no season of the year in which the majority start. It has also been shown above that the males are potent at all times of the year. Schneider (1926) records pairing during many different months in captive animals, and points out that no part of the year forms a definite breeding season for them.

Oestrous cycle, and age

On reaching sexual maturity the first oestrus occurs, which may result in pregnancy. This is exemplified by one lactating specimen which had only one corpus luteum in the ovaries, and must have become pregnant at its first ovulation. Another lactating specimen had one corpus luteum in each ovary, both apparently of the same age, and had thus become pregnant at the first two simultaneous ovulations of the first oestrous cycle. Another lactating animal, and a parous anoestrous one, each had three corpora lutea, all apparently of the same age. These animals had thus become pregnant at the first oestrus, which had three ovulations, at least one of the ova from which had probably perished. The ovaries of an anoestrous parous animal contained three corpora lutea, two young and apparently contemporary, and one much older. This animal had probably become pregnant at the first ovulation of the first oestrus, and subsequently with the two ovulations of the second oestrus.

Grimpe's observations on his captive animals are here of interest. On the birth of the first litter the pups were removed and nursed by a bitch, as it was feared that the mother might not rear them. Three weeks after the birth oestrus occurred, "which from careful management of the mother was soon over". Oestrus then recurred after fourteen days, when the male was admitted and a second pregnancy started. It would appear from this that oestrus occurs about a fortnight after the end of lactation, removal of the pups, of course, leading to the cessation of lactation. Grimpe, unfortunately, does not state the symptoms of oestrus observed: probably it was recognized by the behaviour of the animal, rather than by any local signs in the genitalia. Neither does he say anything of the onset of oestrus after the end of natural lactation, when he allowed the mother to nurse her second litter. If oestrus recurred after fourteen days there can have been no lengthy pseudopregnancy, as is found in the bitch, resulting from the first post-lactation oestrus, and there would appear to be a fourteen-day dioestrous cycle. This may be so, but the present series of specimens does not lend support to the view that oestrus occurs so soon as a fortnight after the end of lactation. Of the adult females, 43·5 % were in anoestrus, and this proportion is higher than would be expected if the post-lactation anoestrus were of such short duration. On the other hand, Schneider records that a specimen in the Dusseldorf gardens came into oestrus twenty days after parturition, the young having been removed at birth.

In the ovaries of all the pregnant animals, except those in the earliest stages, there were no follicles visible to the naked eye. In those of some of the lactating animals the condition was similar, but in others follicles were visible, those in some specimens being of quite large size, up to 5 mm. in diameter. The latter point towards the onset of post-lactation oestrus at no great time after the weaning of the pups, but the ovaries of anoestrous animals present no greater degree of activity. In 80 % of these, visible follicles were present, but none were greater than 4 mm. in diameter. It would appear, then, that the onset of post-lactation oestrus is earlier in some animals than in others. It may occur as soon as three weeks after the end of lactation, as in Grimpe's specimen. On the other hand, judging from the ovaries of many of the lactating and anoestrous animals of this series, it may be later in appearing, with an interval that the writer would suggest as anything up to two months. The later stages of follicular ripening are, no doubt, rapid, but the large number of anoestrous ovaries, with no follicles as much as 5 mm. in diameter, lend support to the view proposed.

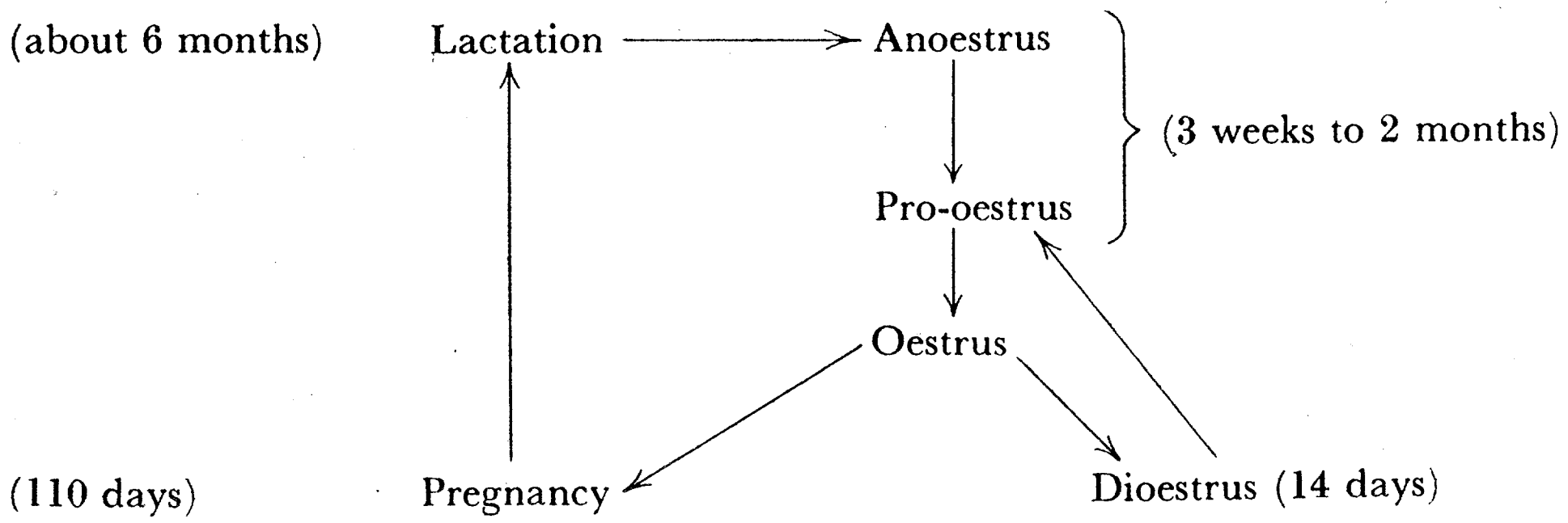

FIG. 36. The oestrous cycle.

The presence of the large persistent corpora lutea, which presumably protect the genitalia from the action of oestrone by their secretion of progestin, would suggest that the spotted hyaena is monoestrous, as the dog; but, in the light of Grimpe's and Schneider's definite records, it is impossible to come to any other conclusion than that it is polyoestrous, with a dioestrous cycle of about fourteen days. It would appear unlikely, however, that the dioestrous cycle ever occurs more than very rarely in nature, because the males, which in the present series outnumber the females, are potent at all times of the year. It is to be presumed that any female coming into oestrus quickly becomes pregnant. This is confirmed by those specimens of the present series that have undoubtedly become pregnant at the first ovulation or ovulations of the first oestrus.

The oestrous cycle may, then, be summarized diagrammatically as in fig. 36, the whole cycle occupying about eleven to twelve months. Each recognizable generation of corpora lutea will thus represent about a year of age. Not more than three generations have been separable in any one animal, because the generations become indistinguishable among the older corpora lutea. Table XIX shows the correlation between the occurrences of different numbers of generations of corpora lutea and the total number of corpora lutea in the ovaries. An anoestrous animal, which has completed the cycle represented by the youngest corpora lutea, having three recognizable generations and an excess of older corpora lutea, showing that it has completed at least four cycles, will thus be at least four years old from the date of reaching sexual maturity. The growth of the hyaena is slow: lactation lasts six months, and at the age of nine months the pups are, according to Grimpe, only half the size of the adults. Sexual maturity in the female is, therefore, not likely to be reached before the age of about two years. An anoestrous animal such as that just mentioned—and there are several such examples in the present series—would therefore be at least six years old at the time of death. Some of the aged individuals, with much-worn teeth and many corpora lutea, are thus likely to be about ten years old. This age probably represents the approximate life-span of wild hyaenas, though in captivity specimens have been known greatly to exceed this age.

TABLE XIX. NUMBER OF AGES OF CORPORA LUTEA

No. of corpora lutea in ovaries	No. of recognizable ages of corpora lutea		
	(1)	(2)	(3)
1	1	—	—
2	1	—	—
3	2	1	—
4	1	3	1
5	—	—	2
6	—	1	1
7	—	1	1
8	—	—	2
9	—	1	1
10	—	—	1
11	—	1	—
12	—	—	—
13	—	—	1

Possible androgenic activity of the ovary

Since the discovery by Parkes (1937) of an androgenic activity in ovarian extracts, which is not shown by purified ovarian hormones and is probably due to substances of the androsterone-testosterone group, a possible explanation of the peculiar genital anatomy of the female spotted hyaena is presented. Lipschütz (1918) and Sand (1918) have shown that the clitoris of the guinea-pig and of the rat respectively can be transformed into a penis-like organ, under the influence of testicular grafts, and Steinach and Kun (1931) have produced a similar condition by exposing the ovaries to X-rays or injecting gonadotropic extracts. Further, Lipschütz (1933) has experimentally produced a penis-like organ from the clitoris by partial castration, an operation leaving only a minute amount of ovarian tissue in the body. He also points out that occasionally a penis-like organ is developed spontaneously in otherwise normal female guinea-pigs, which show no histological abnormalities in their ovaries. It therefore seems possible, if not probable, that in the hyaena we have an animal in which androgenic substances are developed in the ovary to an unusual extent, so that the peculiar organization, so closely resembling the male externally, is produced. Some support is given to this view by the great dearth of follicles in the ovary, mentioned above. If the oestrogenic hormones are produced largely in the follicles, there may well be a shortage of them so that their action is overcome by androgenic substances produced in the stroma of the ovary.

It is of interest to note that Steinach and Kun (1931) emphasize the extensive luteinization of the ovary in their successful experiments, when the great degree of luteinization of the hyaena ovary is remembered. The luteinization cannot, of course, have any effect in producing the male facies of the female in the first instance, because that is found during early development when the ovaries contain no luteal tissue. But there may be some correlation with the retention of large, and apparently functional, corpora lutea in the ovaries for long periods, after sexual maturity is reached. The occurrence of luteal atresia in prepubertal animals, as recorded above, is also of significance. It is of interest to note that Deanesly (1938) finds that the androgenic activity of ovarian grafts "seems to be essentially associated with luteinization of the theca interna of the follicles of the grafts". This, and the other experimental work quoted above, strongly support the suggestion that the condition found in the spotted hyaena is due to androgenic activity of the ovary.

Further, the striking resemblance of the condition found in the normal female spotted hyaena to the pathological conditions found in adrenal virilism in the human subject should be noted (cf. Young 1937).

It is unfortunate that the hyaena is not a convenient laboratory animal, for experimental work on this aspect of its physiology would be likely to be of considerable interest.

ACKNOWLEDGEMENTS

The writer wishes to express his thanks to the Government Grants Committee of the Royal Society, who in part defrayed the expenses of this research, and who made a further grant to provide technical assistance in the preparation of material for histological examination. He is also indebted to the authorities of the British Museum (Natural History) for the loan of collecting tanks and for providing preservatives; to the Colston Research Society of the University of Bristol; and to many friends and correspondents who have assisted him in his work. He takes pleasure in thanking Professor J. Stanley Gardiner, F.R.S., Martin A. C. Hinton, Esq., F.R.S., and Dr A. S. Parkes, F.R.S., for their interest in this work, and valuable criticism of results. In Africa, especial thanks are due to S. P. Teare, Esq., Game Warden of Tanganyika Territory, Captain C. R. S. Pitman, Game Warden of Uganda, Mr Ben Fourie, of Oldeani, Tanganyika Territory, and numerous Government officials and private residents who, by their kind hospitality and active assistance on many occasions, enabled the objects of the expedition to be attained not only with success but also with pleasure. Nor must mention be forgotten of those Africans whose faithful service was essential for the successful accomplishment of the field work, of which the meaning was beyond their comprehension. The writer is also greatly indebted to his assistant, Miss M. L. Mawson, for her skill and care in preparing many thousands of sections for microscopic examination.

SUMMARY

This paper records the information relating to reproduction in the spotted hyaena gathered from an examination of 103 specimens collected in Tanganyika Territory.

The sex ratio in this random sample was 61·1 % of males.

The anatomy of the external genitalia is described. The female is peculiar in that externally it closely resembles the male. There is a peniform clitoris, perforated by the urinogenital canal, similar in form and position to the penis of the male. Scrotal pouches closely simulating those of the male occur in a parallel position. The perineum and anal glands are superficially similar to those of the male.

The clitoris of the female resembles the penis of the male most closely in the prepubertal animal, where the urinogenital canal opens at the tip of the glans in a meatus exactly like that of the male. At sexual maturity the meatus increases in size. It spreads down the under surface of the glans, splitting the fraenum preputii so that a larger orifice is formed, through which copulation and parturition can take place.

The male and the non-parous female are indistinguishable externally: the larger size of the nipples in the parous female is the sole character by which the sexes can be readily separated, without dissection.

The penis consists of two corpora cavernosa, and a corpus spongiosum surrounding the urethra. The secondary sexual organs consist of a pair of large Cowper's glands, and a very small prostate confined to the dorsal surface of the urethra. There are no vesiculae seminales.

The clitoris likewise consists of two corpora cavernosa and a corpus spongiosum. The latter lies dorsal to, and does not surround, the urinogenital canal except at its distal end, where in the parous animal it surrounds the meatus. Proximal to the base of the clitoris the urinogenital canal is about 4 cm. in length: it is formed by the junction of the vagina and urethra. The vagina is shut off from it by a hymenial fold placed just proximal to the junction of the urethra. The urinogenital canal receives the ducts of a pair of large Bartholin's glands.

The vagina is separated from the body of the uterus by a feebly developed os. The uterus consists of two cornua and a short body, which is partly divided internally by a median longitudinal septum. The ovaries lie in a capsule which is in communication with the abdominal cavity.

An examination of the histological structure of the testis and epididymis when considered in relation to the amount of tooth-wear, condition of the cranial sutures, and total length of head and body, shows that sexual activity in the male is reached before physical maturity. Closure of the basilar suture is associated with the attainment of puberty, whereas closure of the frontoparietal suture does not take place till later. Sexual maturity is reached at a head-and-body length of about 110 cm. and physical maturity at about 120 cm.

The weight of the testes increases with increasing body size until physical maturity is reached, but after reaching puberty their weight bears little relation to their state of activity.

A fairly close correlation between the weight of the testes and that of the epididymides and vasa deferentia was found, but the relationship of the weight of Cowper's and the anal glands was not so close.

The prostate is very variable in the amount of its development. It is frequently very small, but may reach a size of approximately a cubic centimetre. No correlation could be found between the degree of its development, or its histological activity, and the age, size, or state of sexual activity of the animal, after the attainment of puberty.

The histology of the organs of the genitalia is described in detail.

There is no seasonal sexual cycle in the male. All physically mature animals showed some degree of sexual activity, and once puberty is reached the animals are capable of breeding at any time of the year.

The female is larger than the male, and reaches puberty and physical maturity at a head-and-body length of about 5 cm. more than the respective lengths in the male. The onset of puberty occurs at a later age than in the other sex.

The ovary of the parous animal is characterized by a high degree of luteinization, and it is probable that the degenerate remains of the older corpora lutea are never lost. The corpora lutea remain functional throughout pregnancy and persist through lactation: their rate of regression is very slow. The ovaries of the oldest animals show the greatest numbers of corpora lutea.

The ovaries are further characterized by the small number of follicles, both microscopic and visible to the naked eye, present in them. The growth of the oocyte and follicle is divisible into three stages, the first in which the oocyte is surrounded by a single layer of follicle cells, the second in which the number of layers of follicle cells increases, and the third in which the antrum is developed.

Follicular atresia is very common, both in large and small follicles. It usually starts with a degeneration of the follicular epithelium, and is followed by an invasion of the follicle by connective tissue cells. A more rarely observed type of atresia leads to the formation of cells resembling luteal cells scattered among the invading connective tissue.

Young corpora lutea contain a central clot of blood, and consist of large luteal cells of irregularly polyhedral shape. Towards the end of pregnancy many of the cells become shrunken, and there is considerable proliferation of the connective tissue cells between them. During lactation and after weaning the cells continue to decrease in size, but as the corpora lutea become older the rate of regression appears to decrease, so that even old ones show some signs of activity. They appear never completely to disappear throughout the life of the animal.

The uterus consists of the usual muscular and mucous layers. After post-partum involution and during anoestrus the mucosa is thin and smooth, and the glands are few and small. At pro-oestrus the mucosa is greatly thickened, its surface is thrown into ridges, and the glands are greatly increased in number. At oestrus the growth changes are carried further, and the glands reach their maximum in number and size, completely filling the mucosa and penetrating to its base. Examination of the sterile cornu during pregnancy reveals the conditions equivalent to pseudopregnancy. The glands are very much enlarged and are separated from each other only by thin strands of connective tissue. At the level of the muscularis mucosae they suddenly become narrow, and follow a short course in this layer. In later stages the glands degenerate, and the mucosa, with the exception of the muscularis layer, is shed. When this happens the epithelium of the bases of the glands is retained. By its proliferation it forms the epithelium covering the new mucosa which arises external to the muscularis. The narrow parts of the glands, penetrating the muscularis, are retained and become the glands of the new mucosa.

The vagina in anoestrus is lined by an epithelium of cubical and polyhedral cells, with an outer layer of thin stratified cells. At pro-oestrus the epithelium is greatly increased in thickness; the cells are enlarged and many of them undergo a process of mucification. At oestrus the epithelium is further thickened and consists of a deeper part of large polyhedral cells, and a superficial part of lenticular and cornified cells, the outer layers of which are desquamated into the lumen of the organ.

Bartholin's glands are compound tubo-racemose glands lined by a secretory epithelium. They start into activity at pro-oestrus and reach their maximum during oestrus. Activity continues during pregnancy, but by the end of lactation the involution of the gland is complete.

The histology of the anal and mammary glands is described.

There is some evidence that ovulation occurs commonly from the ovary of one side only at each oestrus.

The number of foetuses in the litter is usually one or two, but the number of ova shed from the ovaries at each oestrus is usually in excess of this. The superfluous ova must either miss fertilization or fail to become implanted early in development.

Transference of the ova from the ovary of one side to the cornu of the other sometimes occurs.

Gestation lasts about 110 days, but shows some irregularity at least in captive animals, and lactation about six months.

Both copulation and parturition take place through the clitoris of the female. The clitoris is capable of erection equal to that of the penis. At parturition great stretching of its ventral wall must take place.

There is no annual breeding season for the female spotted hyaena in Tanganyika Territory: all stages of sexual activity were found at the same time. The complete sexual cycle lasts nearly twelve months; pregnancy and lactation lasting together about nine and a half months, and anoestrus three weeks to two months.

In the absence of fertilization a dioestrous cycle of about fourteen days' duration occurs. The animal is thus polyoestrous.

Many of the specimens in the present series are at least six years old, and probably older. The natural length of life in the wild animal is probably about ten years.

The view is brought forward that the peculiar male facies of the female may be produced by an excess of androgenic substances, accompanied probably by a deficiency of oestrogenic ones, derived from the ovary. The resemblance between the conditions found in the normal female and those found elsewhere in adrenal virilism is noted.

REFERENCES

Aelian *Natura animalium*, lib. I, cap. XXV.
Aristotle *Historia animalium*, lib. VI, cap. XXX.
Chapman, H. C. 1888 *Proc. Acad. Nat. Sci. Philad.* p. 189.
Deanesly, R. 1938 *J. Physiol.* **92**, 34*P*.
— 1938 *Proc. Roy. Soc.* B, **126**, 122.
Evans, G. H. 1910 *Elephants and their diseases.* Rangoon.
Grimpe, G. 1916 *Zool. Anz.* **48**, 49.
— 1923 *Ver. dtsch. Zool. Ges.* p. 77.
Hemmingway, E. 1936 *Green hills of Africa.* London.
Lipschütz, A. 1918 *Arch. EntwMech. Org.* **44**, 196.
— 1933 *C.R. Soc. Biol., Paris*, **112**, 1272.
Marshall, F. H. A. 1922 *The physiology of reproduction.* London.
Neuville, H. 1935 *Arch. Mus. Hist. nat. Paris*, p. 225.
— 1936 *a* *Bull. Mus. Hist. nat. Paris*, **8**, 54.
— 1936 *b* *Rev. Hist. nat. Appl.* (*a*), **1**, 49.
Parkes, A. S. 1926 *Biol. Rev.* **2**, 1.
— 1937 *Nature, Lond.*, **139**, 965.
Pliny *Historia naturalis*, lib. VIII, cap. XXX.
Sand, K. 1918 *Pflüg. Arch. ges. Physiol.* **173**, 1.
Schmotzer, B. and Zimmerman, A. 1922 *Anat. Anz.* **55**, 257.
Schneider, K. M. 1926 *Peltztierzucht*, **2**, 1.
Steinach, E. and Kun, H. 1931 *Pflüg. Arch. ges. Physiol.* **227**, 265.
Stilling, H. 1885 *Virchows Arch.* **100**, 170.
Watson, M. 1877 *Proc. Zool. Soc. Lond.* p. 369.
— 1878 *Proc. Zool. Soc. Lond.* p. 416.
— 1879 *Proc. Zool. Soc. Lond.* p. 79.
— 1881 *Proc. Zool. Soc. Lond.* p. 516.
Young, H. H. 1937 *Genital abnormalities, hermaphroditism and related diseases.* London.

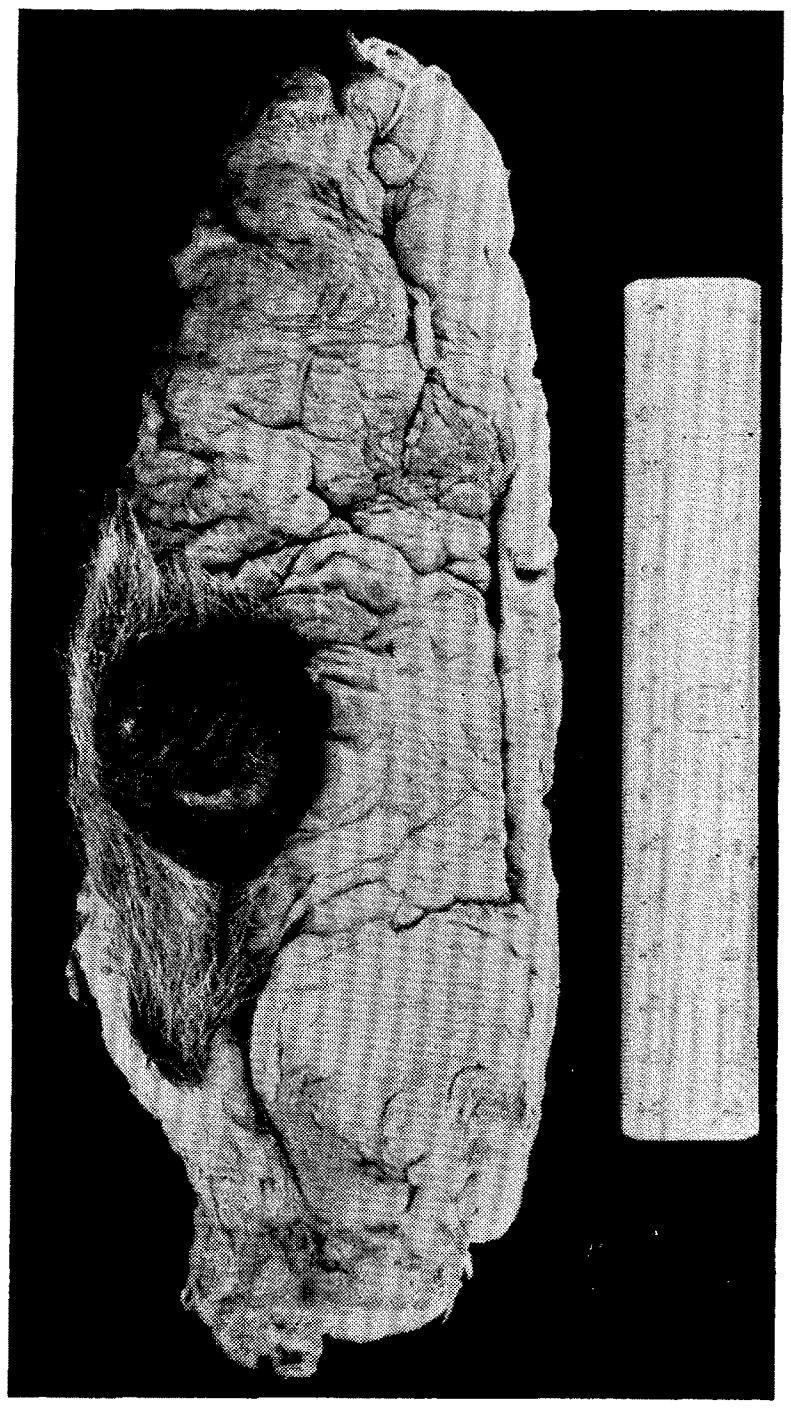

FIG. 37. Mammary gland during lactation (after fixation).

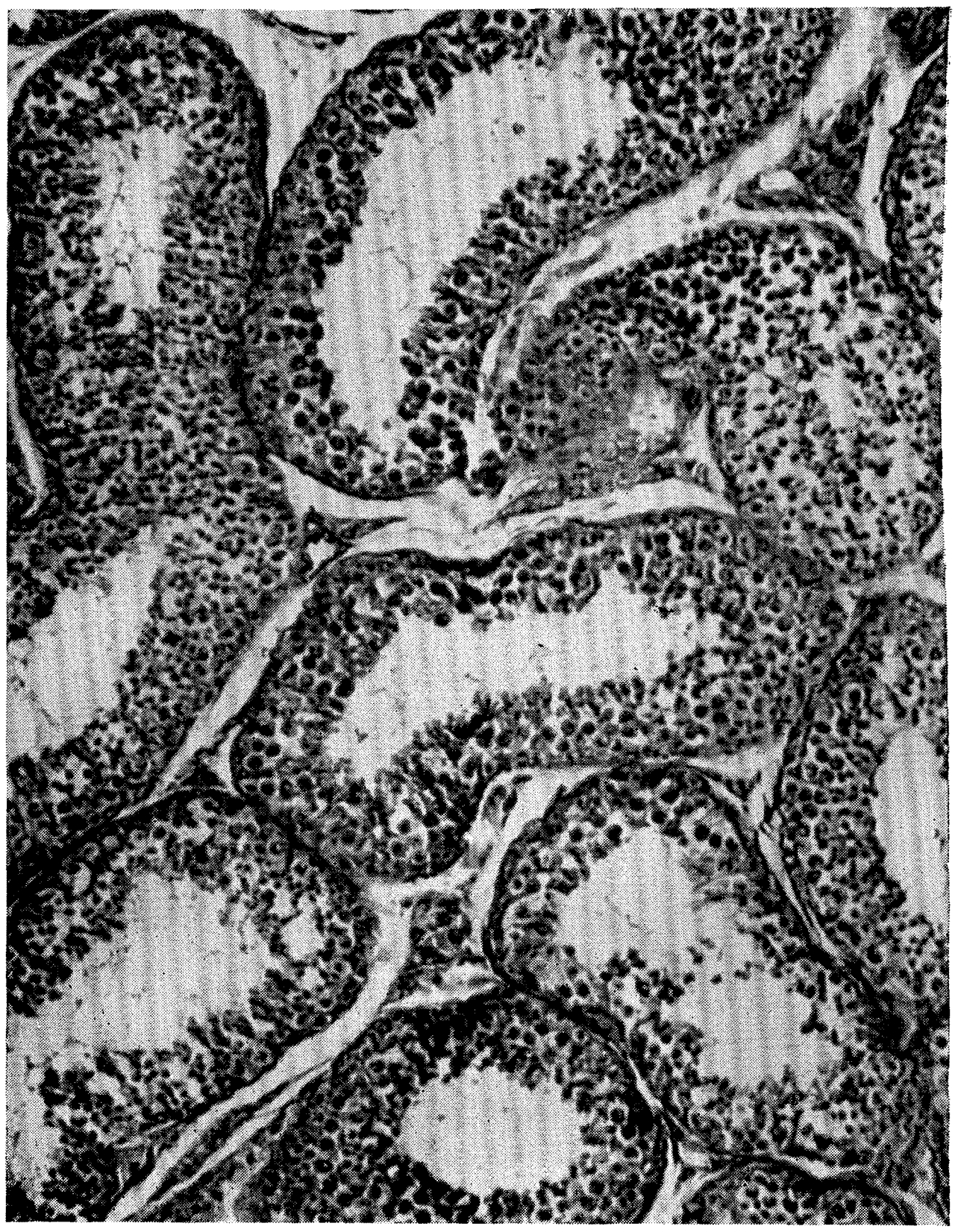

FIG. 38. Section of testis in inactive state. × 130.

FIG. 39. Section of testis in full activity. × 130.

FIG. 40. Section of testis in intermediate activity. × 130.

Fig. 41. Section of epididymis in inactive state. × 130.

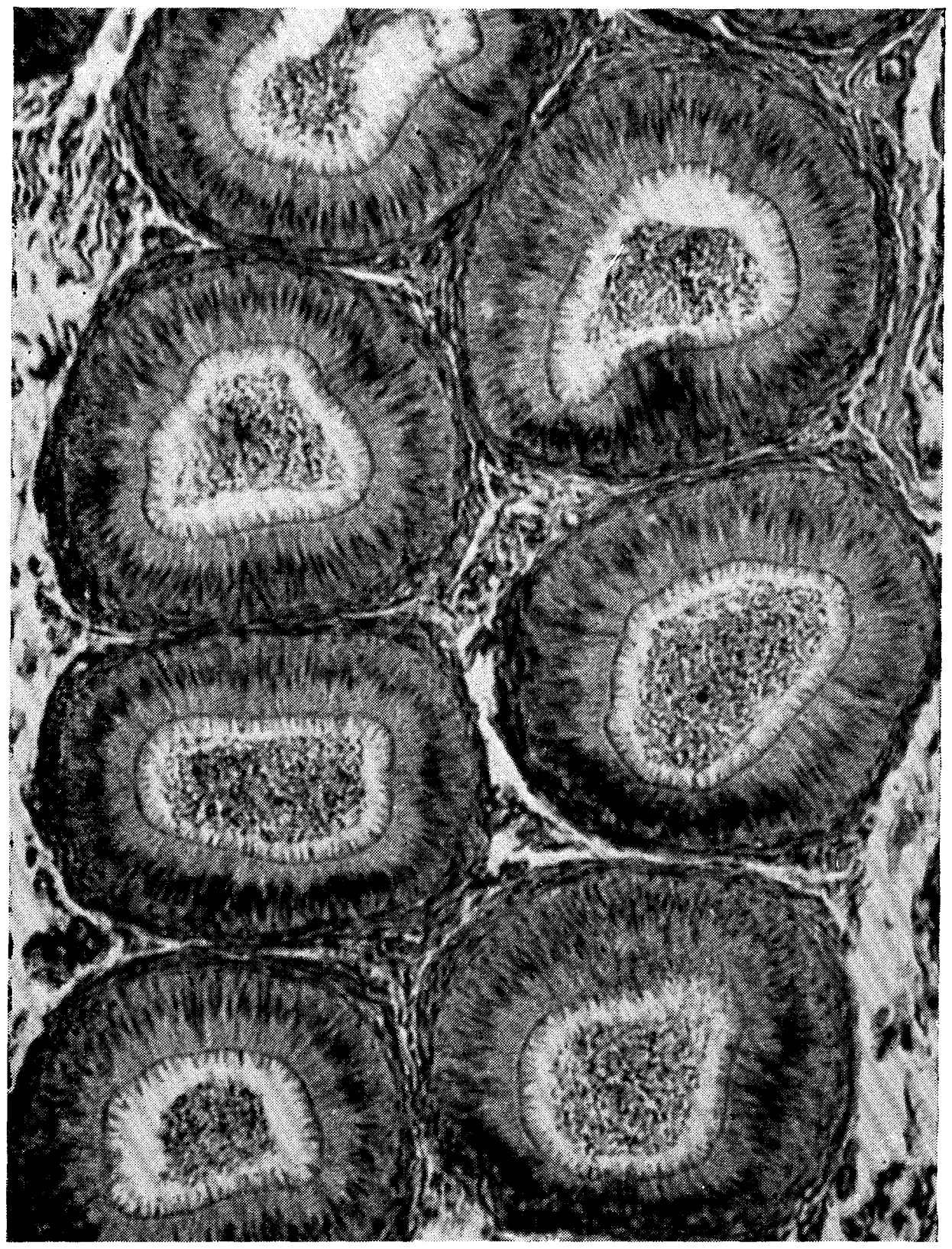

Fig. 42. Section of epididymis in full activity; tubules filled with sperm. × 130.

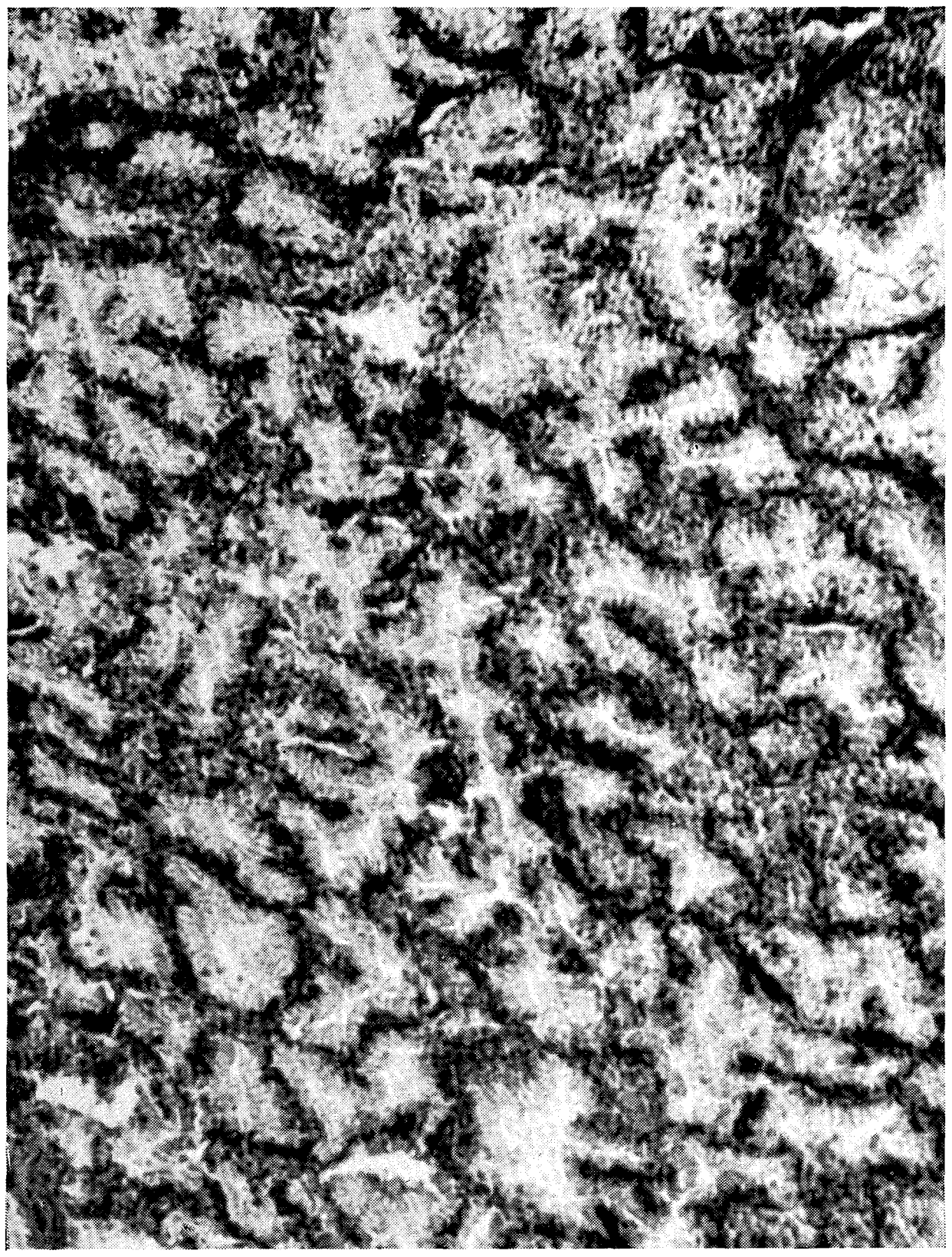

Fig. 43. Section of Cowper's gland, from a prepubertal animal. × 130.

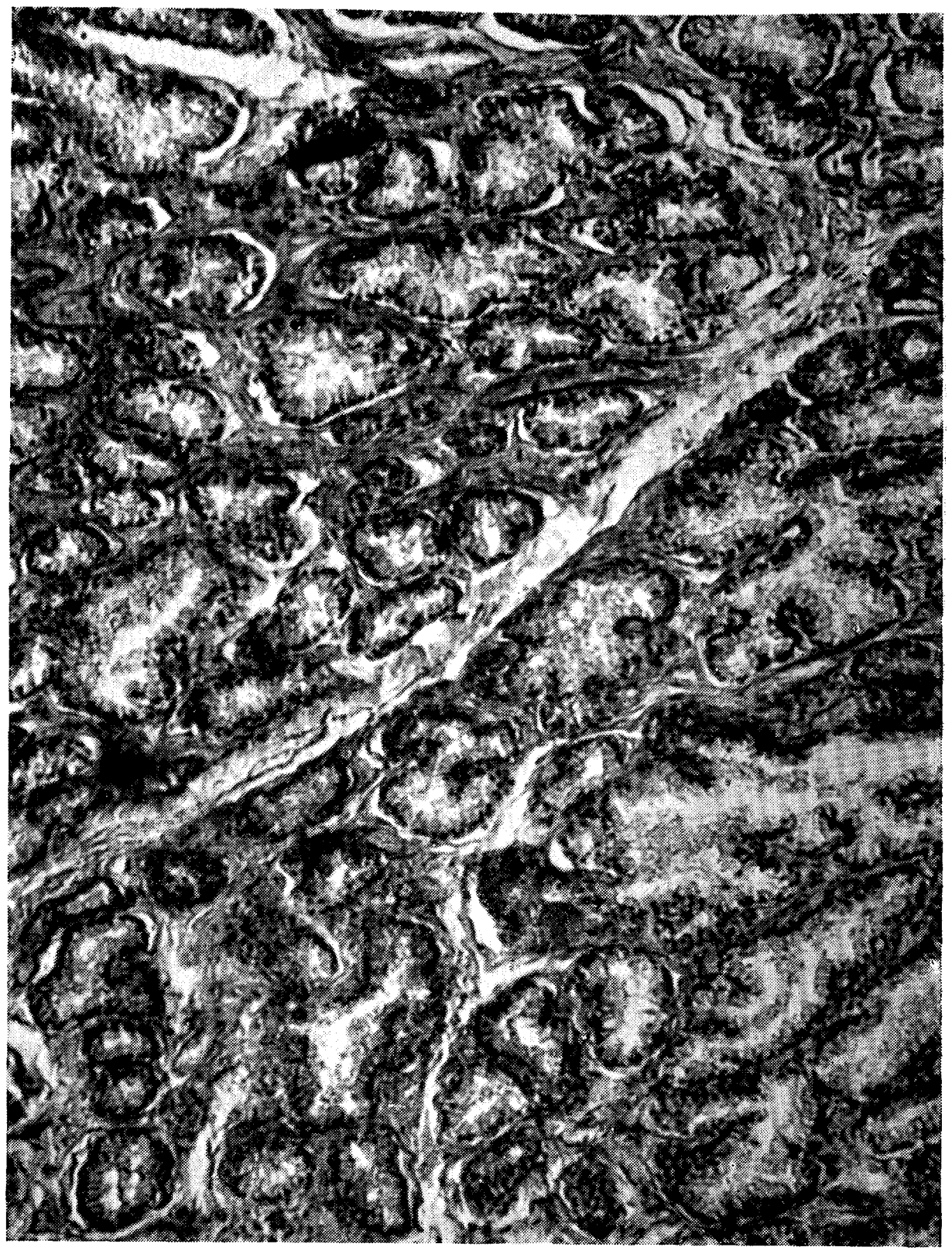

Fig. 44. Section of Cowper's gland showing small acini separated by wide bands of connective tissue. × 130.

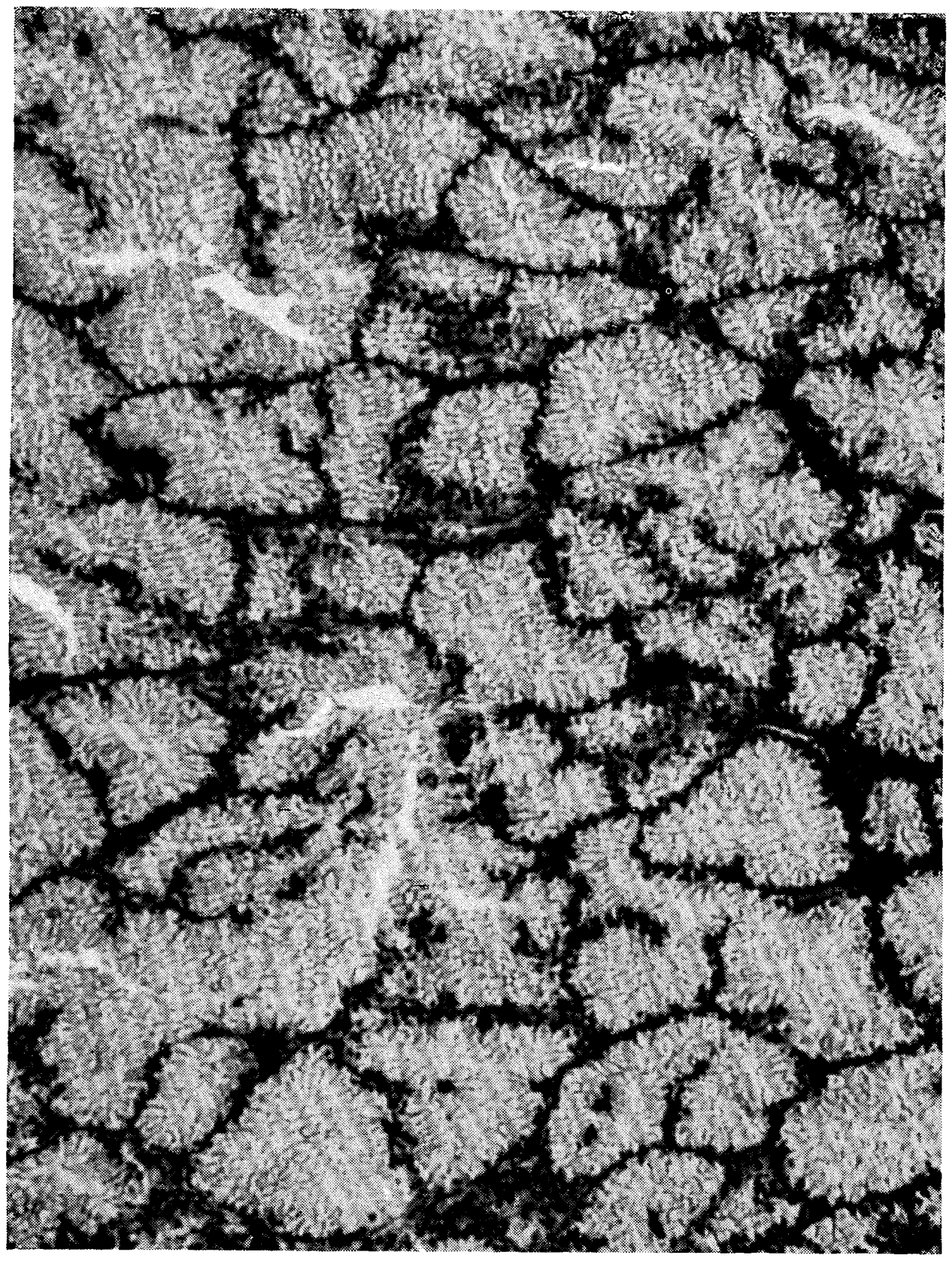

Fig. 45. Section of Cowper's gland showing closely packed acini filled with large cells. × 130.

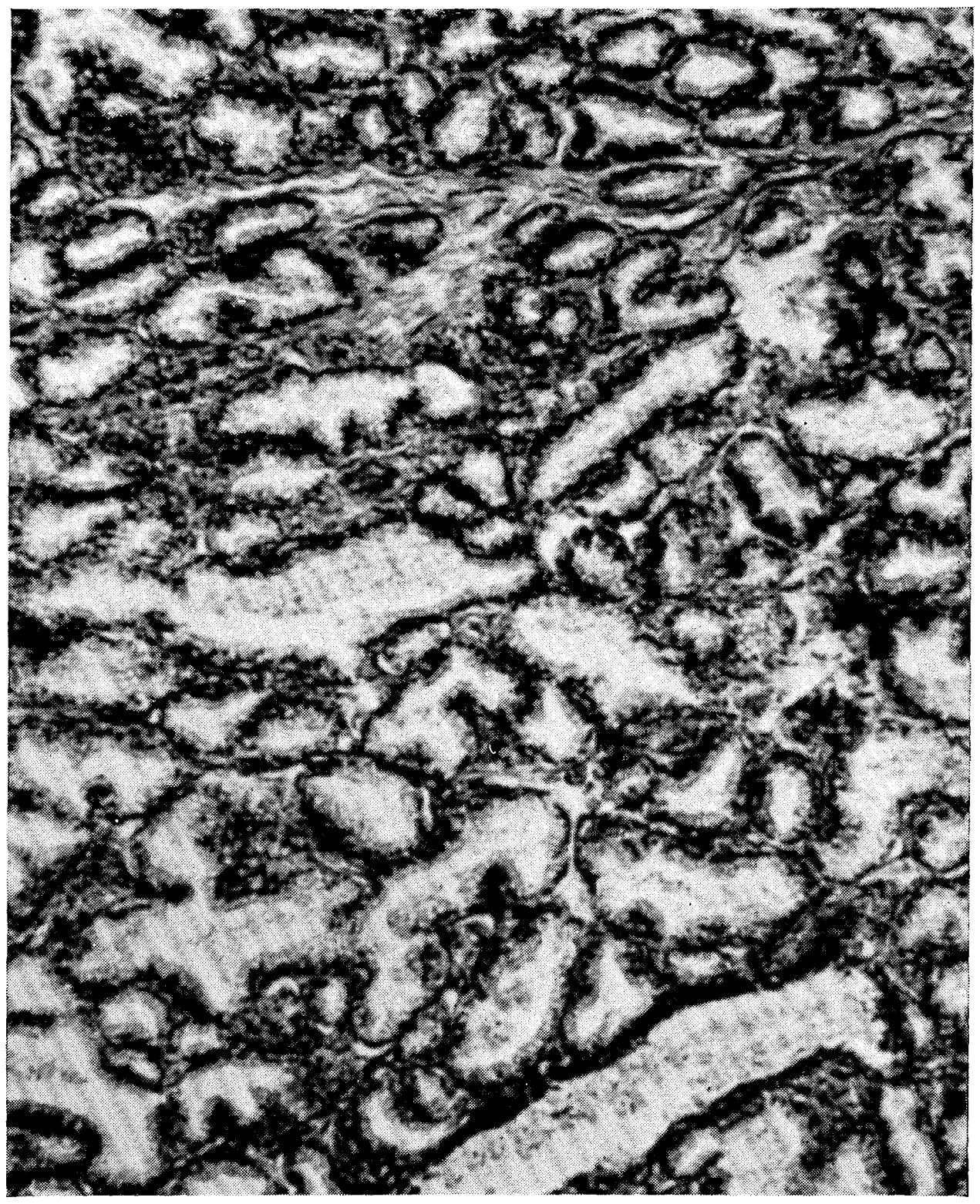

Fig. 46. Section of Cowper's gland: the commonest state found in the sexually mature animal: all the acini with lumina. × 130.

Fig. 47. Section of a small prostate. × 130.

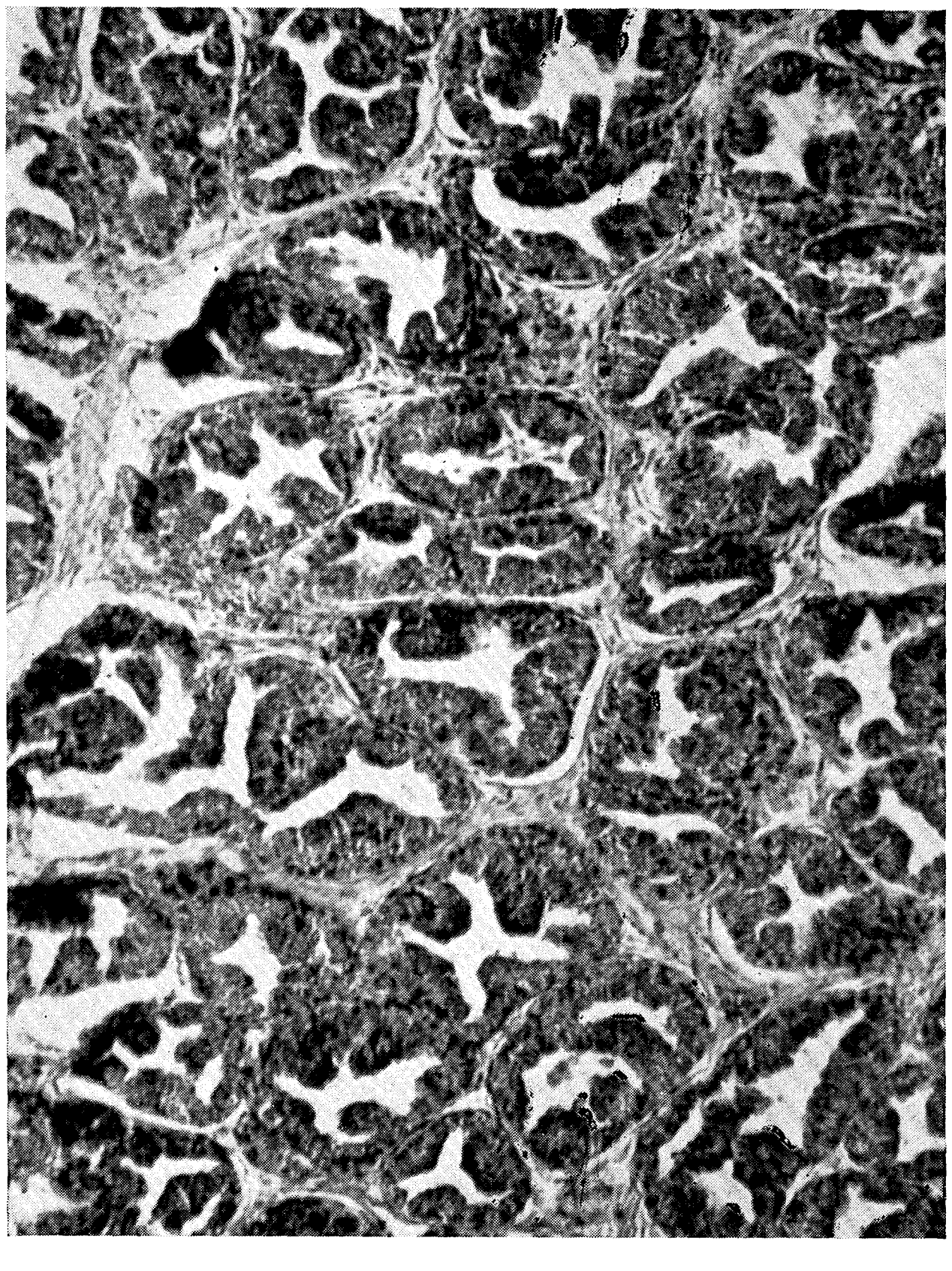

Fig. 48. Section of prostate in highest state of activity. × 130.

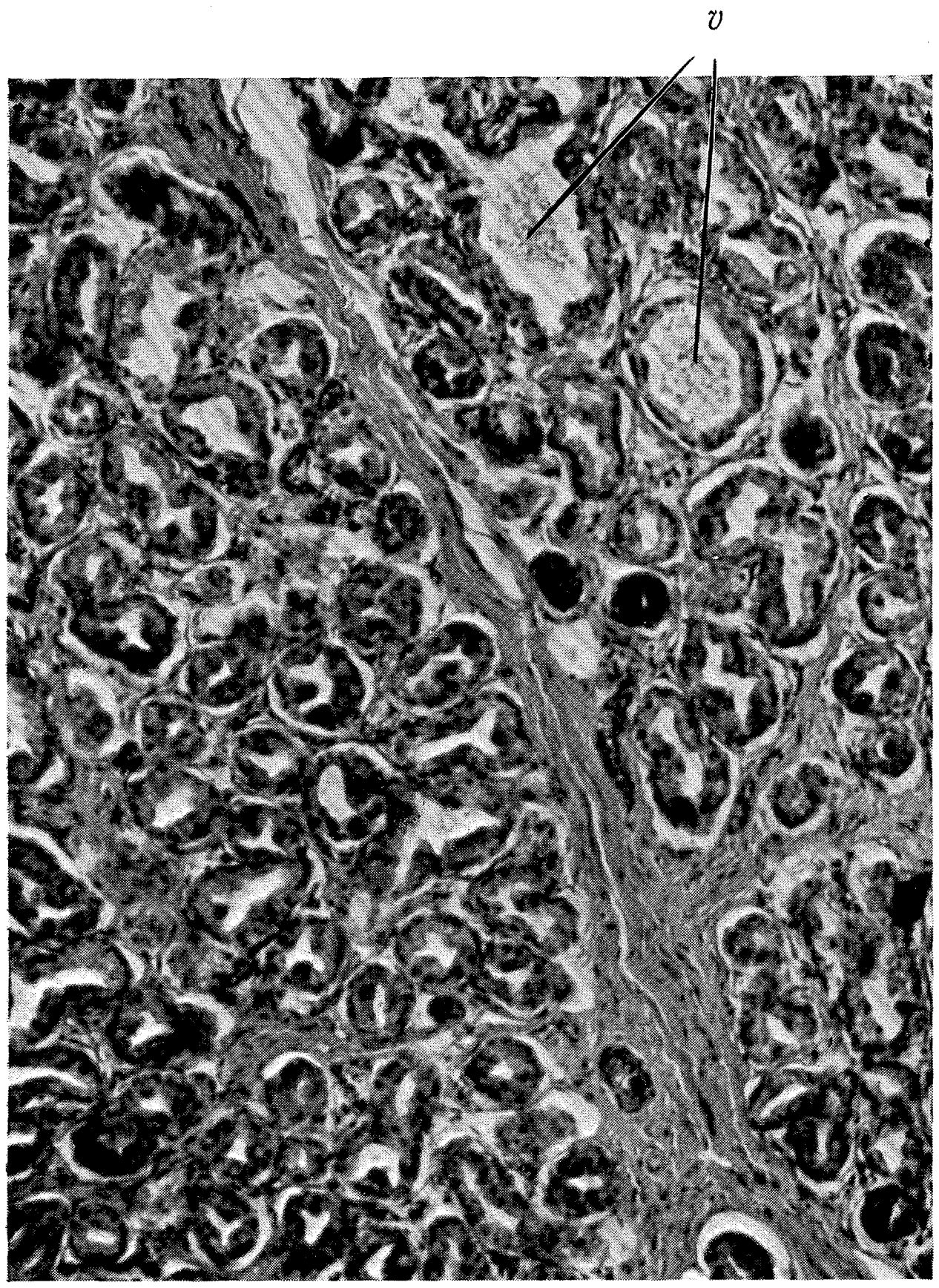

FIG. 49. Section of prostate showing increased vascularity. Vessels, *v*. × 130.

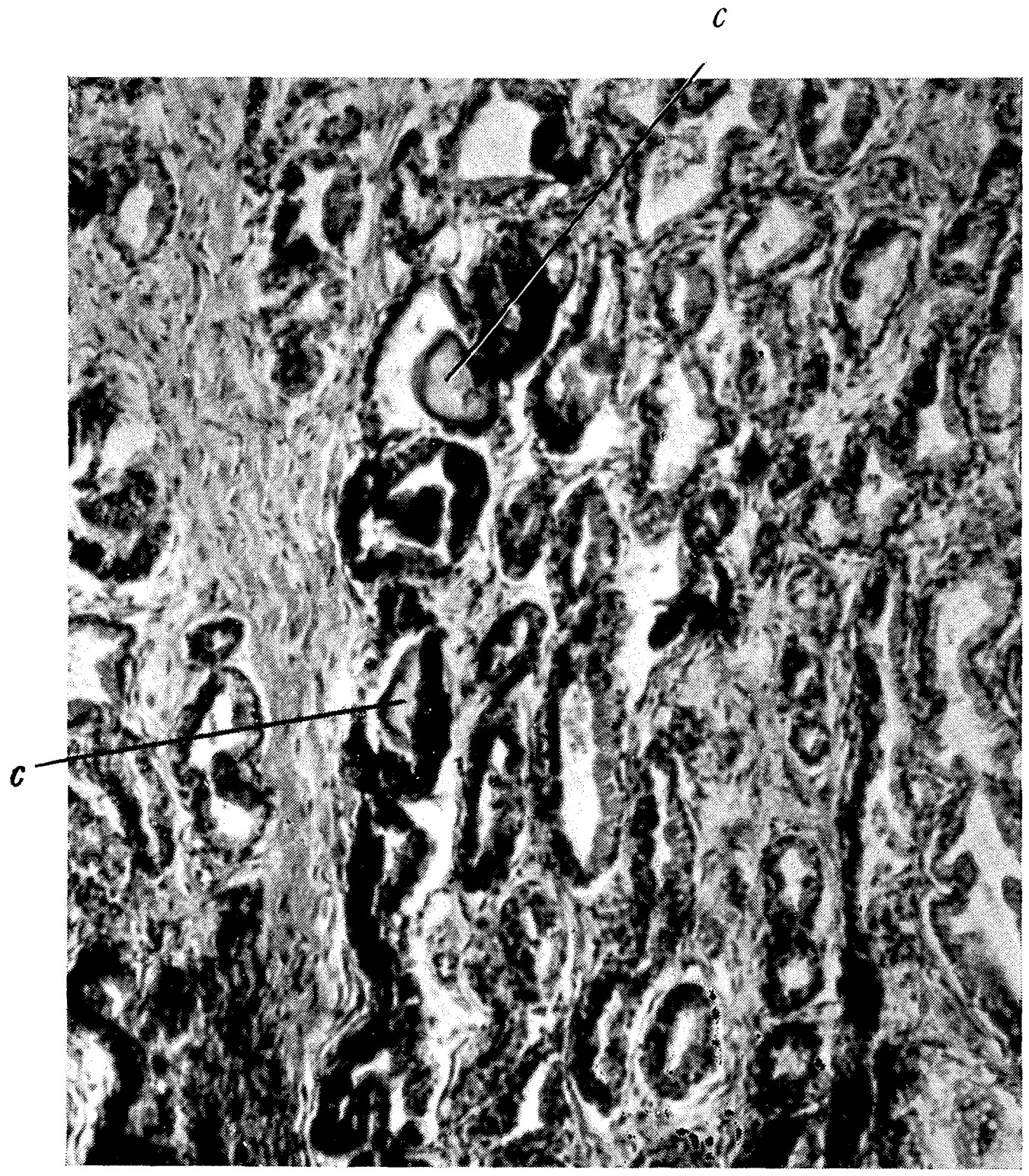

FIG. 50. Section of prostate showing concretions, *c*. × 130.

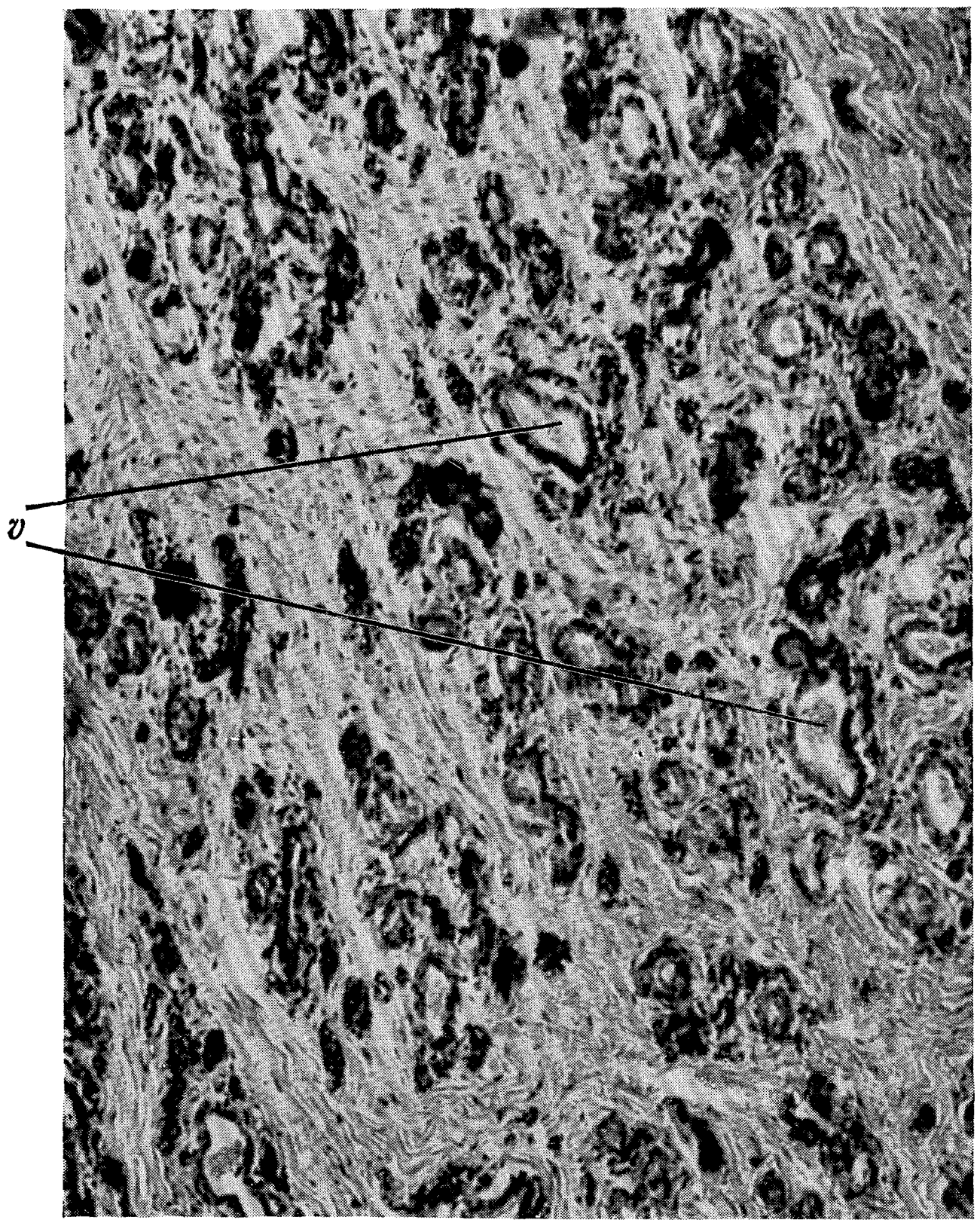

FIG. 51. Section of prostate showing increased vascularity. Vessels, *v*. × 130.

FIG. 52. Section of anal gland. The commencement of a duct, showing cells passing from the acini into the duct, and degenerating as they travel down it. × 130.

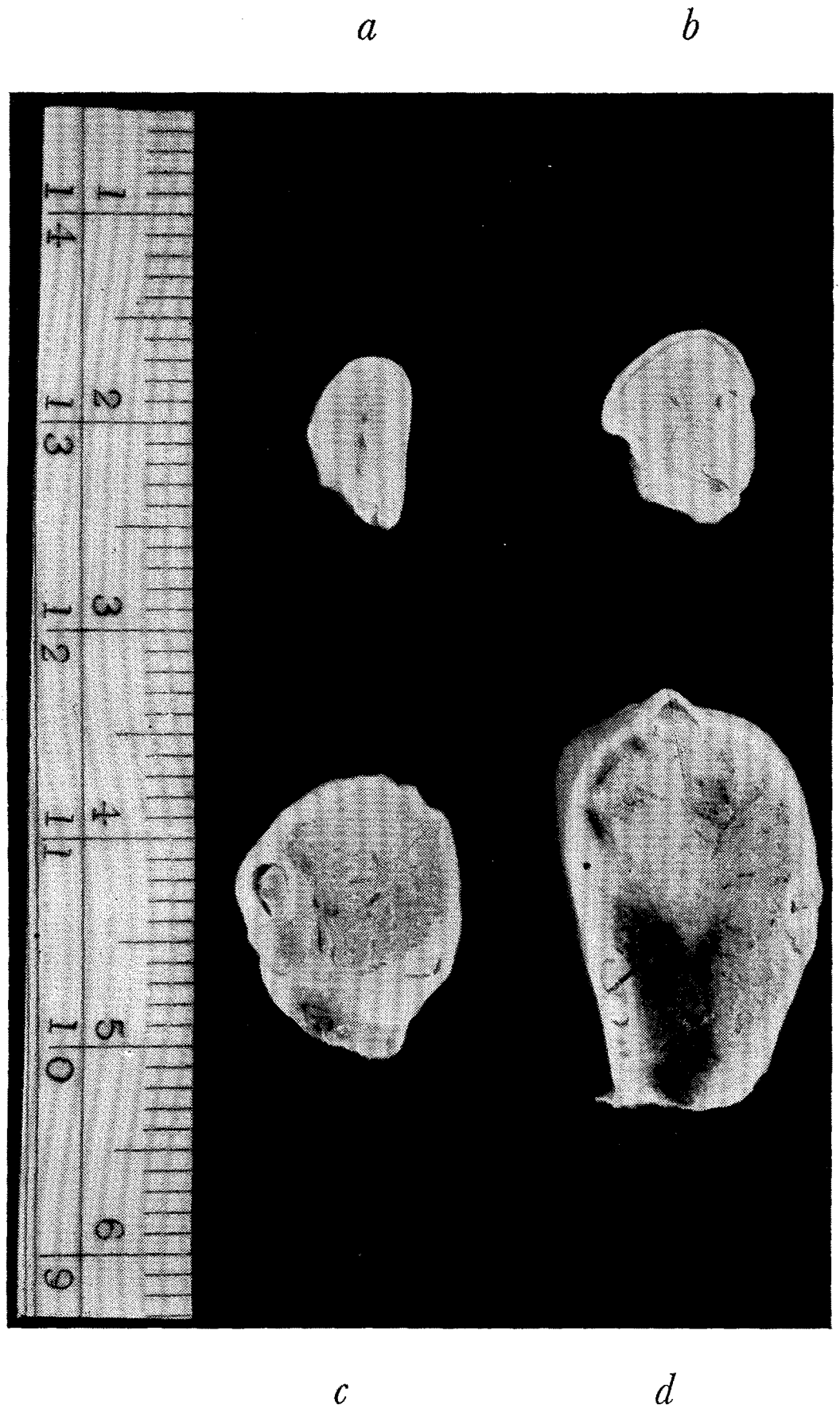

Fig. 53. Sections of ovary. *a*, prepubertal group A, no visible follicles. *b*, prepubertal group B, some visible follicles. *c*, adult in anoestrus: one large corpus luteum and two visible follicles. *d*, adult, pregnant. Two young corpora lutea (top and right) and one old one (bottom, dark in colour). Several visible follicles. Scale of cm.

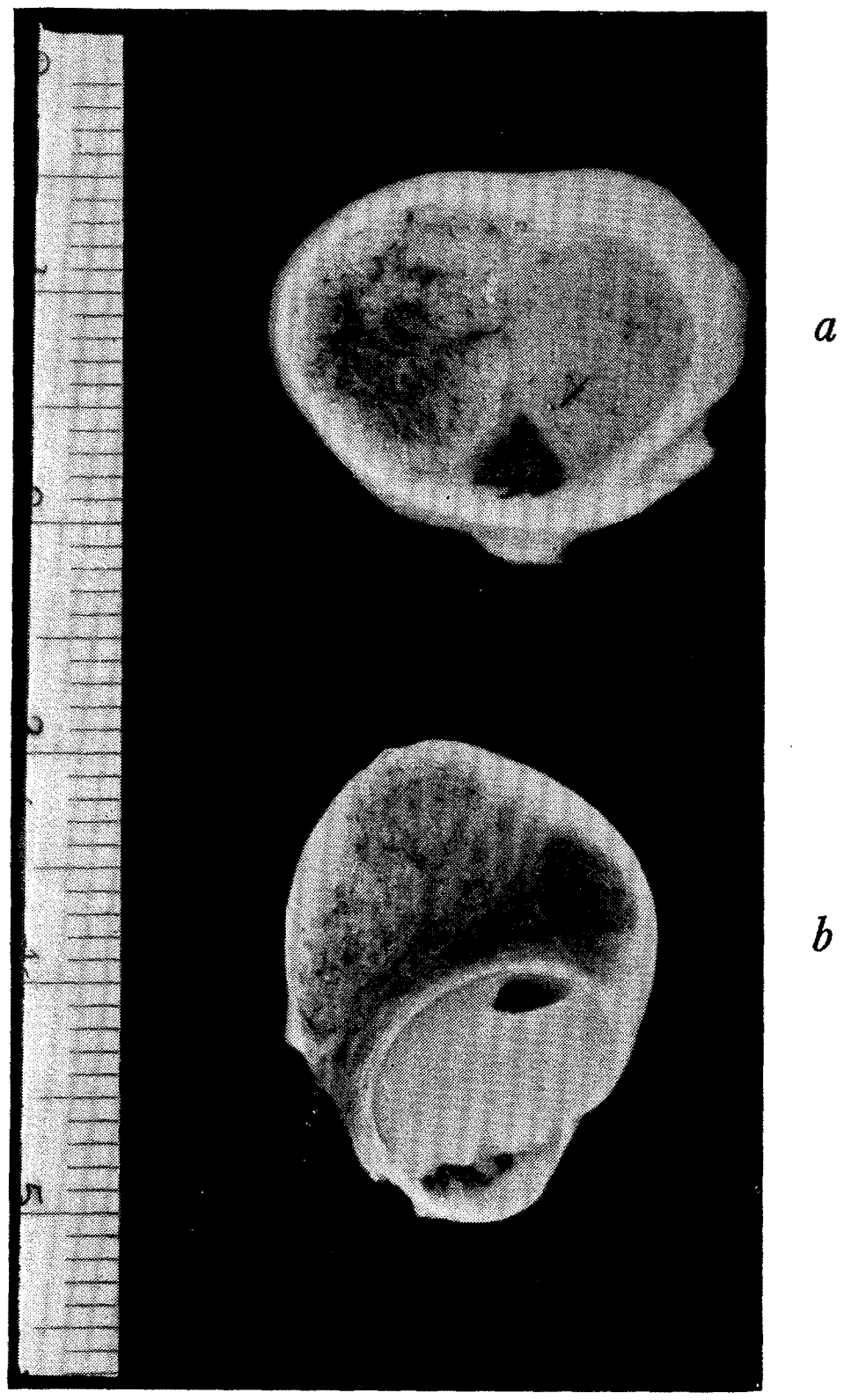

Fig. 54. Sections of ovary. *a*, pregnant: corpora lutea of three ages: the youngest on the right, the oldest below. *b*, at oestrus: two corpora lutea of different ages, the youngest on the left, and, below, a ripe follicle. Scale of cm.

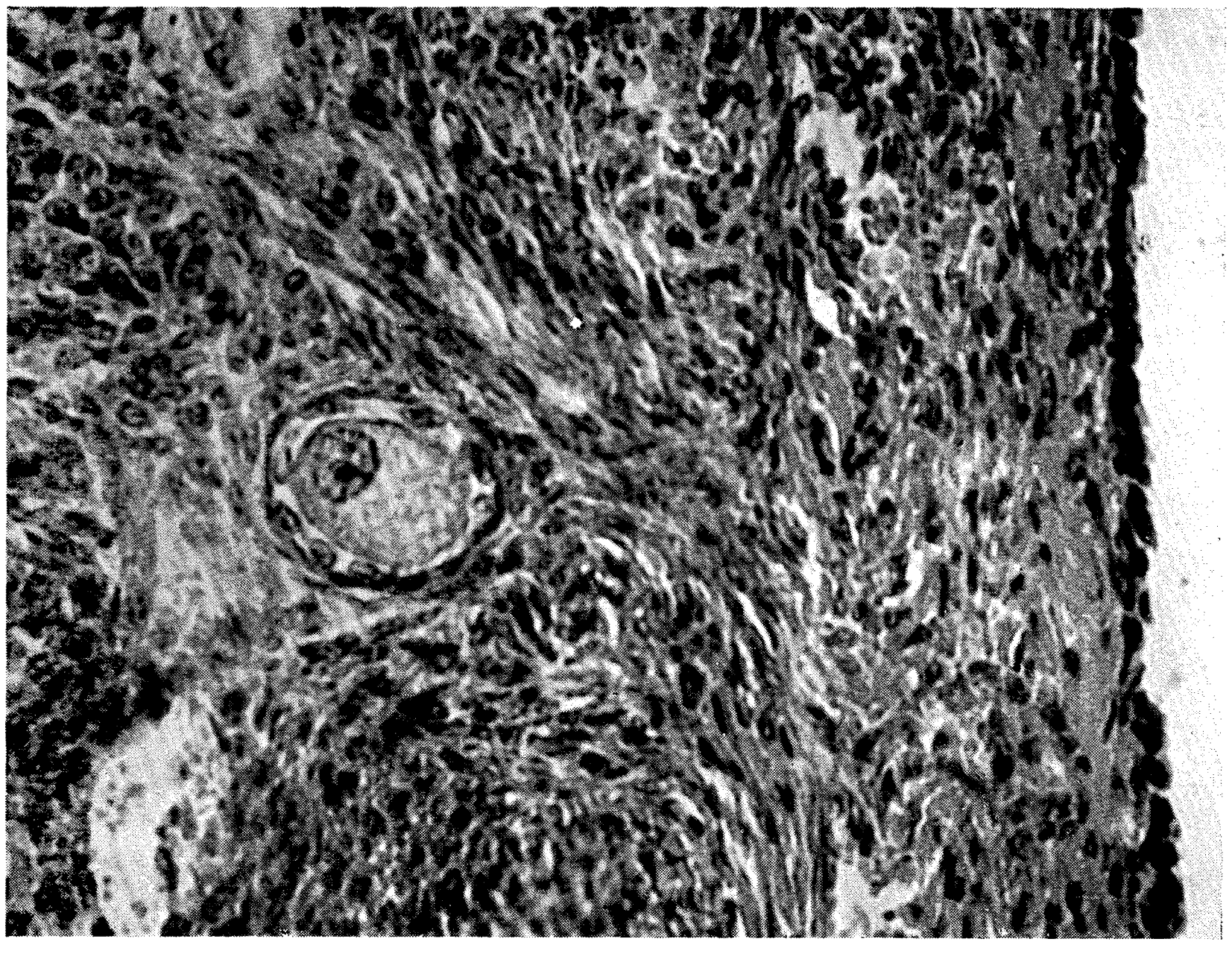

Fig. 56. A follicle early in the first stage of growth. The follicular epithelium consists of a single layer of flattened cells. The surface of the ovary, with the germinal epithelium, on the right. × 430.

FIG. 55. Section of part of the ovary showing cortex and peripheral stroma. The dearth of follicles is typical. × 130.

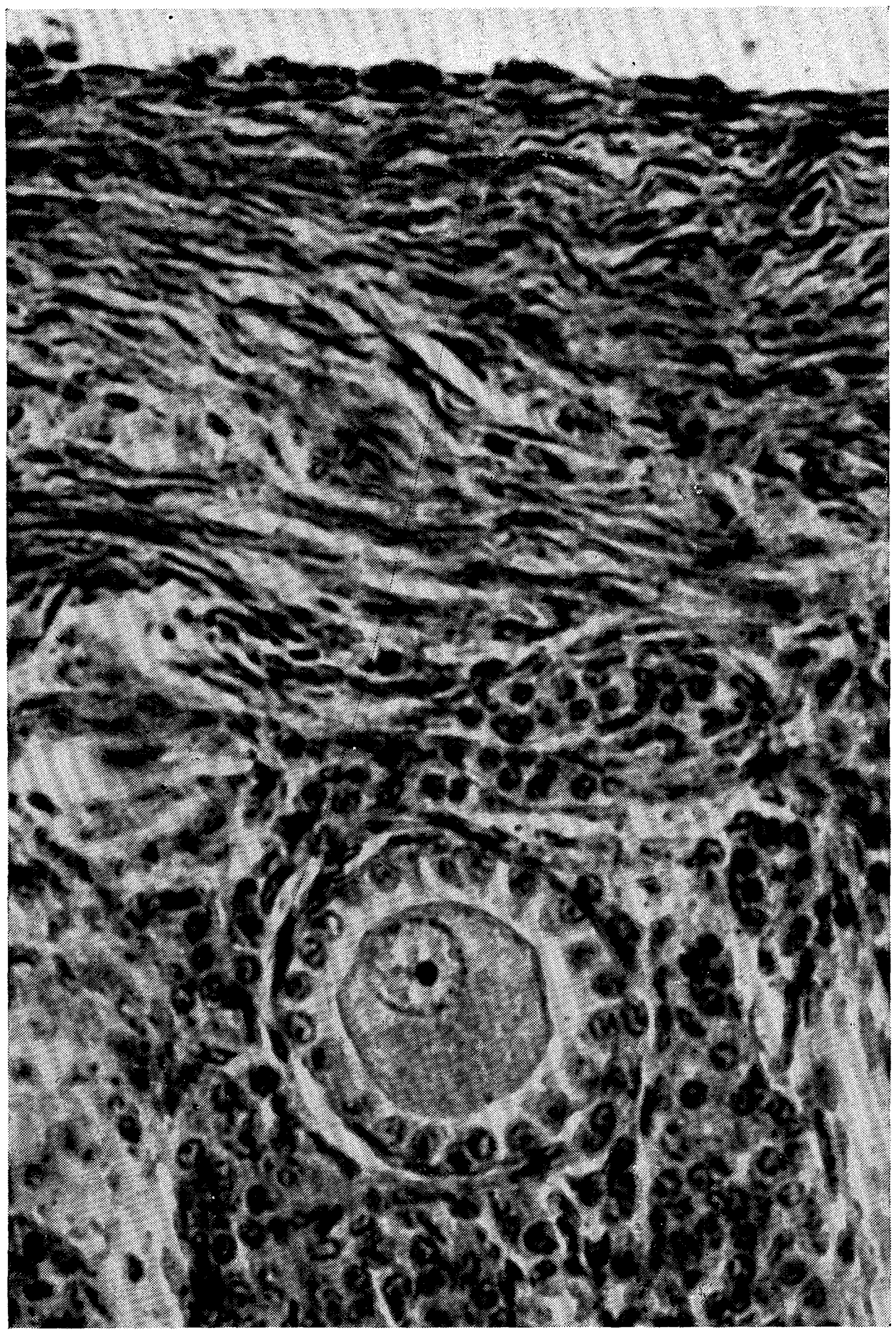

FIG. 57. Follicle late in the first stage of growth. The follicular epithelium consists of a single layer of cubical cells. Surface of the ovary above. × 430.

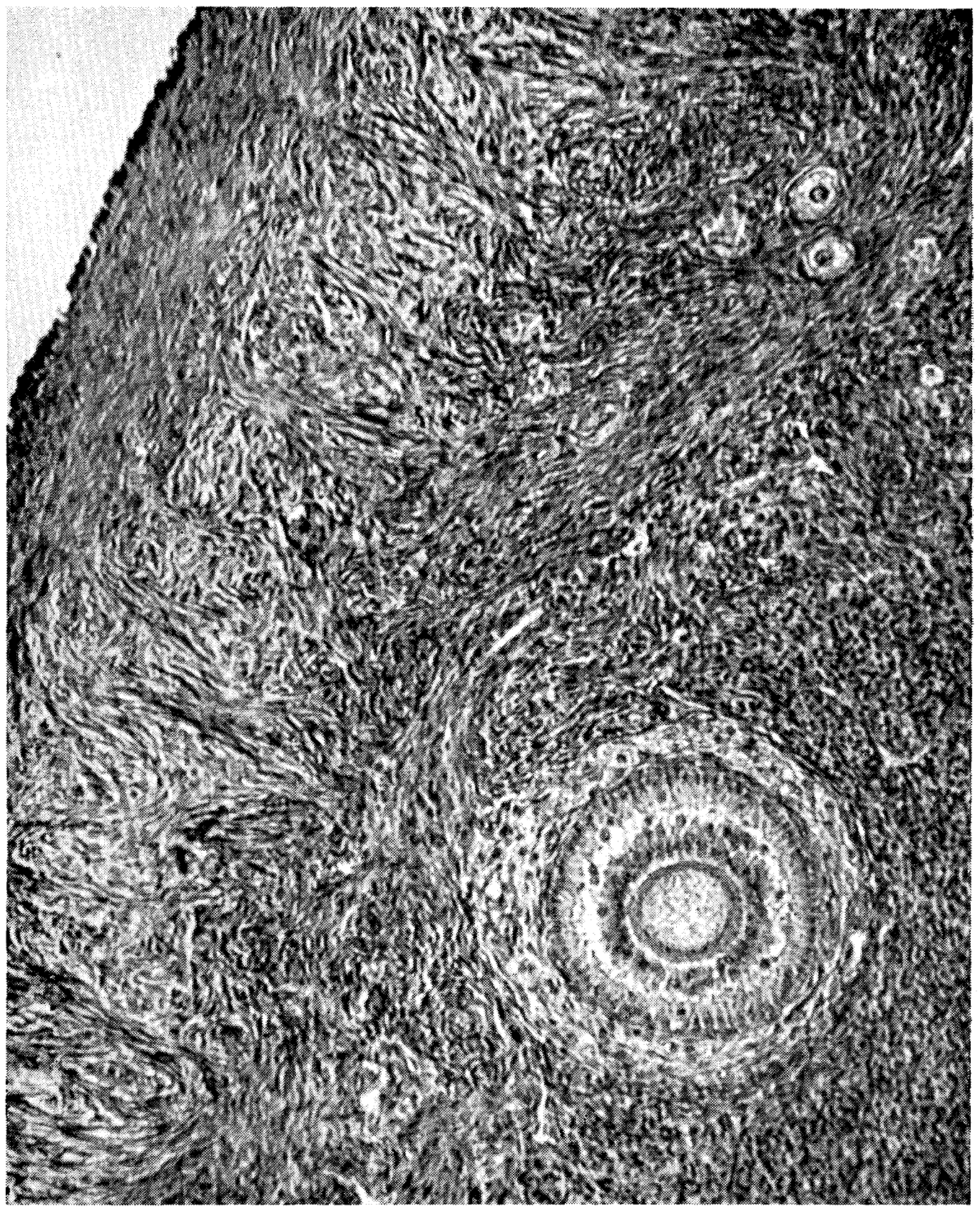

FIG. 58. A follicle in the second stage of growth. The follicular epithelium consists of two layers of cells. The follicle lies in the peripheral stroma, just internal to the cortex. × 130.

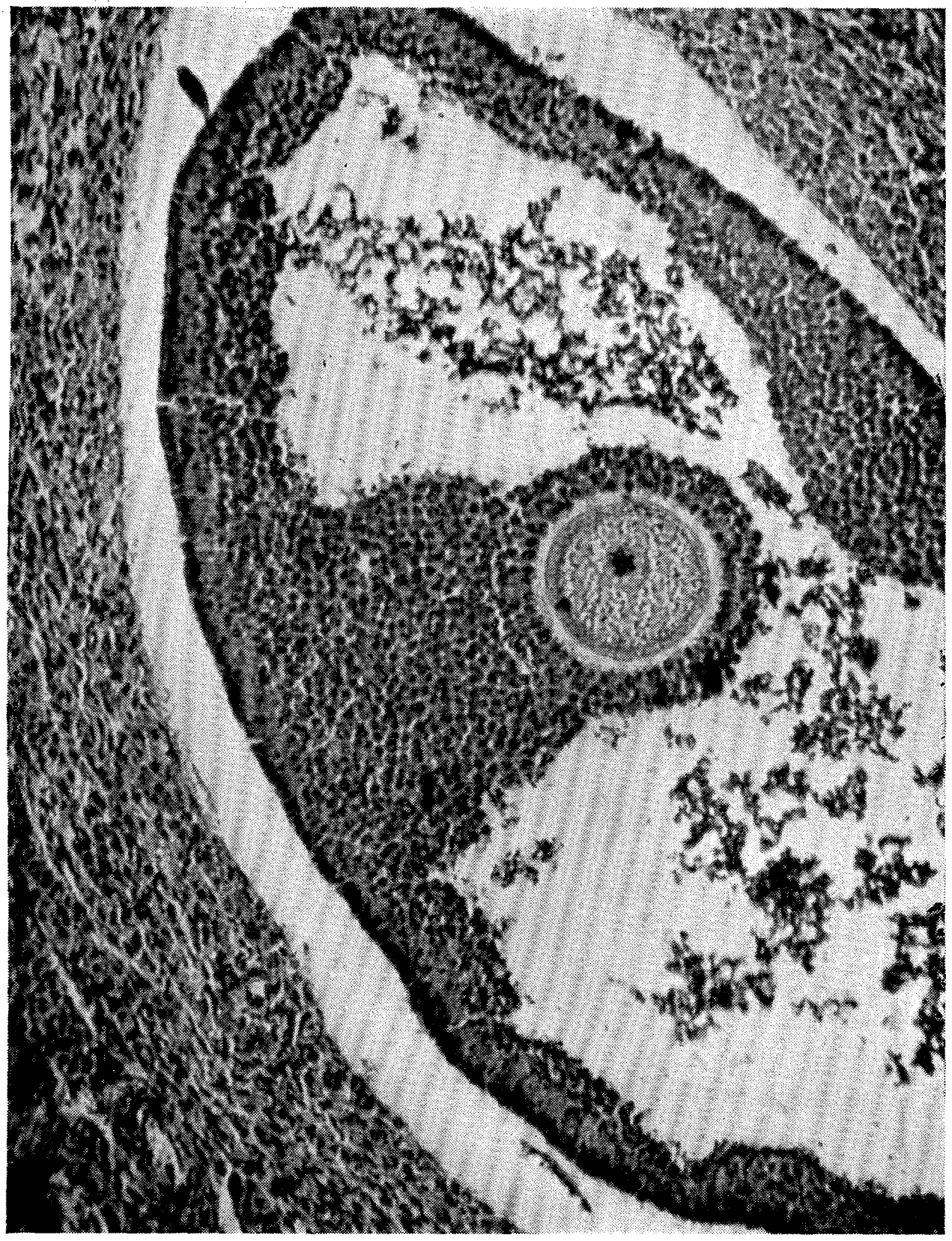

FIG. 59. A follicle early in the third stage of growth, with the formation of the antrum begun. The shrinkage of the epithelium from the follicular wall is due to fixation. The antrum contains coagulated liquor folliculi. × 130.

FIG. 60. A follicle in early atresia, with degenerate epithelium and central coagulum. × 130.

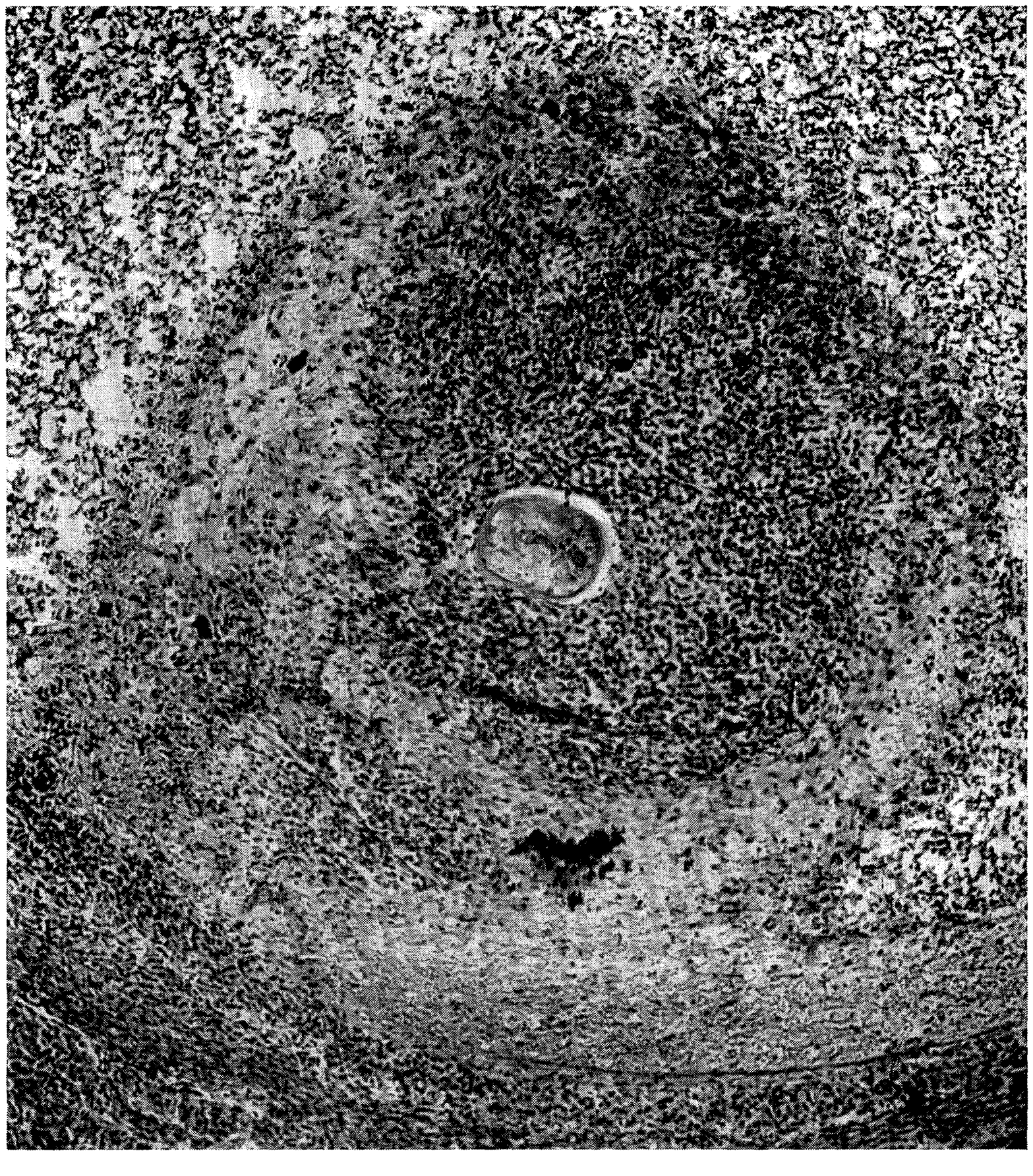

FIG. 61. Atresia in a follicle with a large antrum. The degenerate cumulus with remains of the ovum. The antrum is filled with coagulum. × 93.

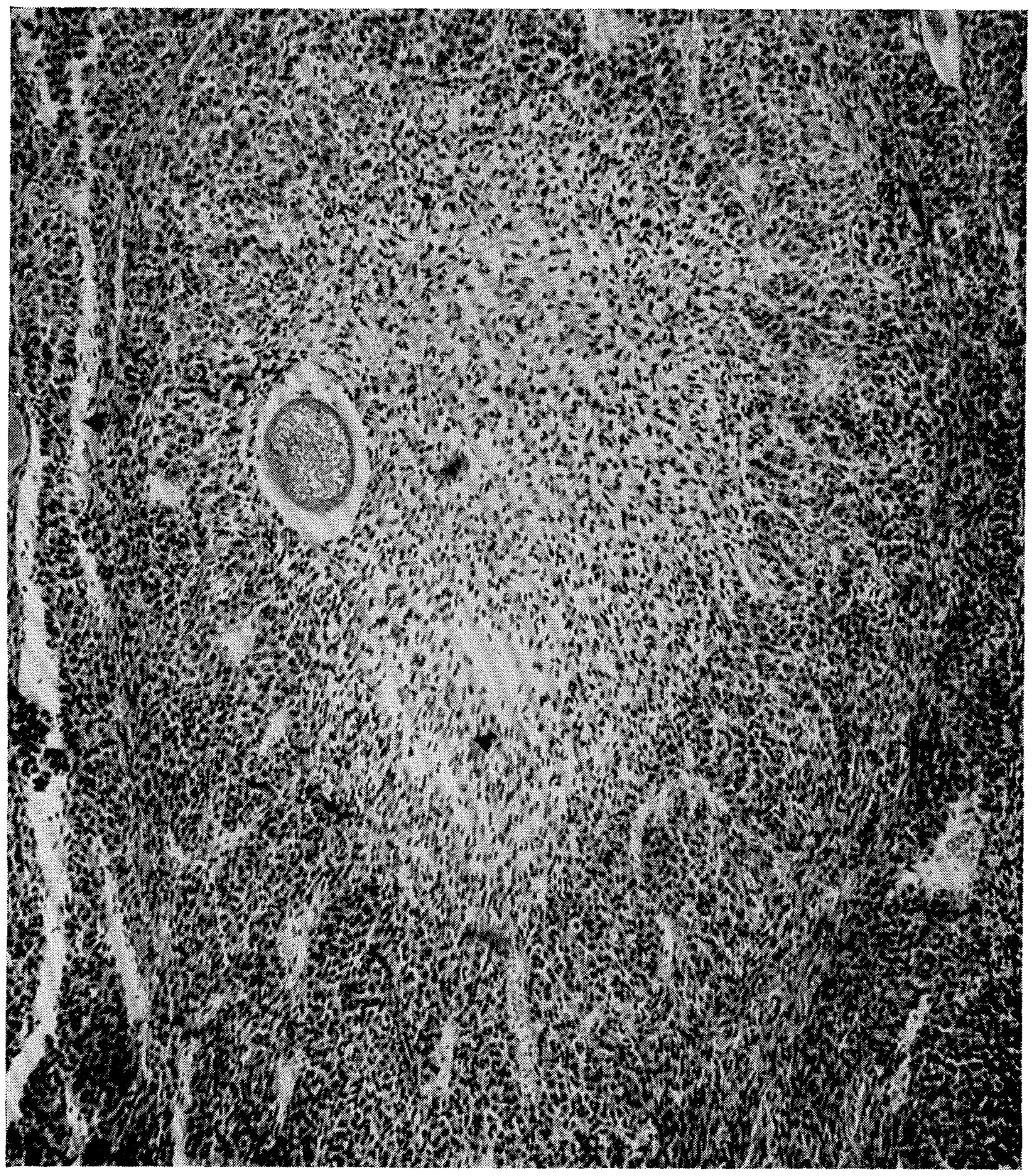

FIG. 62. An atretic follicle completely filled by invading connective tissue: remains of the ovum still conspicuous. × 93.

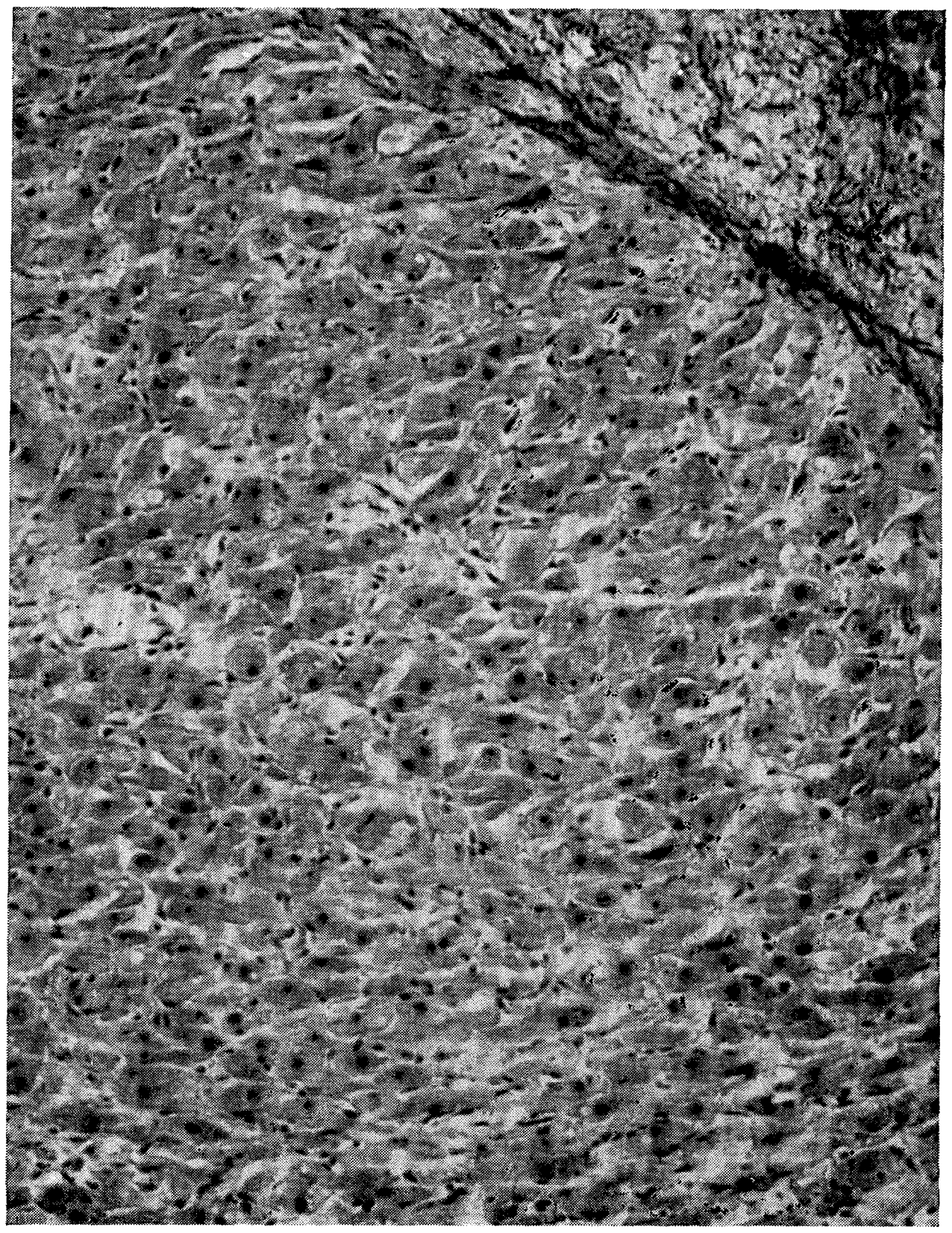

FIG. 64. Part of a very young corpus luteum. A portion of the central clot of fibrin is seen at the top right-hand corner. × 130.

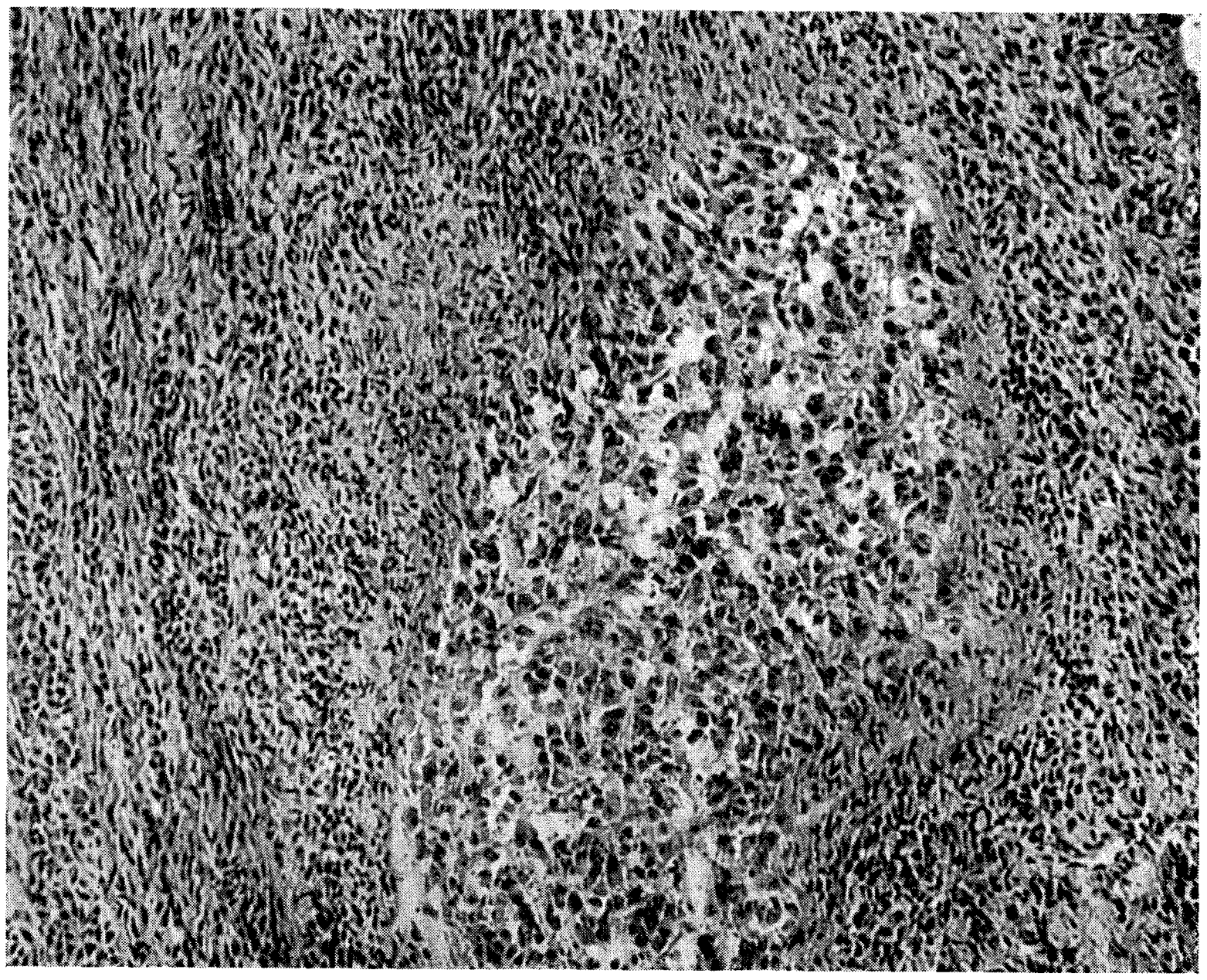

FIG. 63. Luteal atresia in a prepubertal animal. × 130.

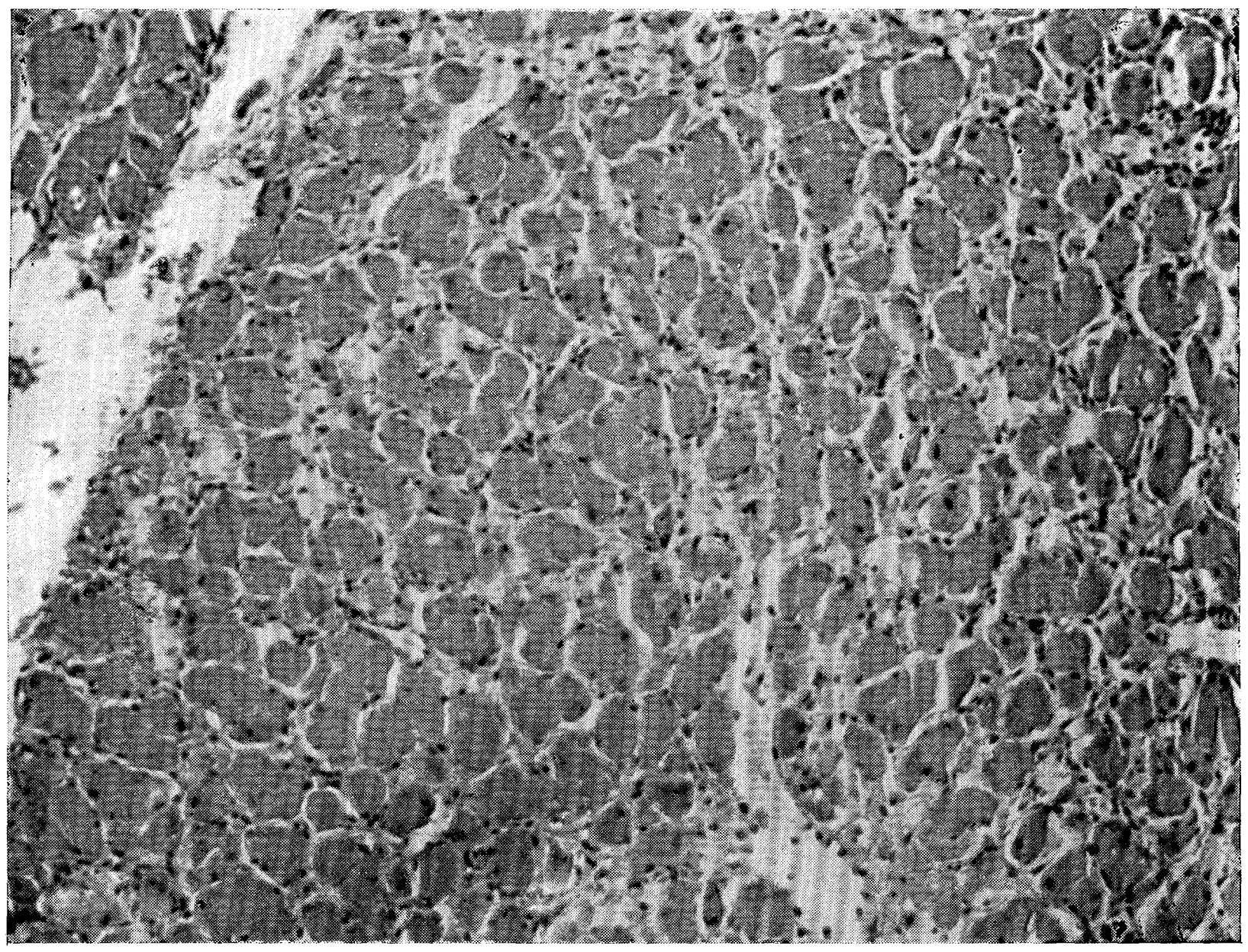

FIG. 65. Corpus luteum in early pregnancy. Part of the central space, from which the clot has been resorbed, is shown. × 130.

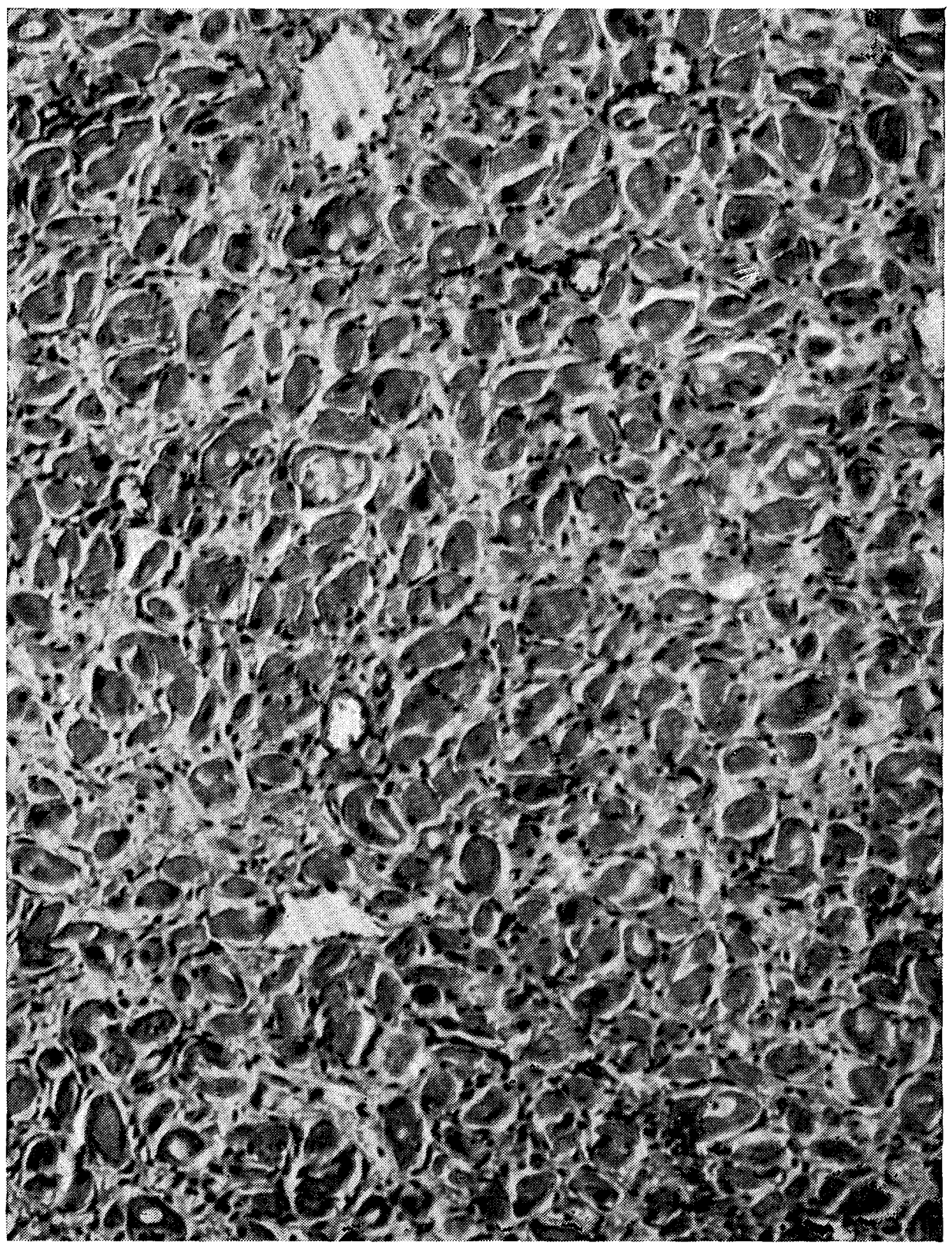

FIG. 66. Corpus luteum at about mid-pregnancy. × 130.

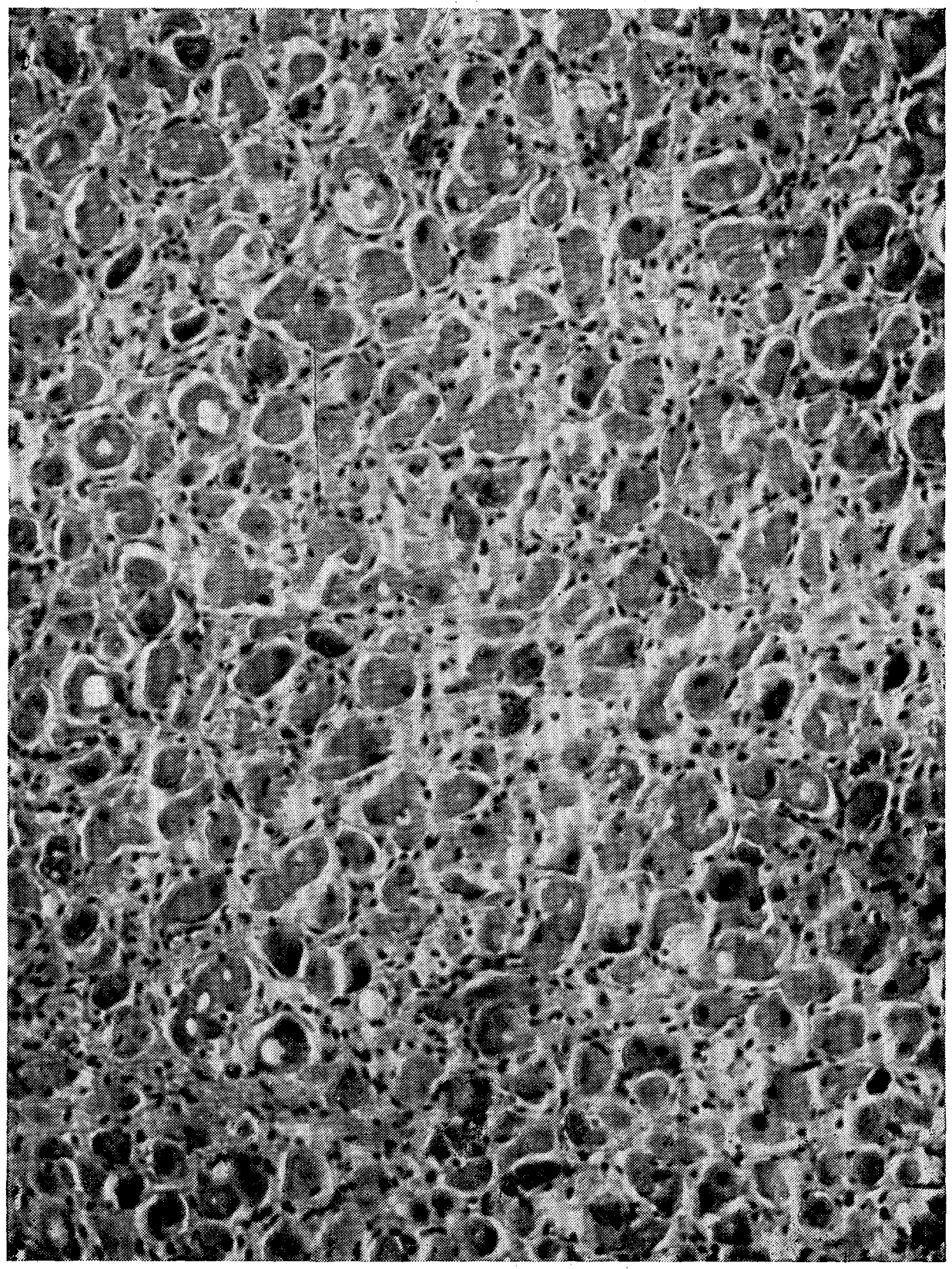

FIG. 67. Corpus luteum nearly at full term of pregnancy. × 130.

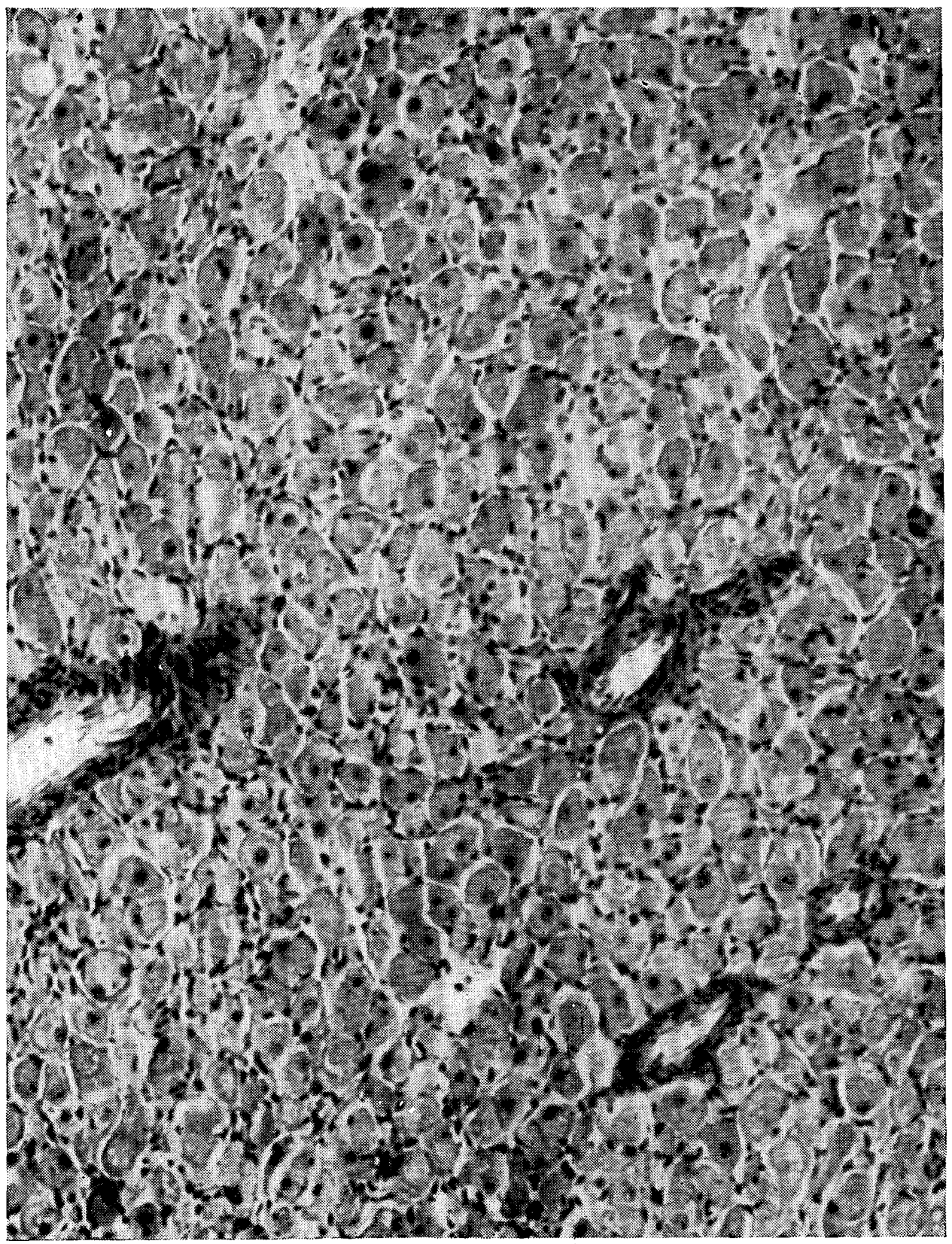

FIG. 68. Corpus luteum in early lactation. × 130.

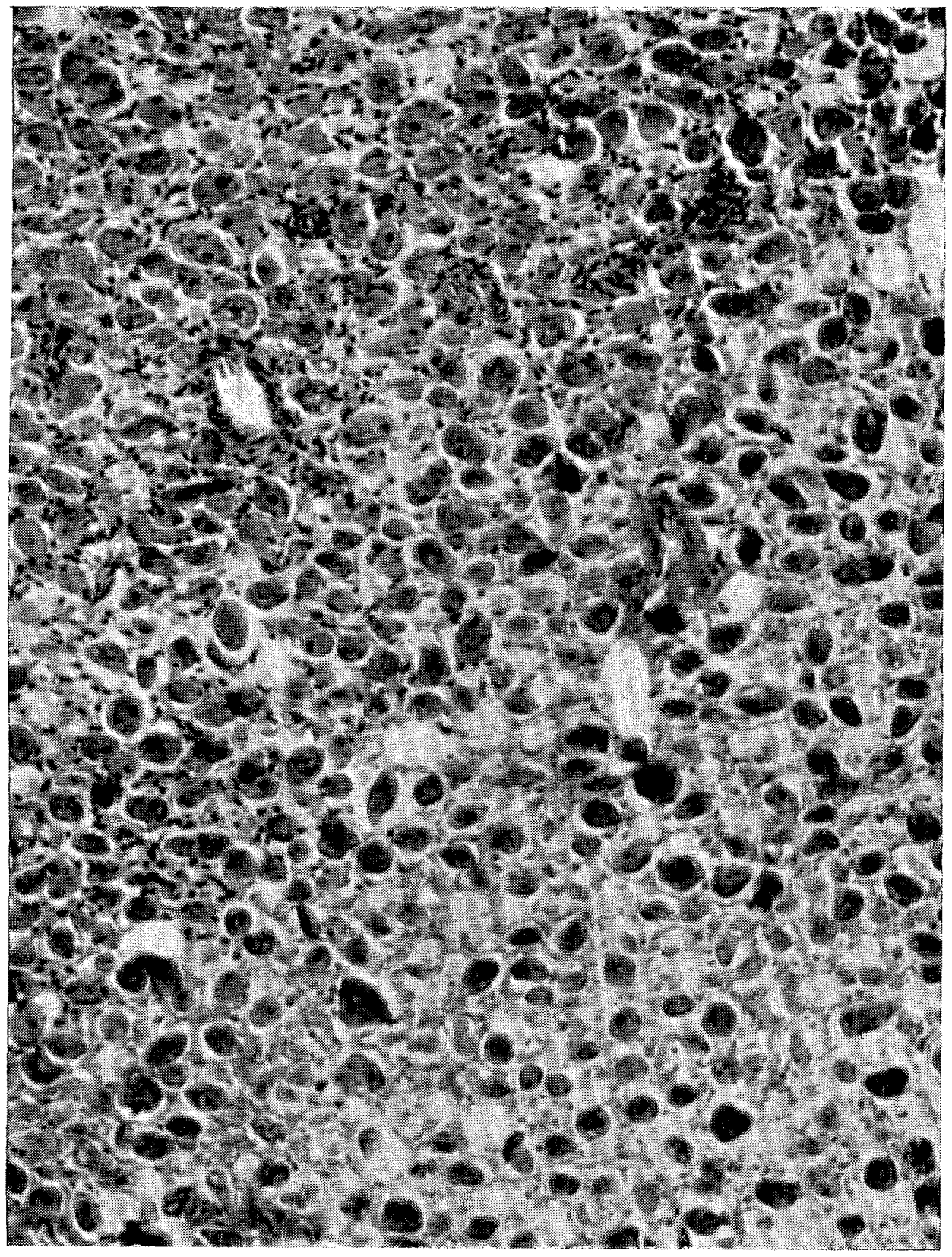

FIG. 69. Corpus luteum late in lactation. × 130.

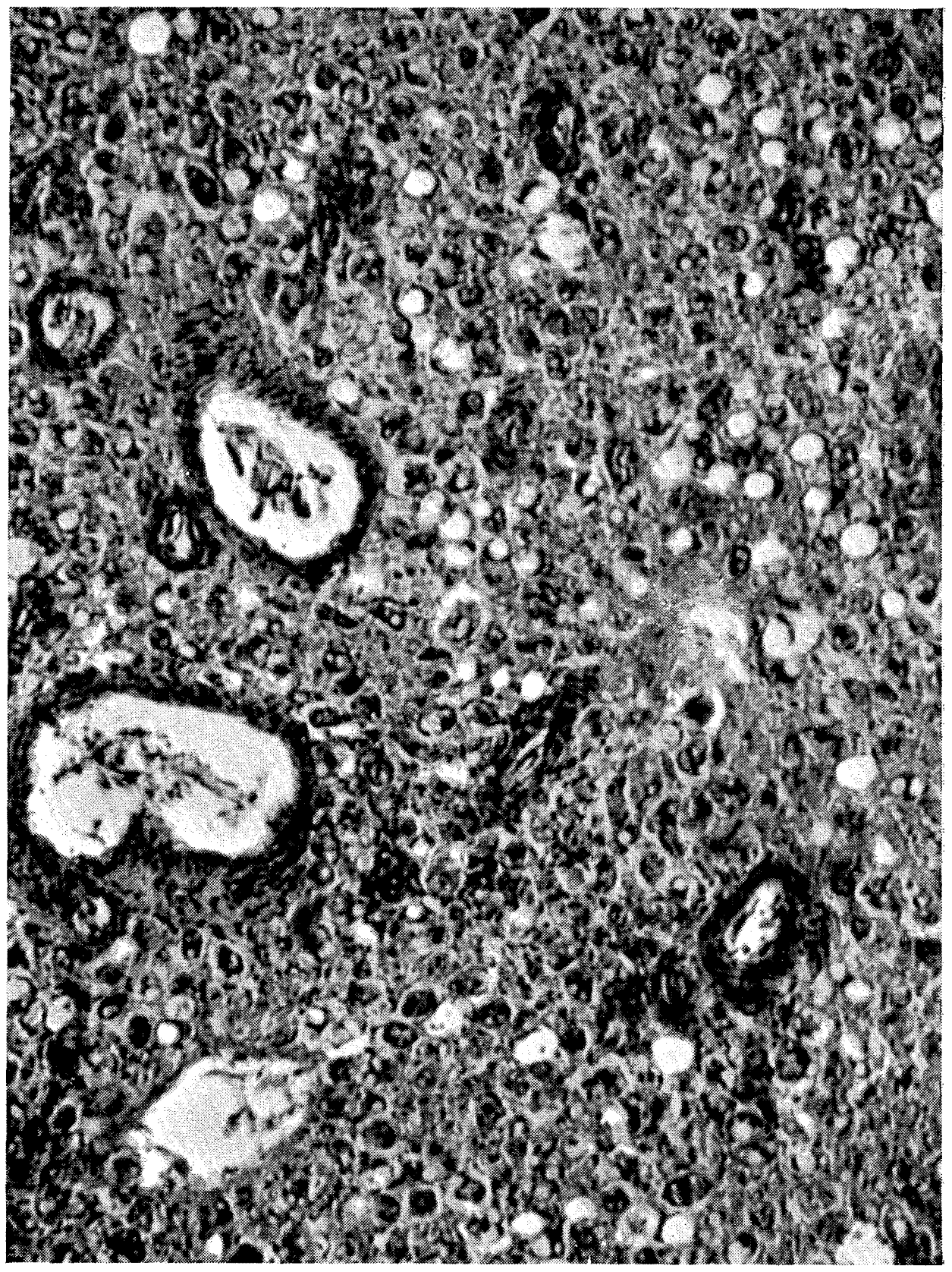

FIG. 70. Section of old corpus luteum showing blood vessels and vacuoles. × 130.

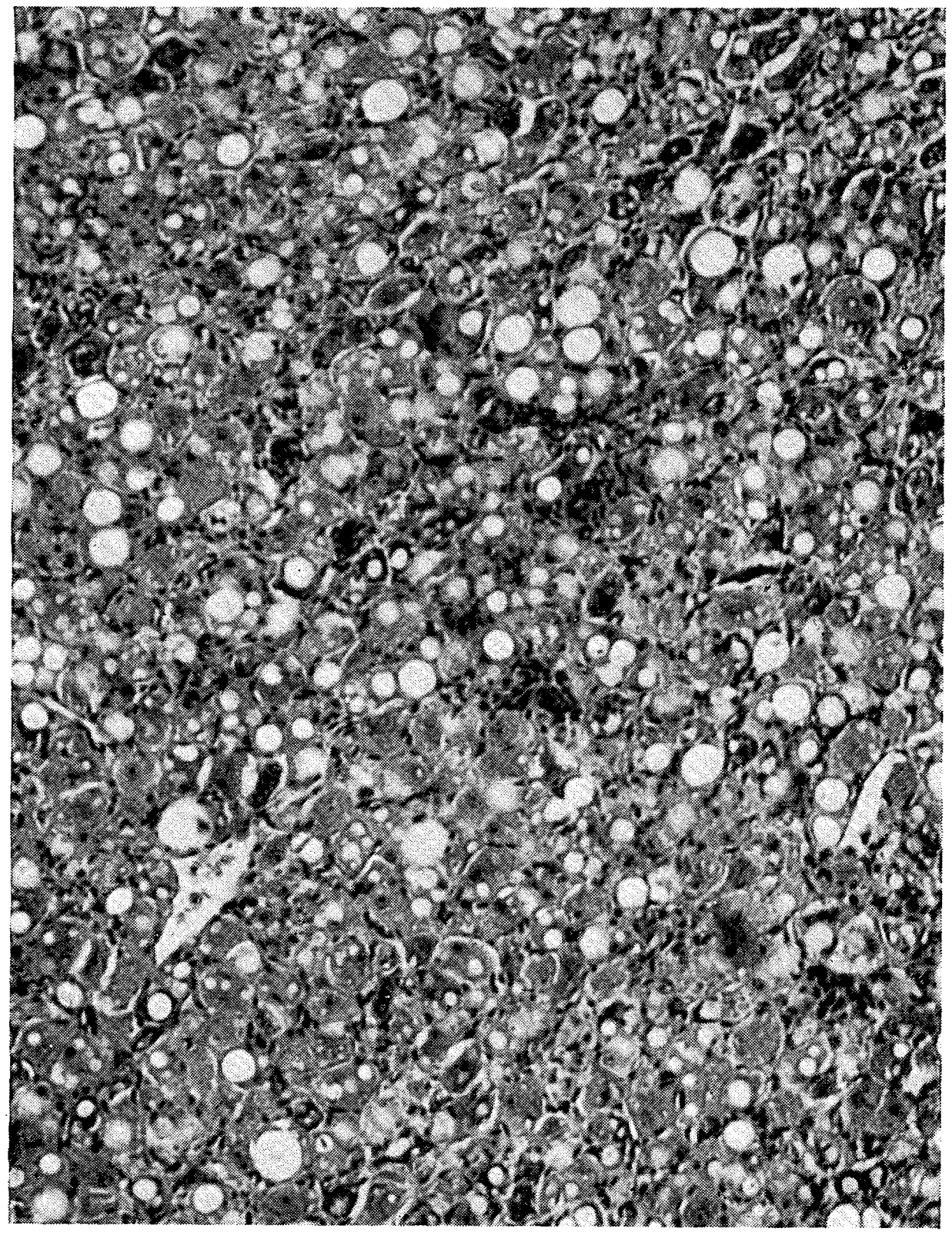

FIG. 71. The occurrence of vacuoles in a comparatively young corpus luteum. × 130.

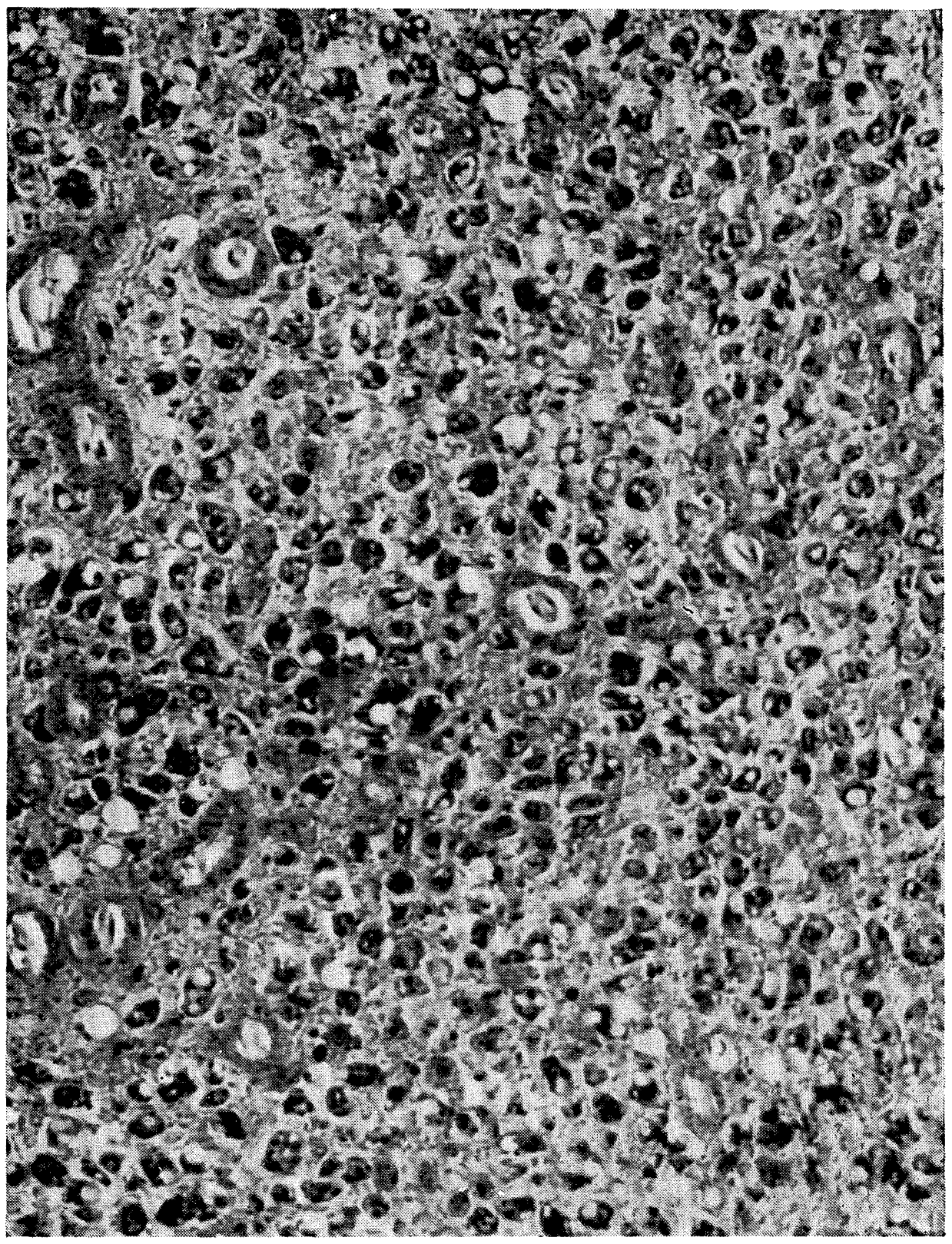

FIG. 72. Section of very old residual corpus luteum. × 130.

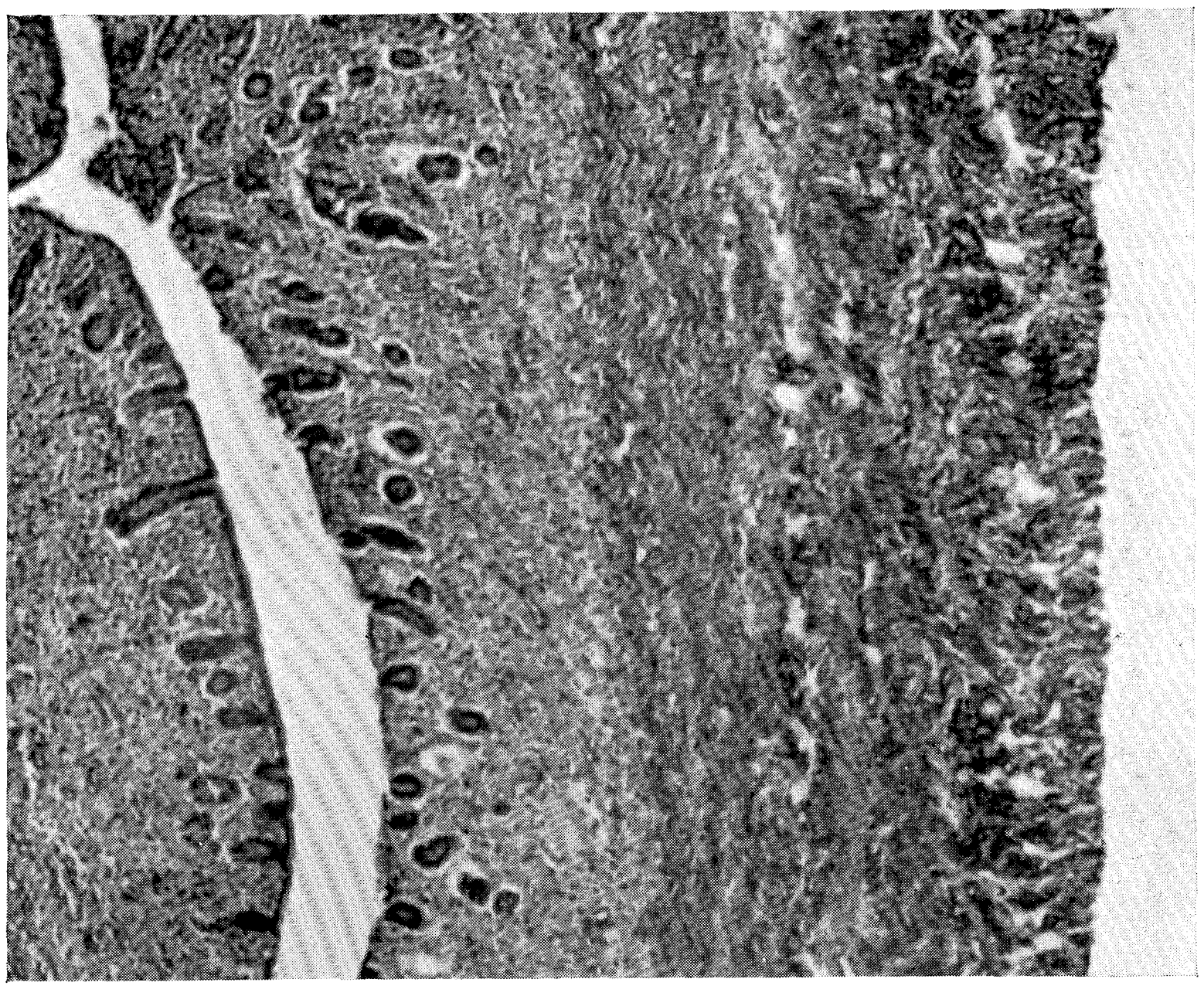

Fig. 73. Uterine mucosa. Prepubertal group A. × 130.

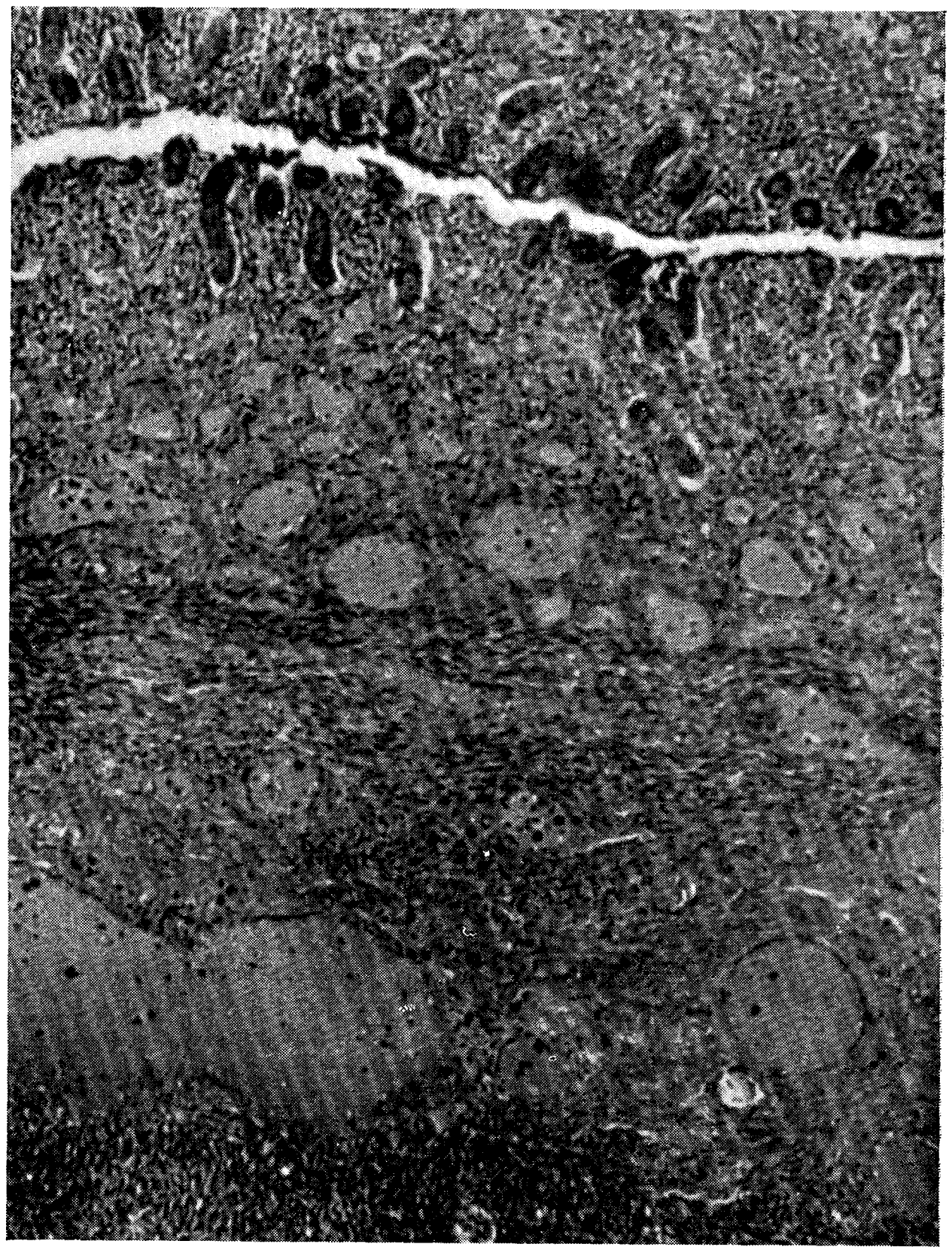

Fig. 74. Uterine mucosa and muscle layers highly vascularized. Prepubertal group B, approaching first oestrus. × 130.

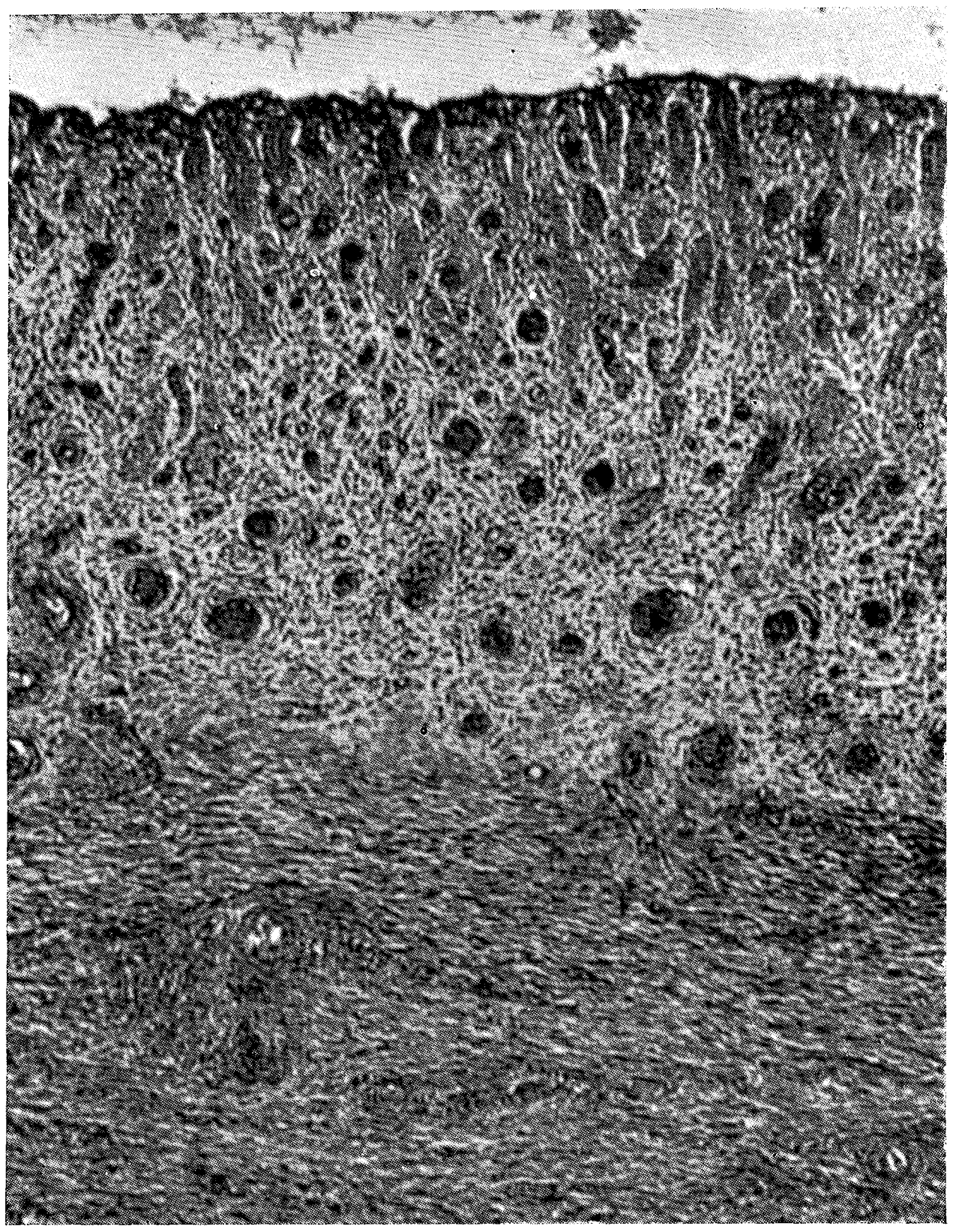

Fig. 76. Uterine mucosa at the beginning of pro-oestrus: increase in number and length of glands. × 130.

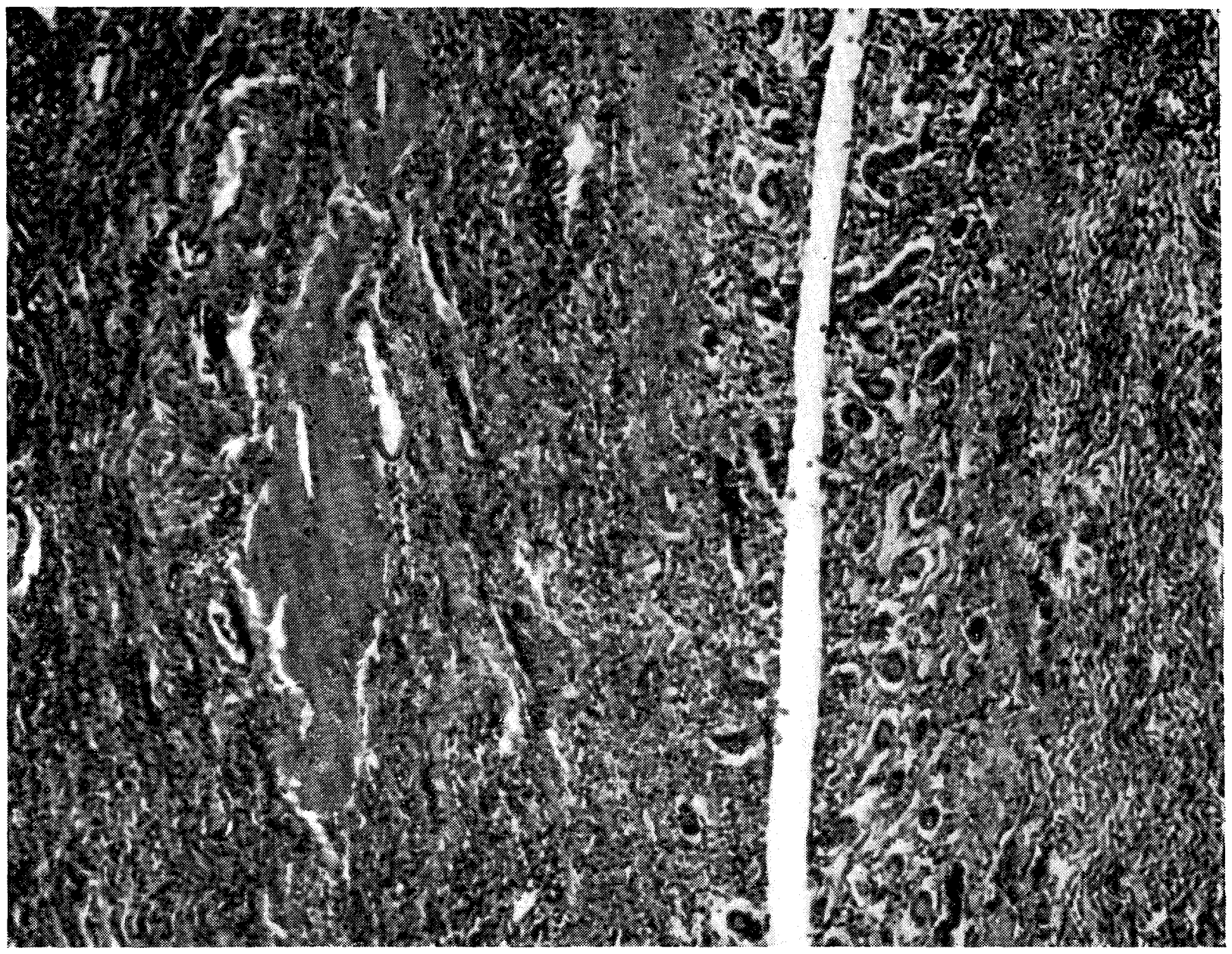

Fig. 75. Uterine mucosa during lactation. × 130.

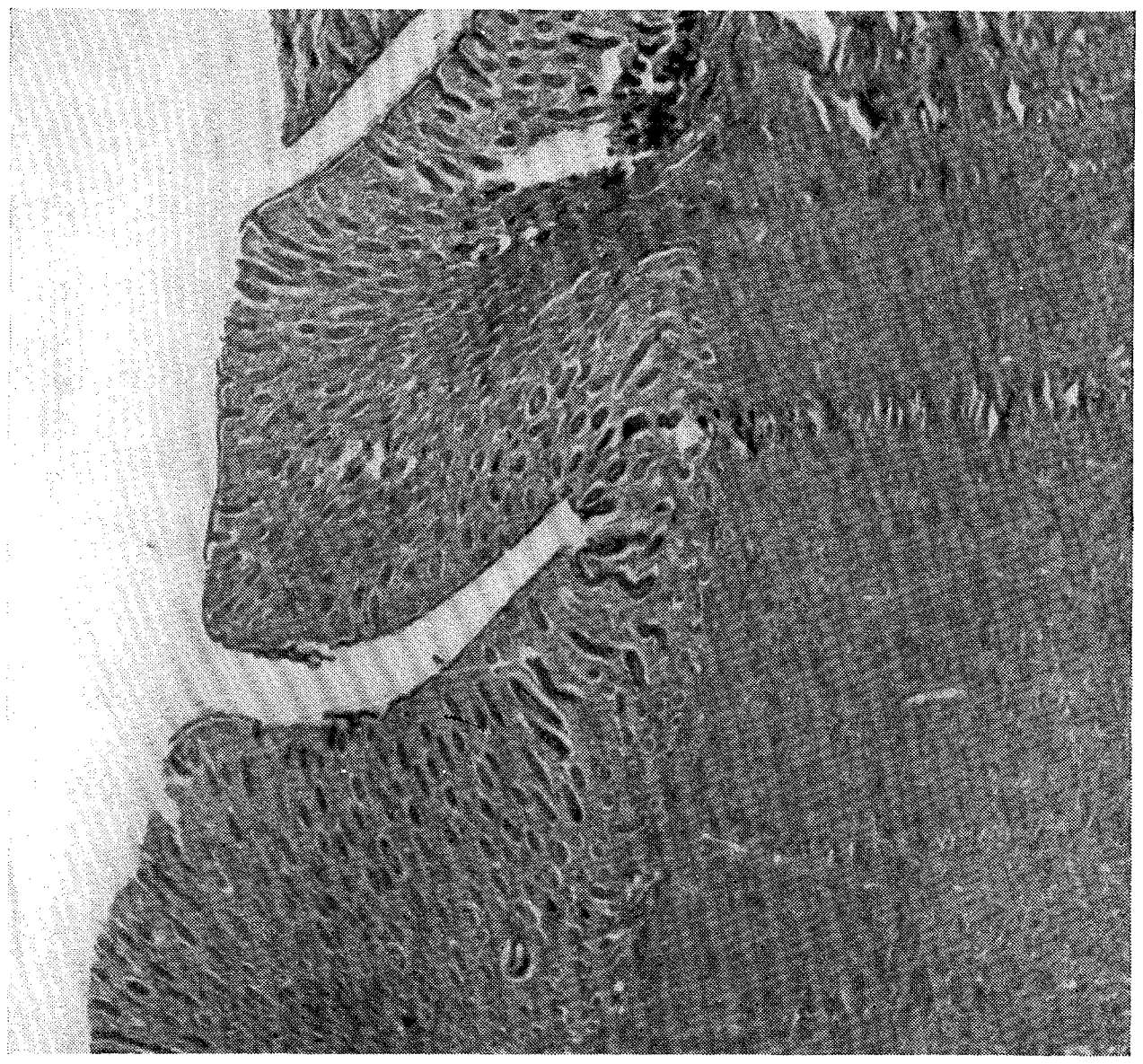

FIG. 77. Uterine mucosa at oestrus. × 30.

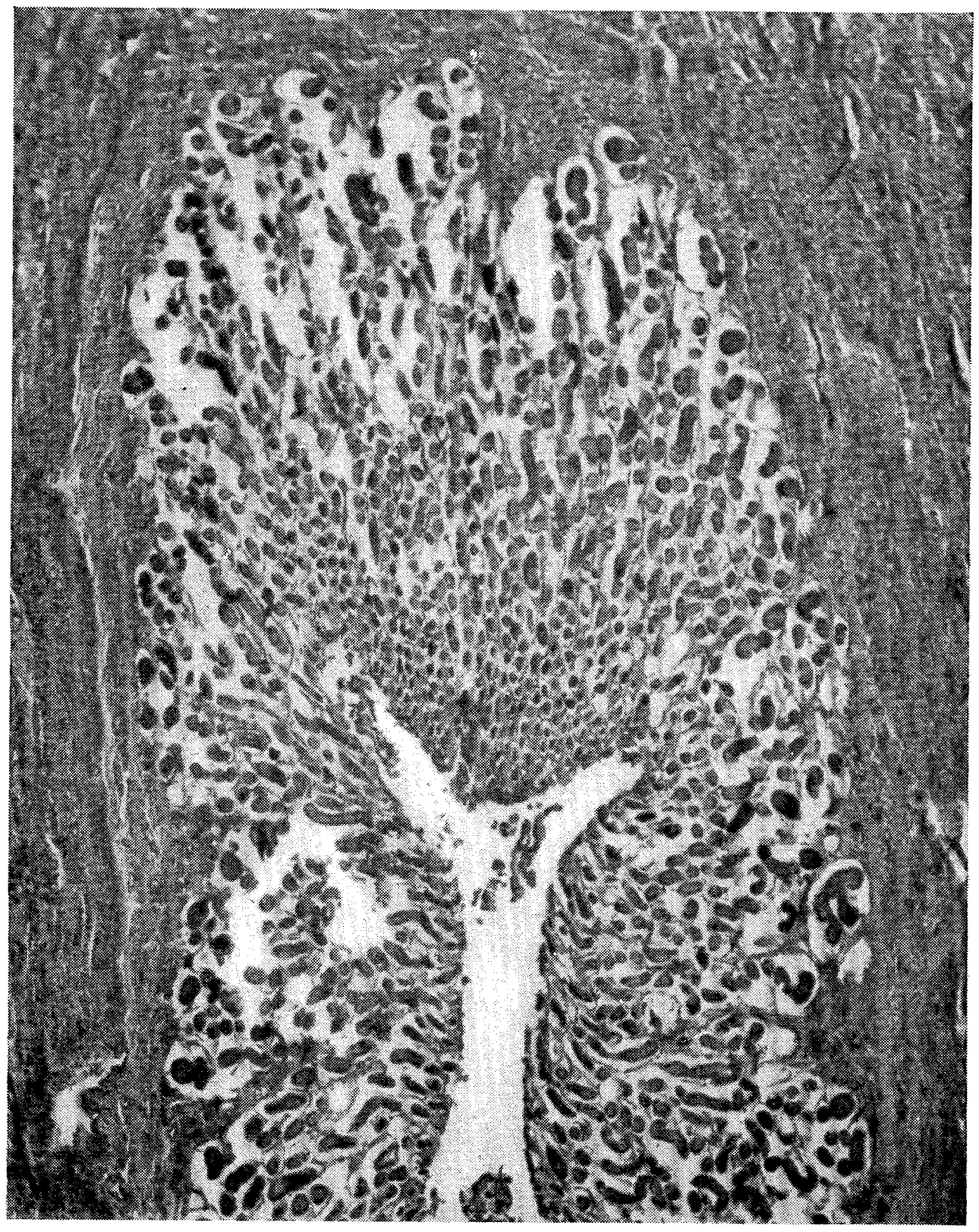

FIG. 78. Uterine mucosa: progestational proliferation. The shrinkage is due to delay in fixation. × 30.

FIG. 79. Uterine mucosa of the sterile horn in early pregnancy. The bases of the wide glands have narrow tails which penetrate the muscularis mucosae. × 130.

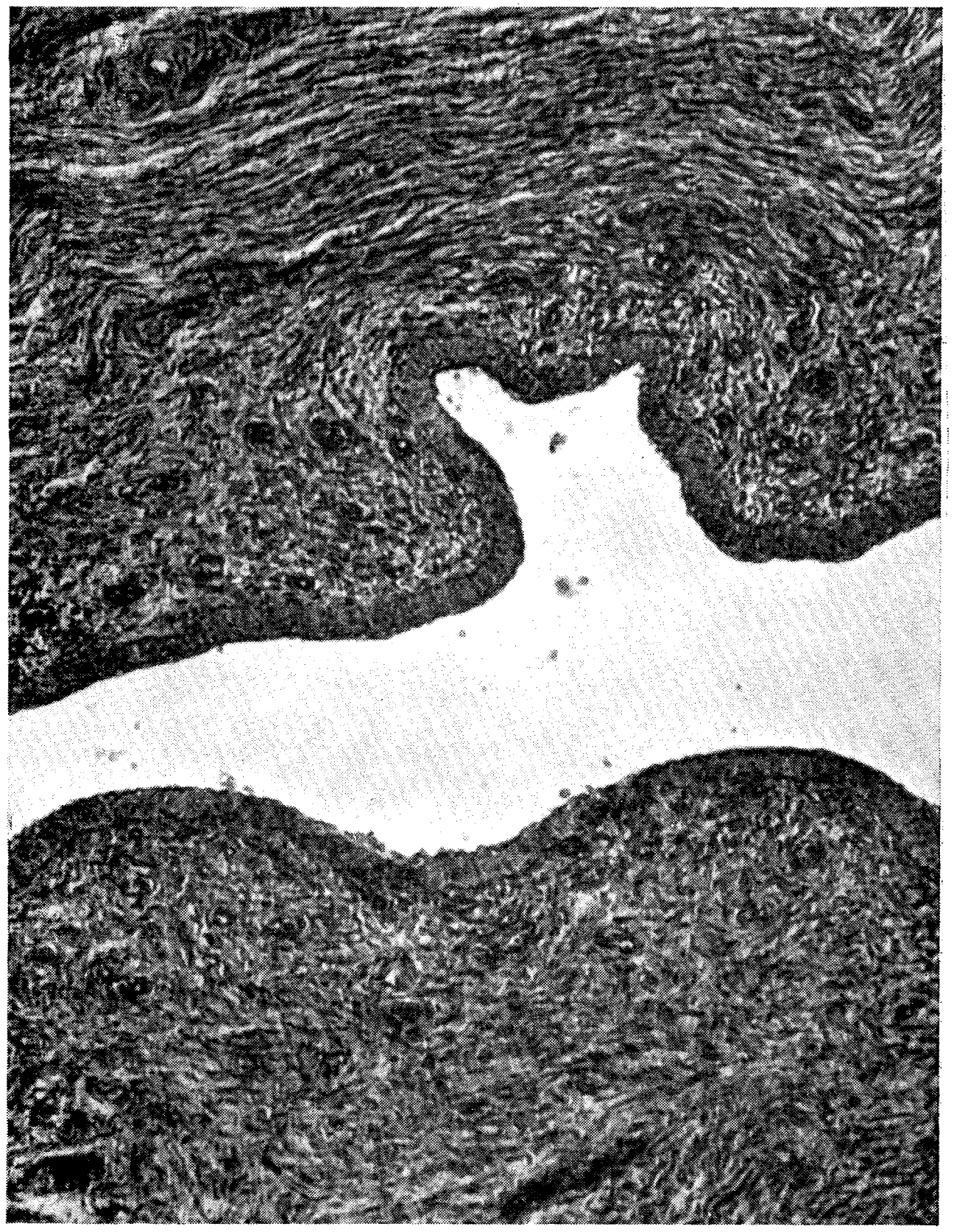

FIG. 81. Vaginal wall and epithelium in anoestrus (prepubertal). × 130.

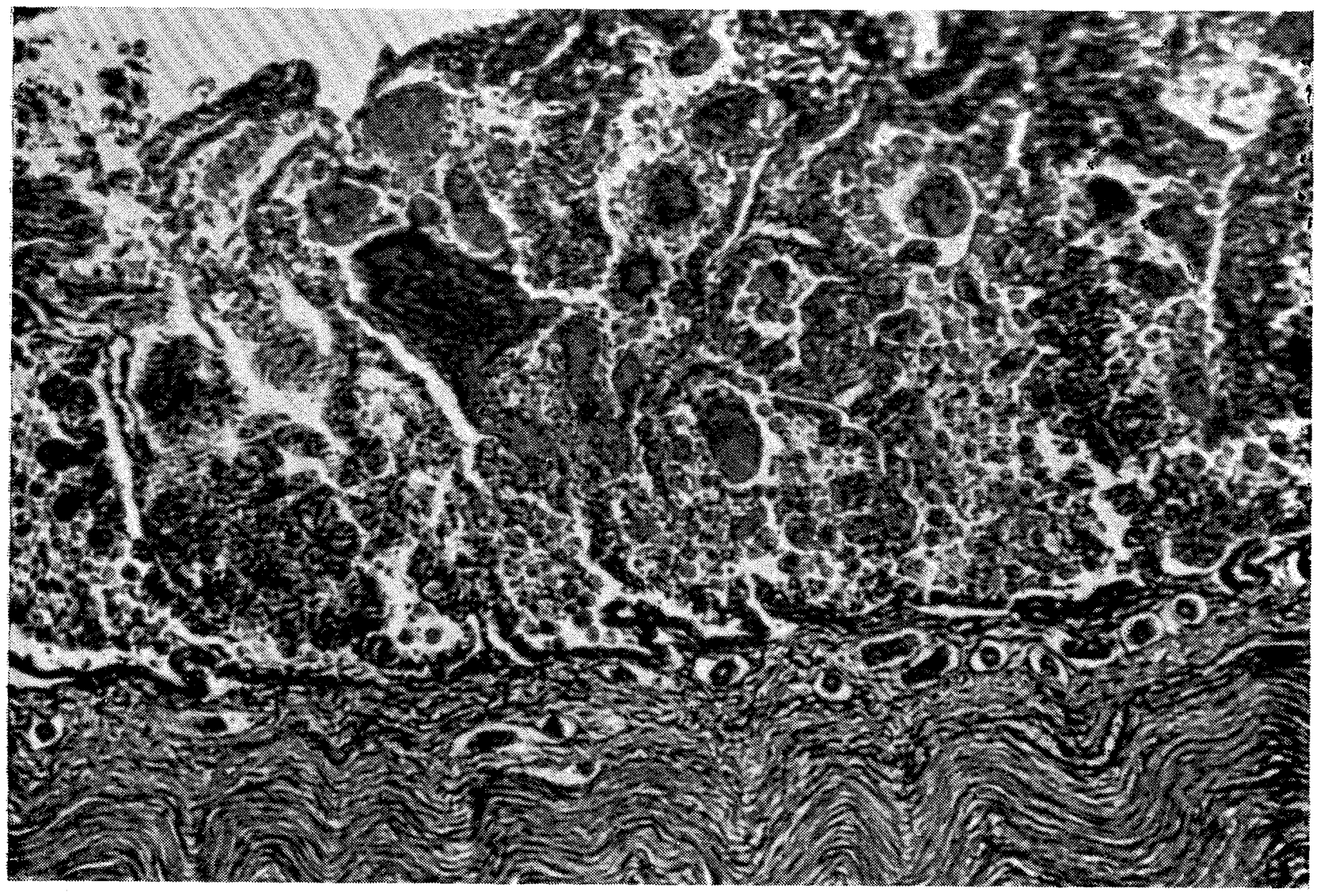

Fig. 80 (on left). Uterine mucosa of the sterile horn in late pregnancy. The epithelium of the bases of the glands is forming a new epithelial lining for the uterus beneath the degenerate mucosa. × 130.

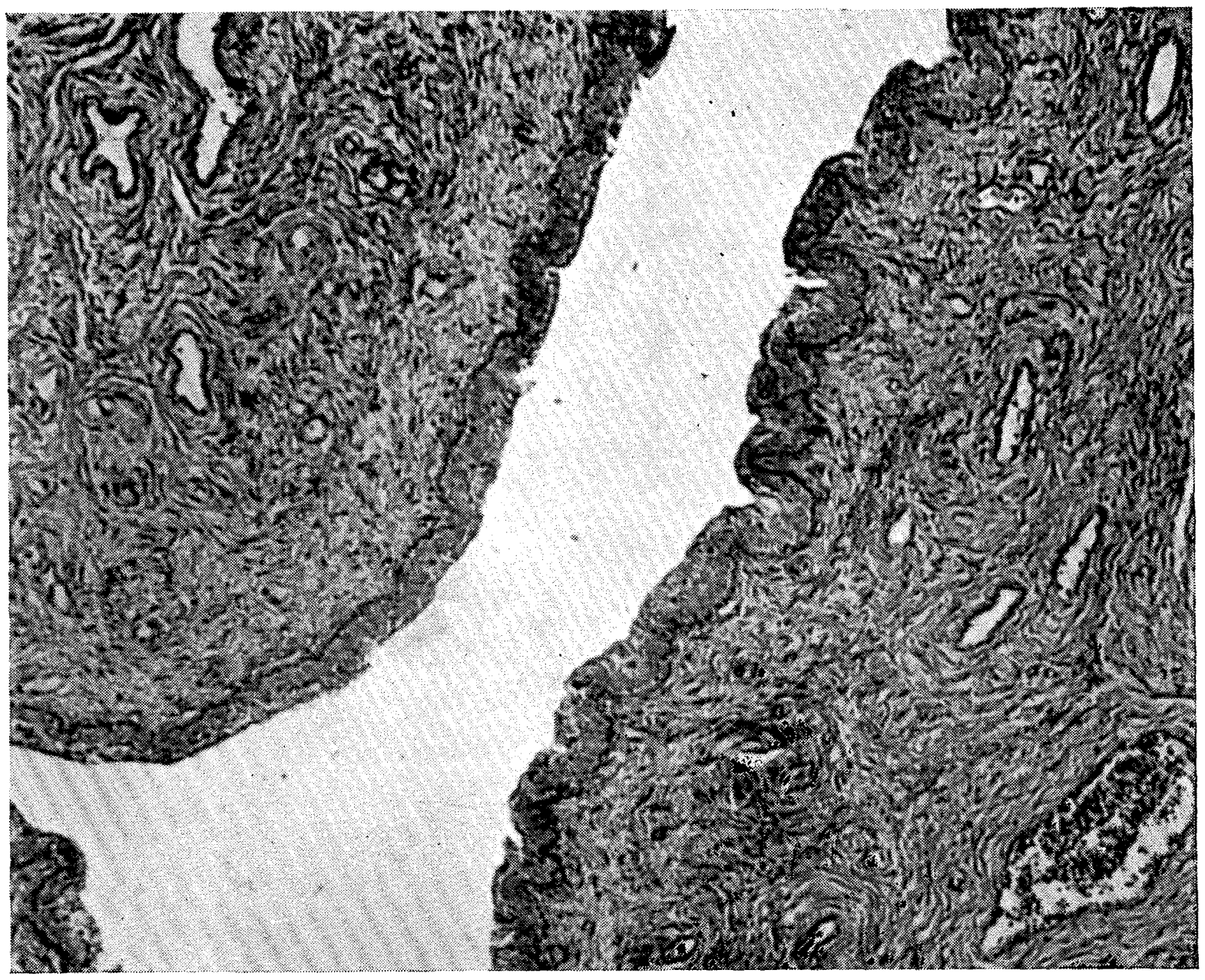

Fig. 82 (on right). Vaginal wall and epithelium in anoestrus (parous). × 130.

Fig. 83 (above). Vaginal wall and epithelium at oestrus. Vascularization of muscle layer. Cornification of epithelium and separation of it into layers. Desquamation into lumen. × 130.

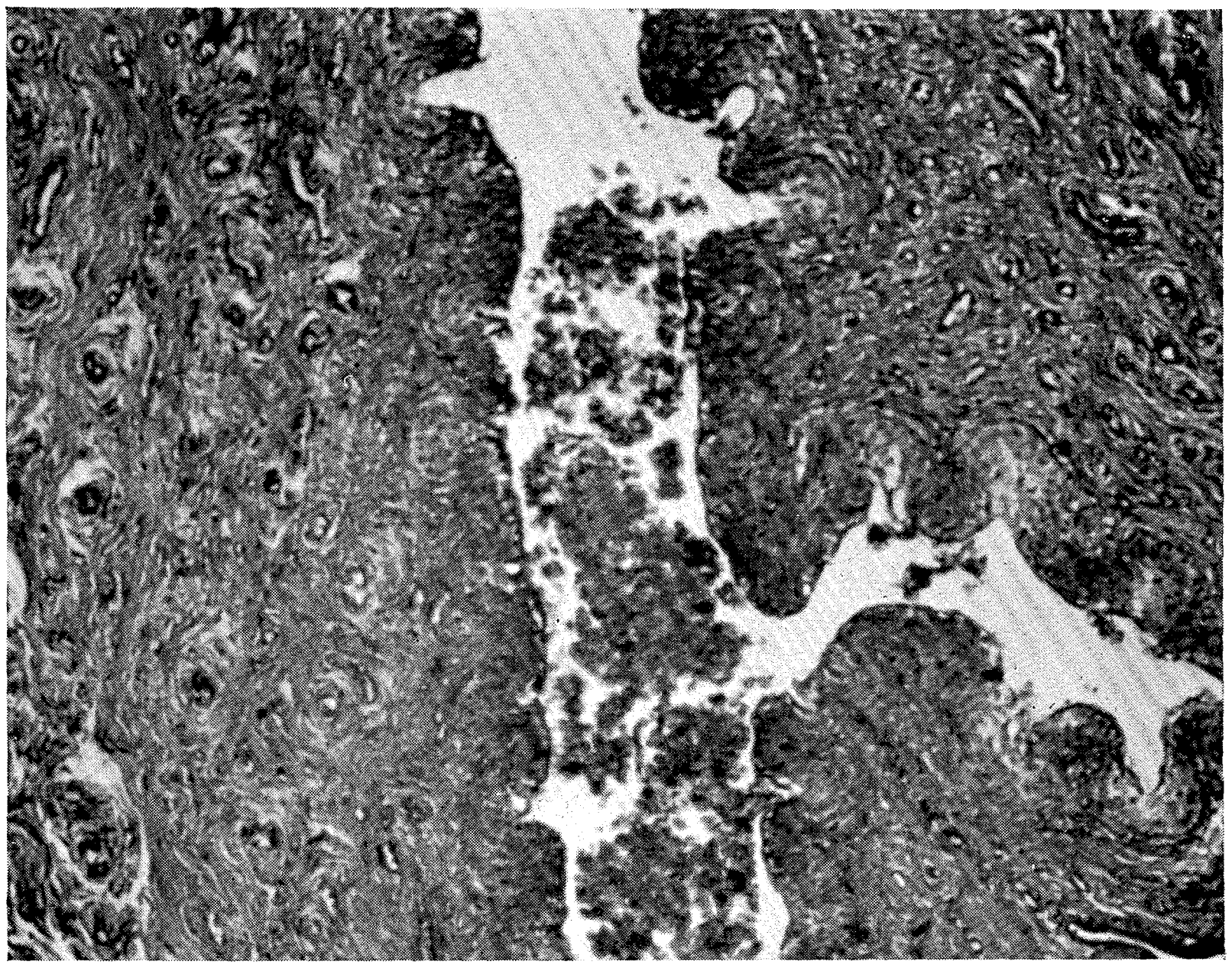

Fig. 84 (on right). Vaginal wall and epithelium during pregnancy. × 130.

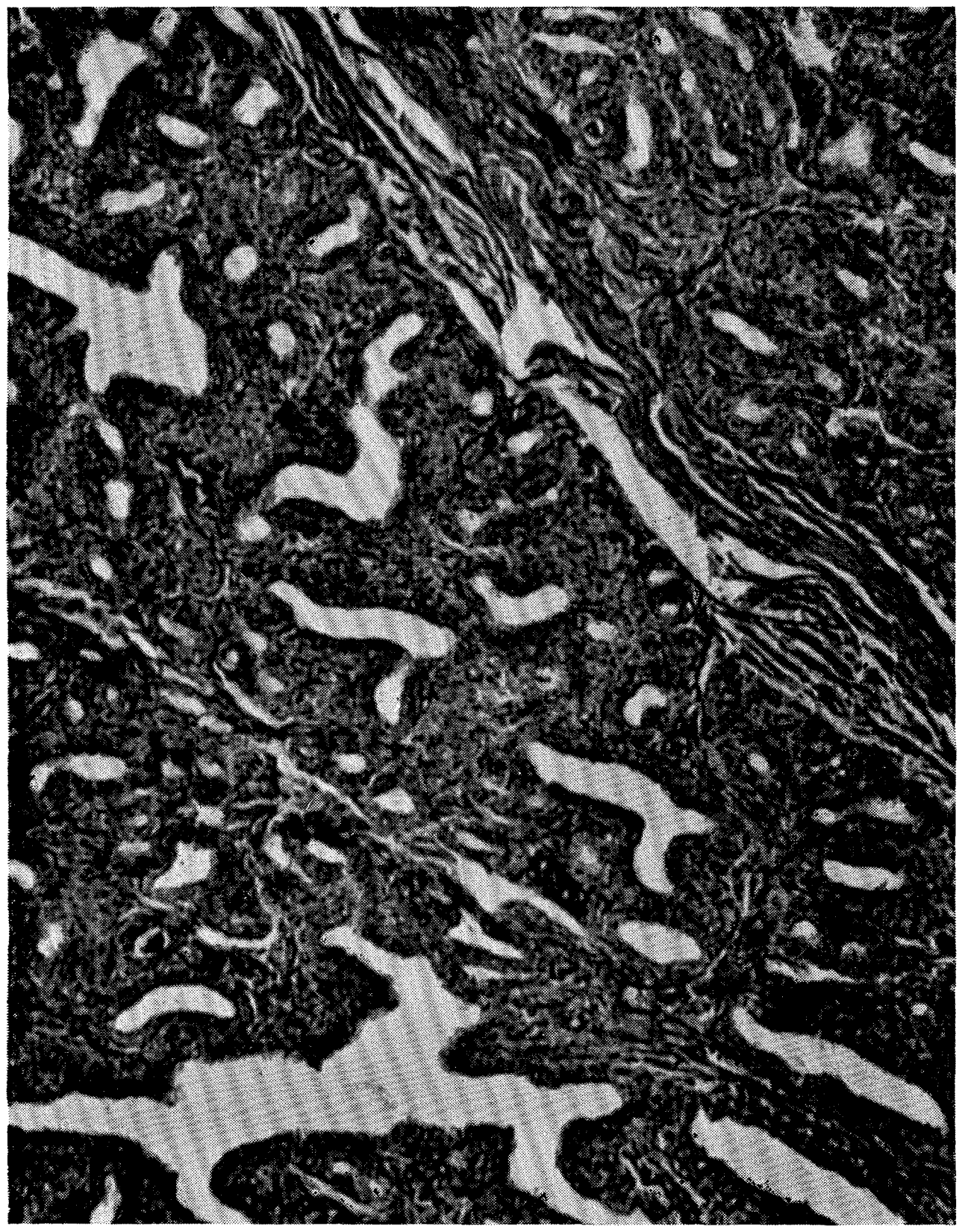

FIG. 85. Bartholin's gland: prepubertal. × 130.

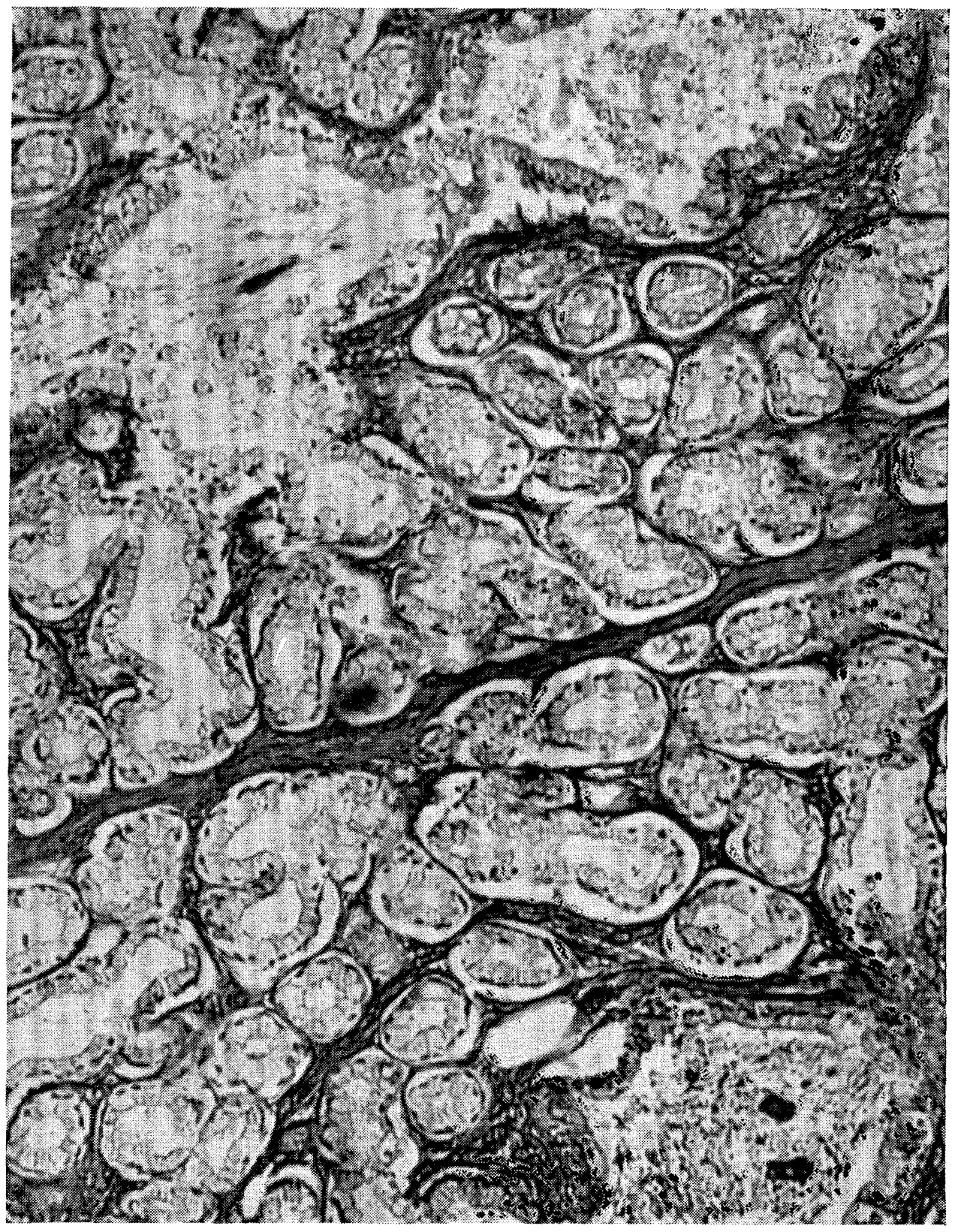

FIG. 87. Bartholin's gland at oestrus. × 130.

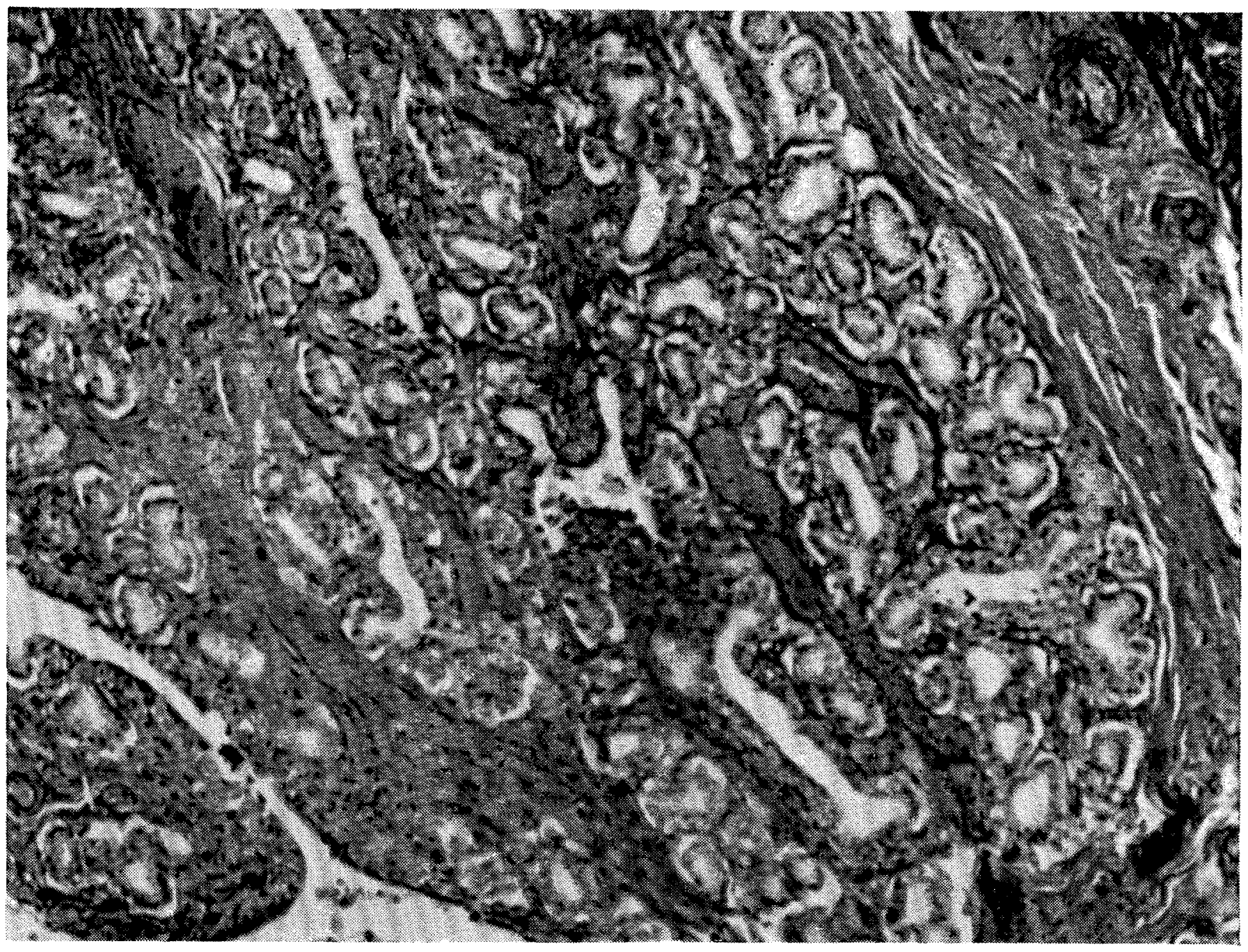

FIG. 86. Bartholin's gland at pro-oestrus. × 130.

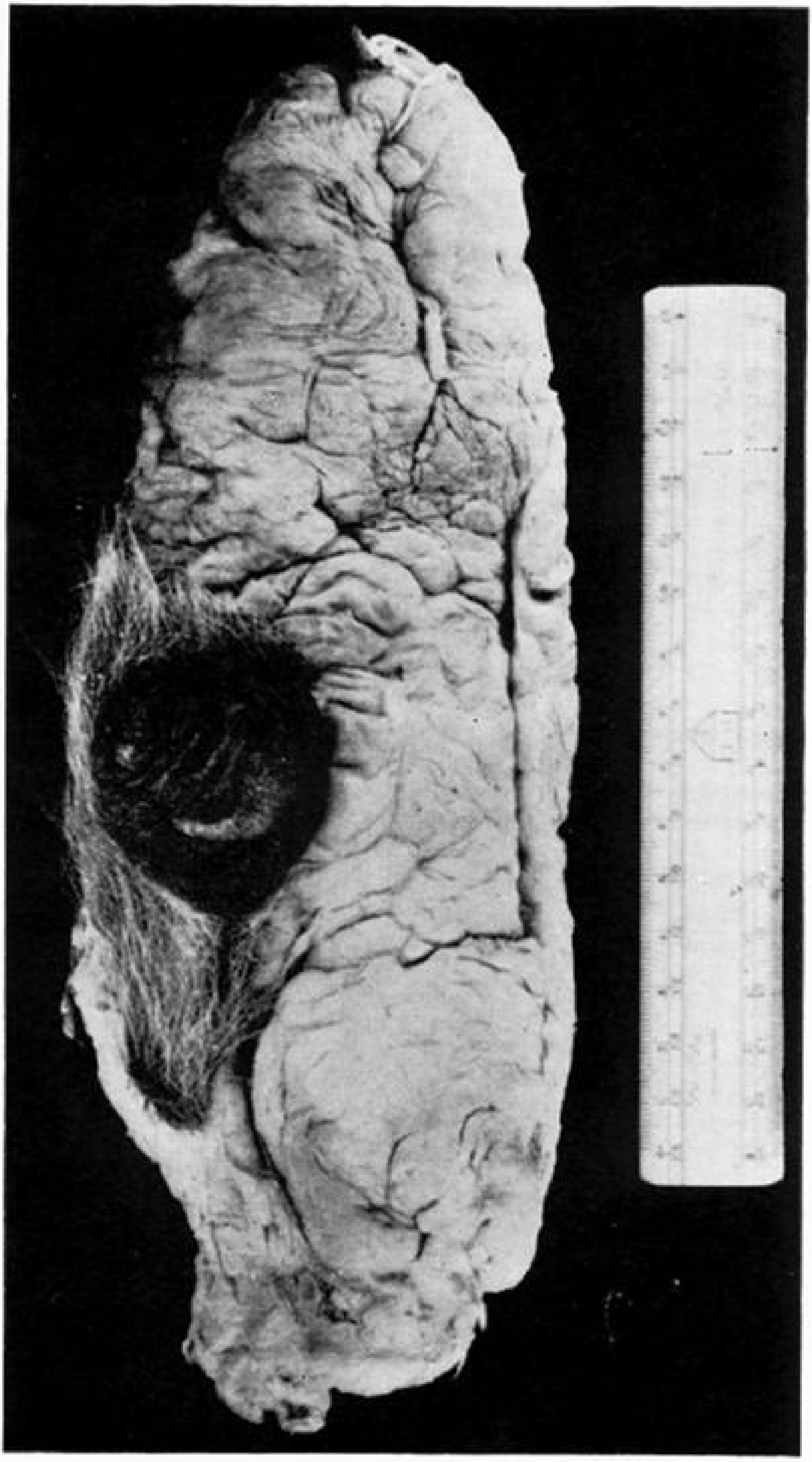

FIG. 37. Mammary gland during lactation (after fixation).

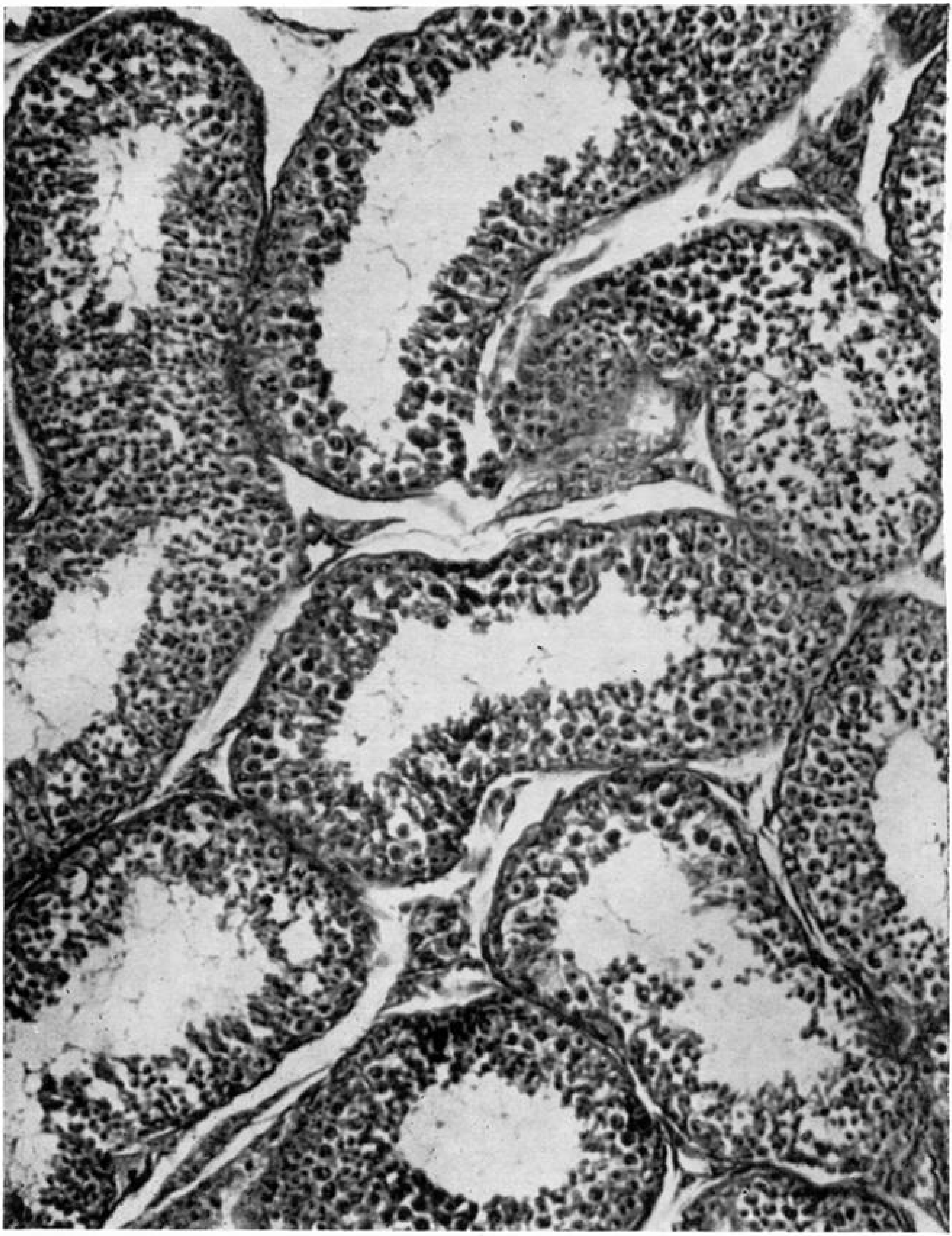

FIG. 38. Section of testis in inactive state. × 130.

FIG. 39. Section of testis in full activity. ×130.

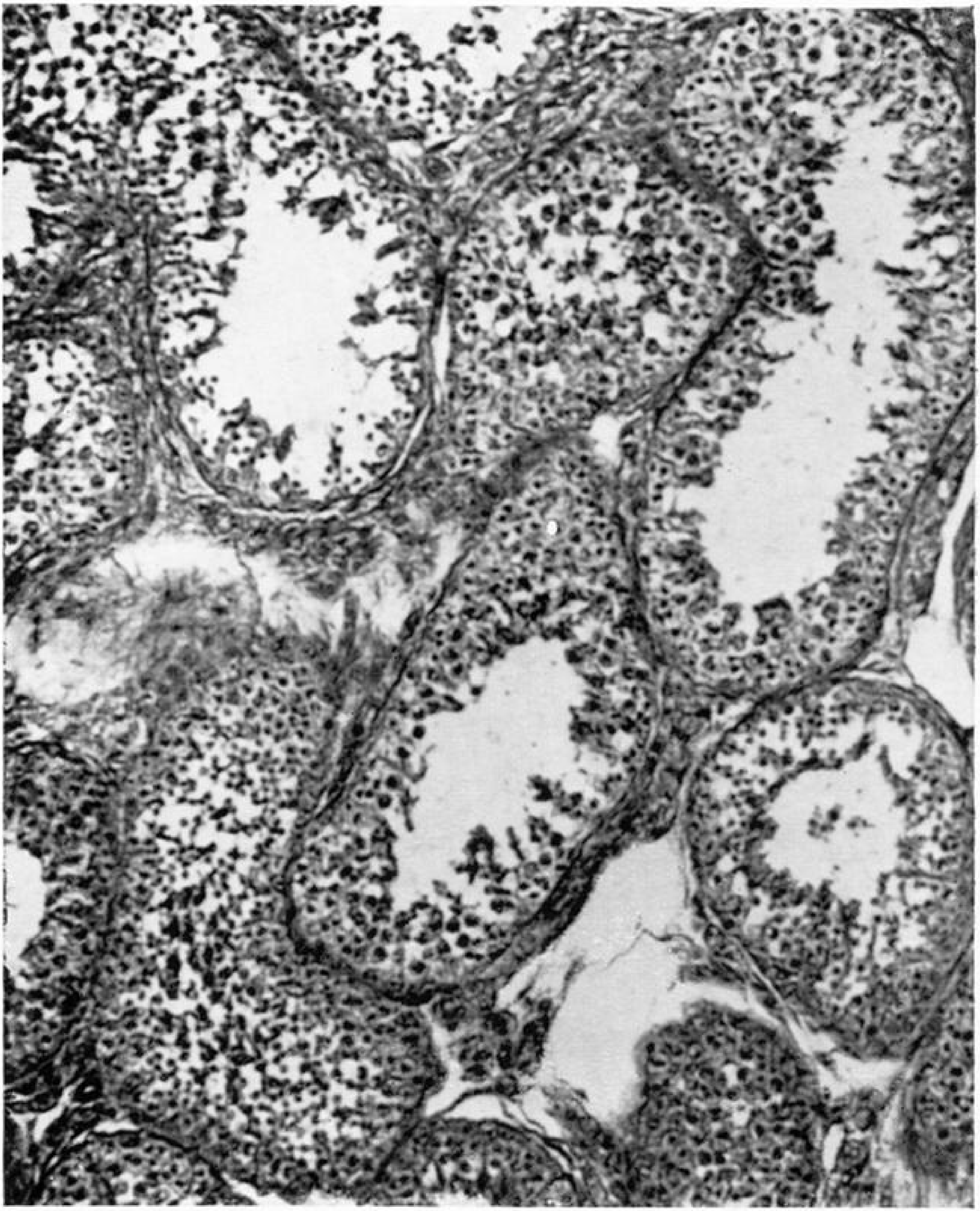

FIG. 40. Section of testis in intermediate activity. × 130.

FIG. 41. Section of epididymis in inactive state. × 130.

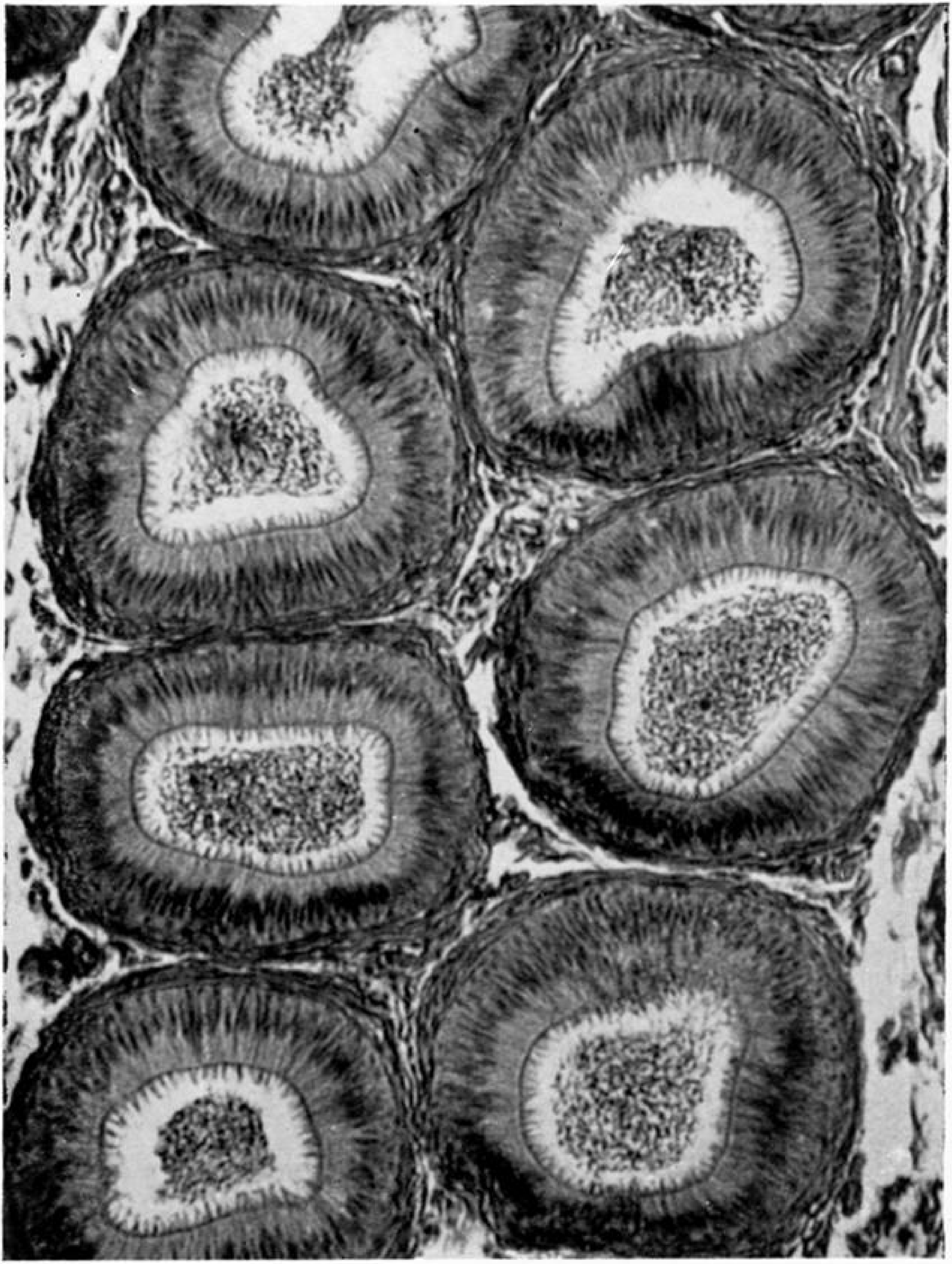

FIG. 42. Section of epididymis in full activity; tubules filled with sperm. × 130.

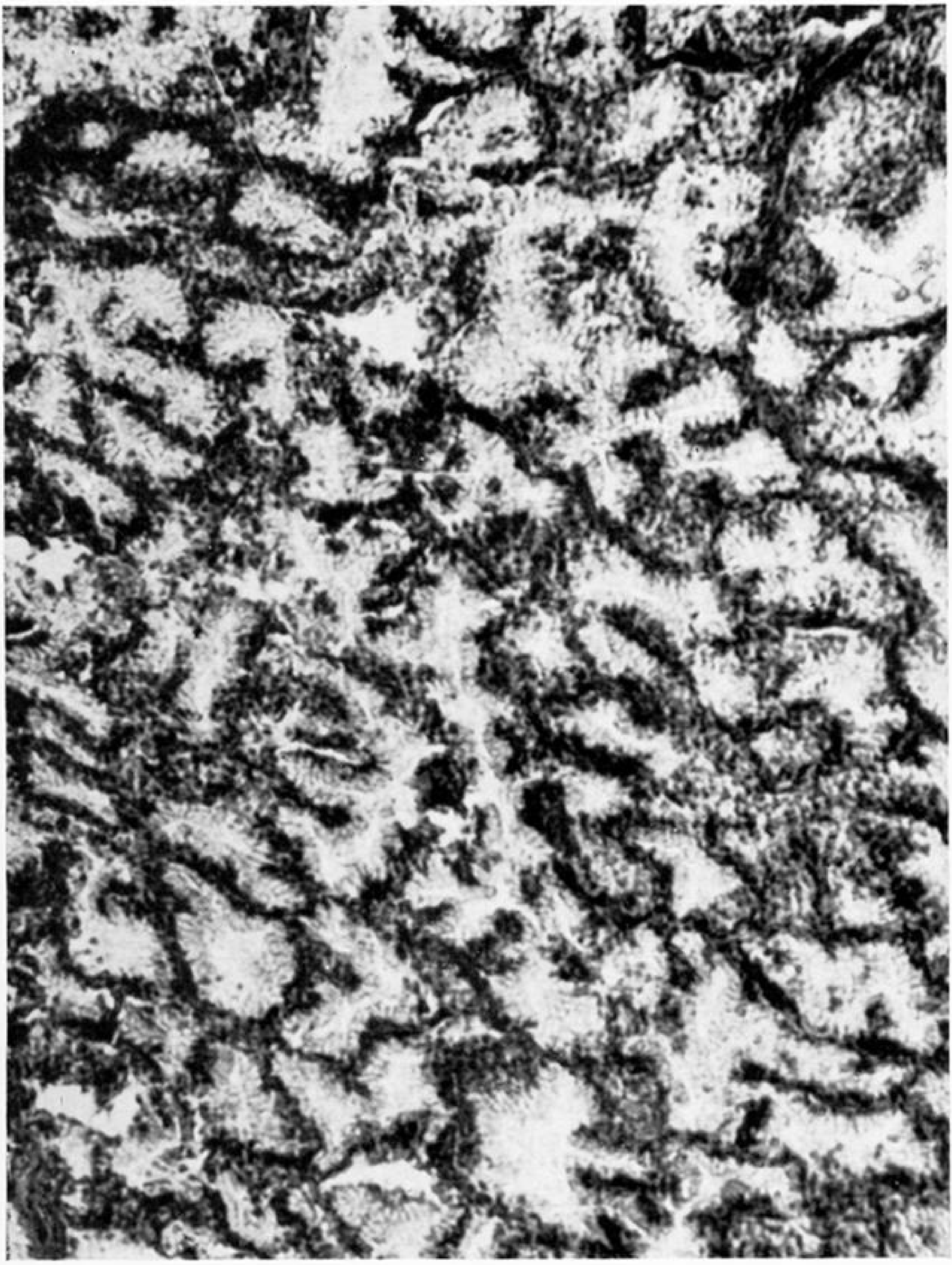

FIG. 43. Section of Cowper's gland, from a prepubertal animal. × 130.

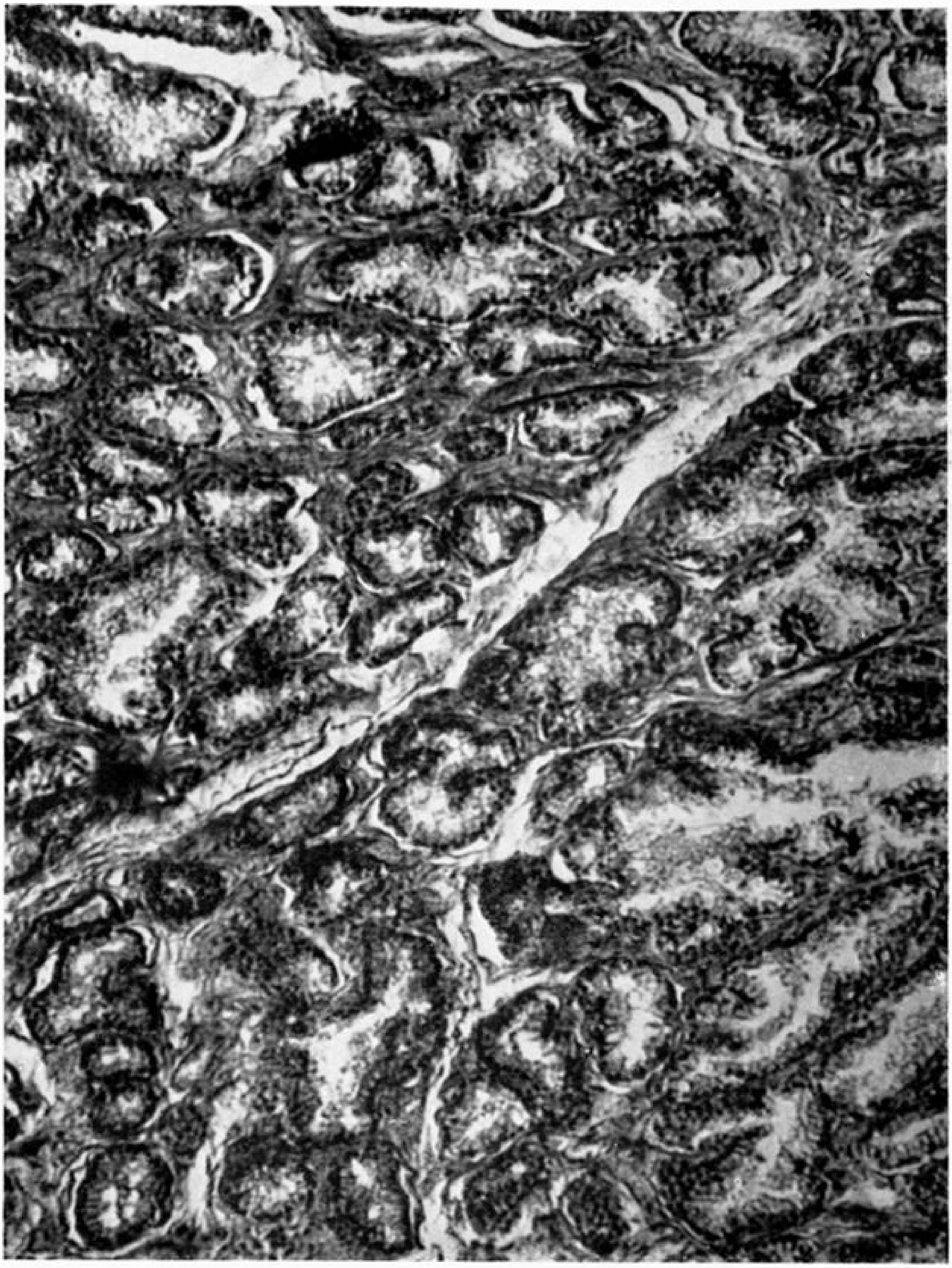

FIG. 44. Section of Cowper's gland showing small acini separated by wide bands of connective tissue. × 130.

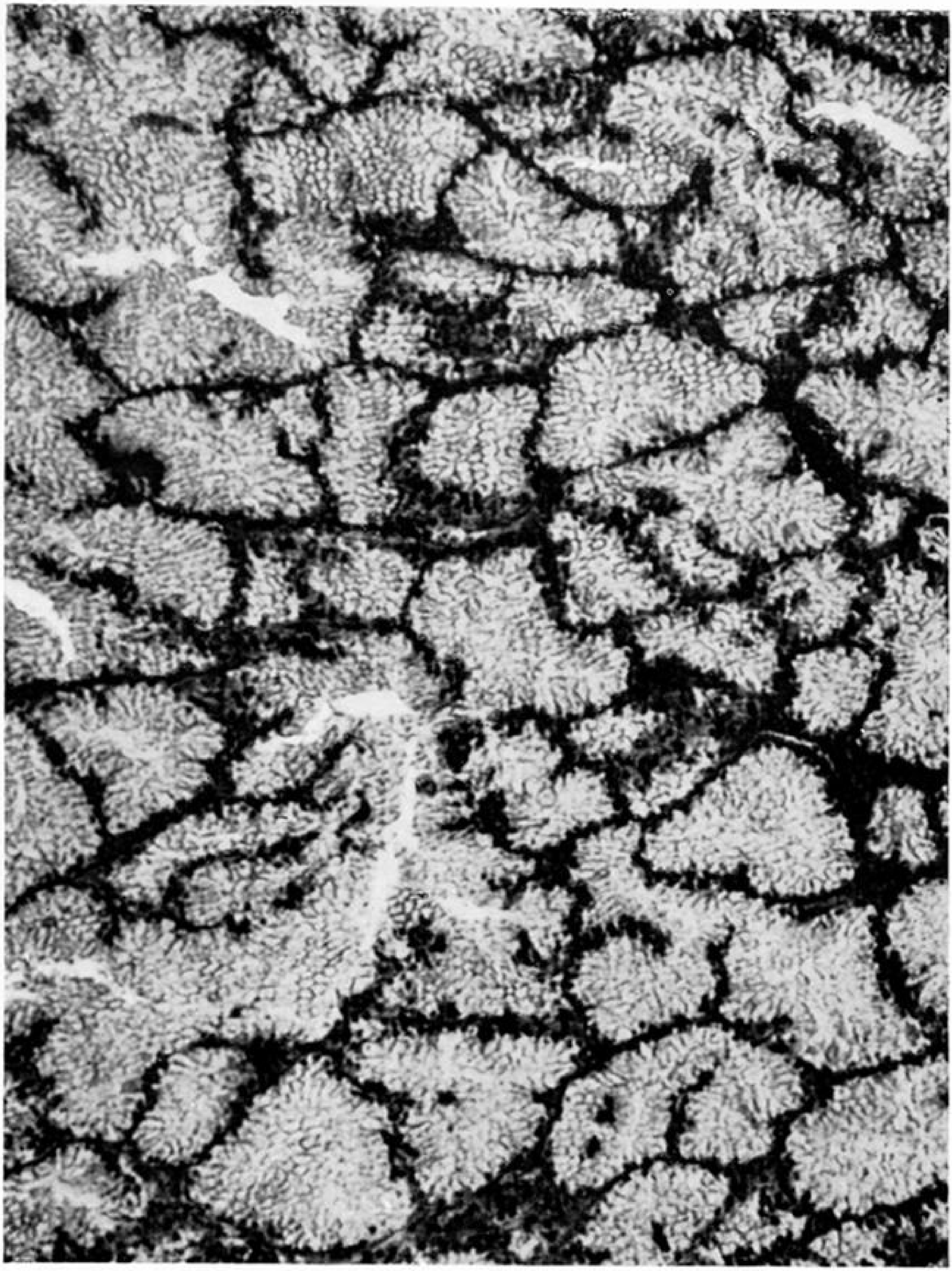

FIG. 45. Section of Cowper's gland showing closely packed acini filled with large cells. × 130.

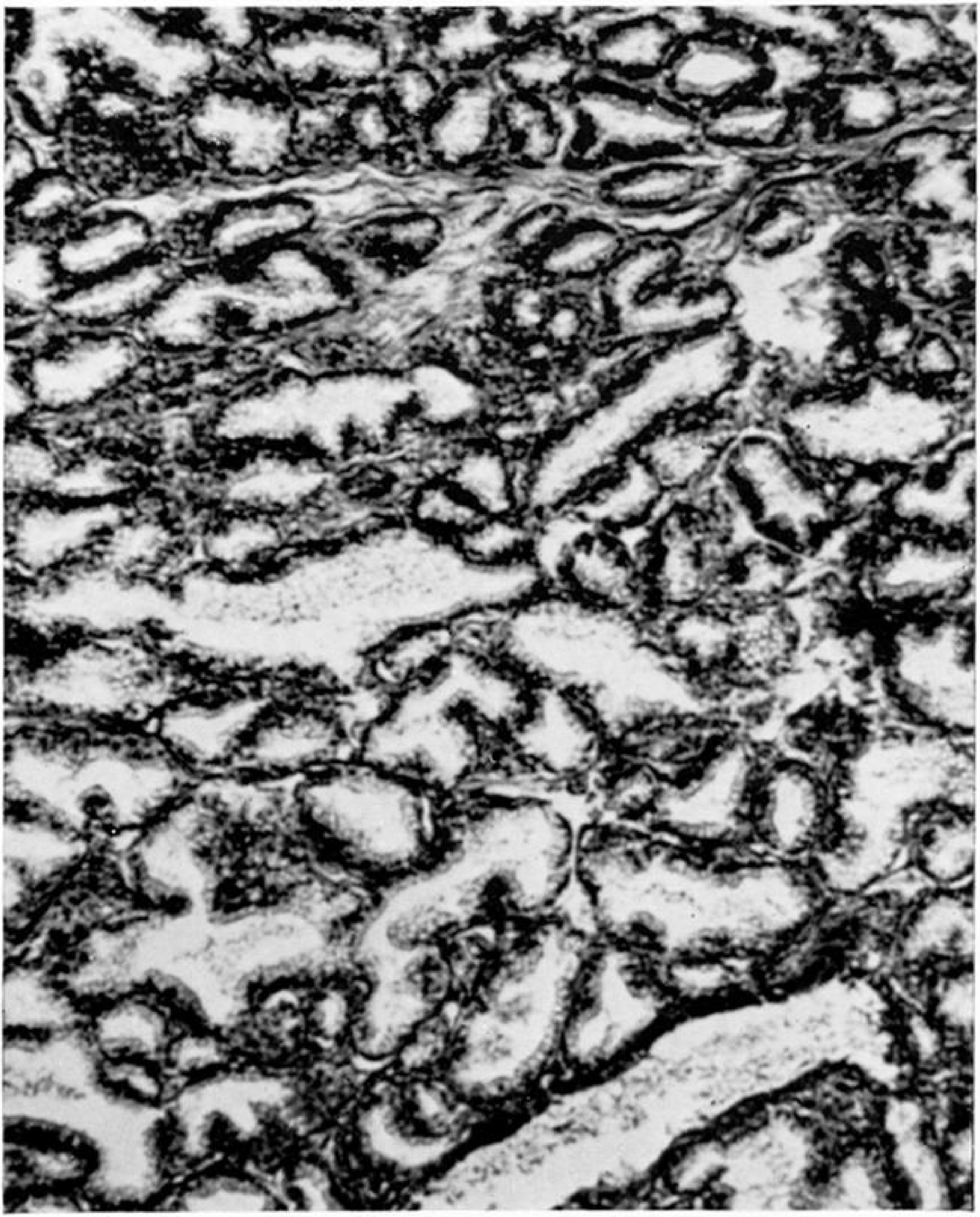

FIG. 46. Section of Cowper's gland: the commonest state found in the sexually mature animal: all the acini with lumina. × 130.

Fig. 47. Section of a small prostate. × 130.

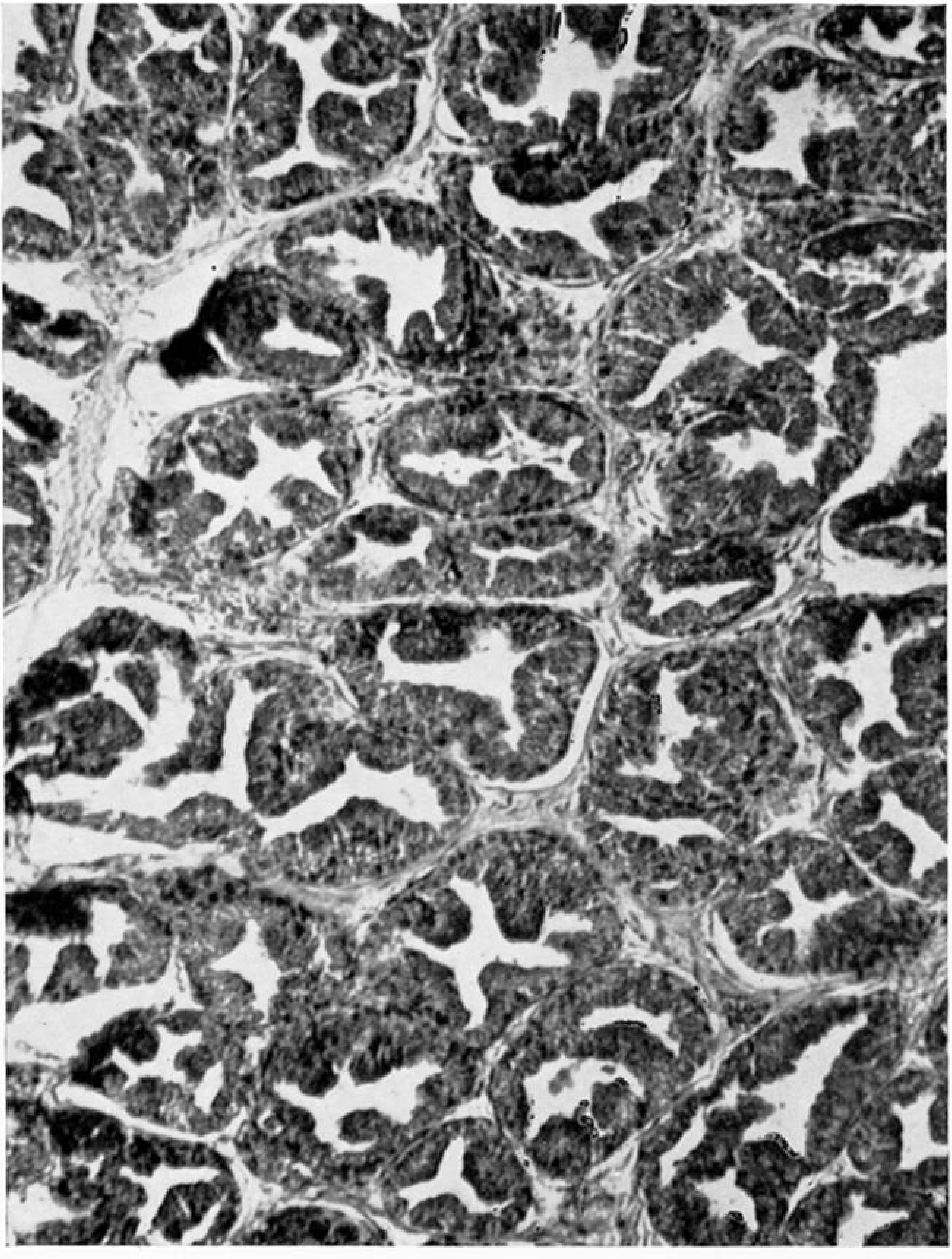

FIG. 48. Section of prostate in highest state of activity. × 130.

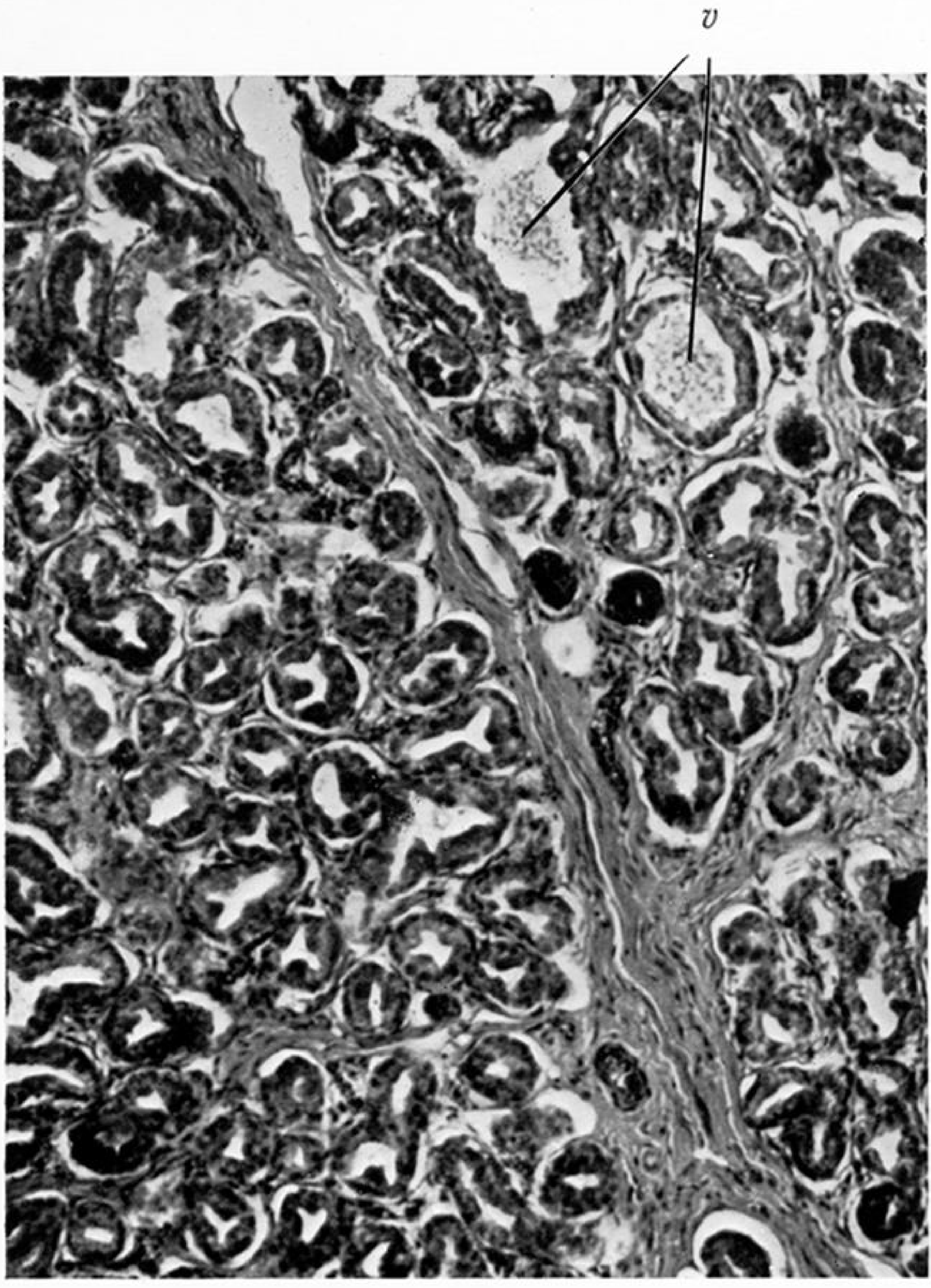

FIG. 49. Section of prostate showing increased vascularity. Vessels, *v*. × 130.

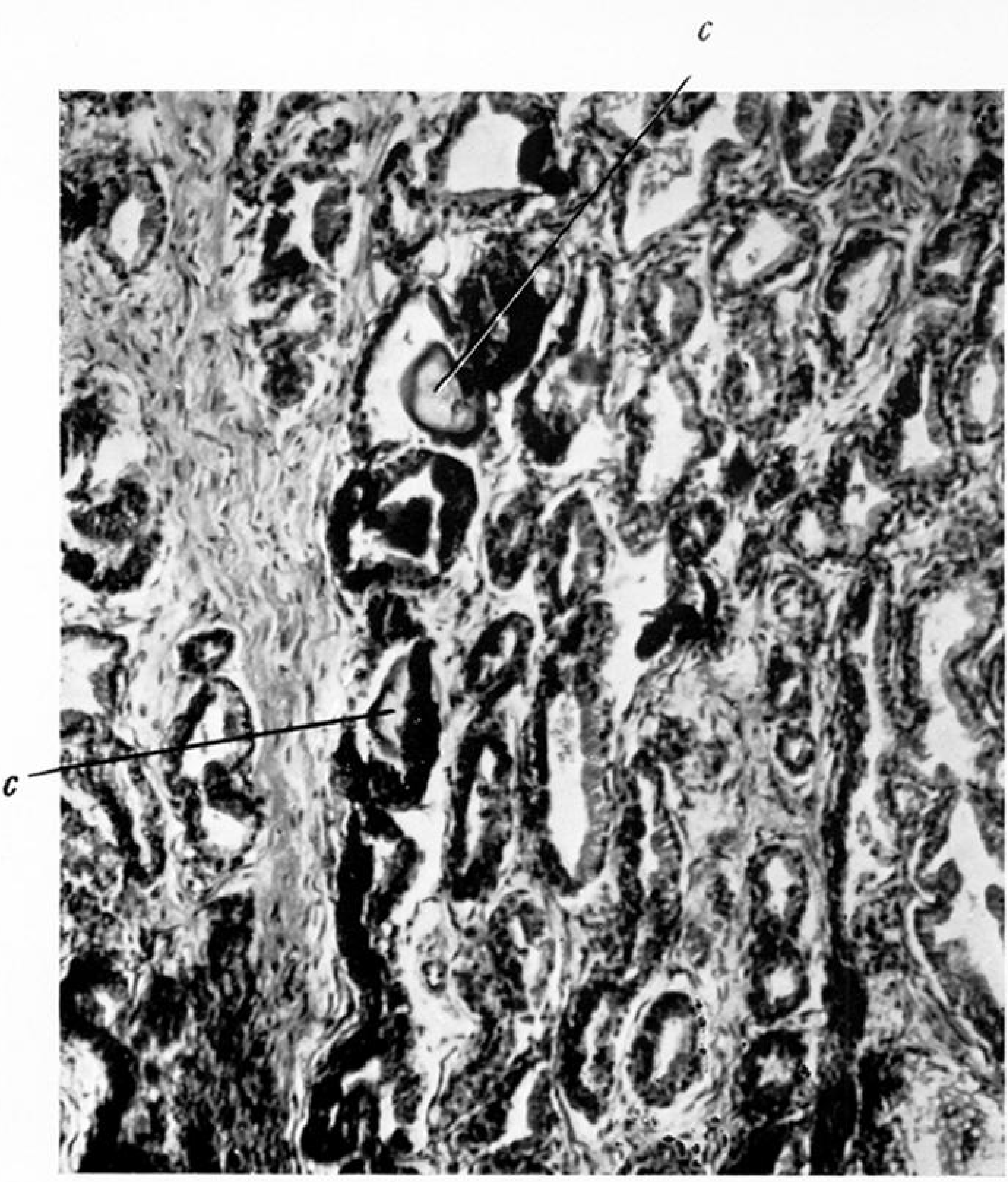

FIG. 50. Section of prostate showing concretions, *c*. × 130.

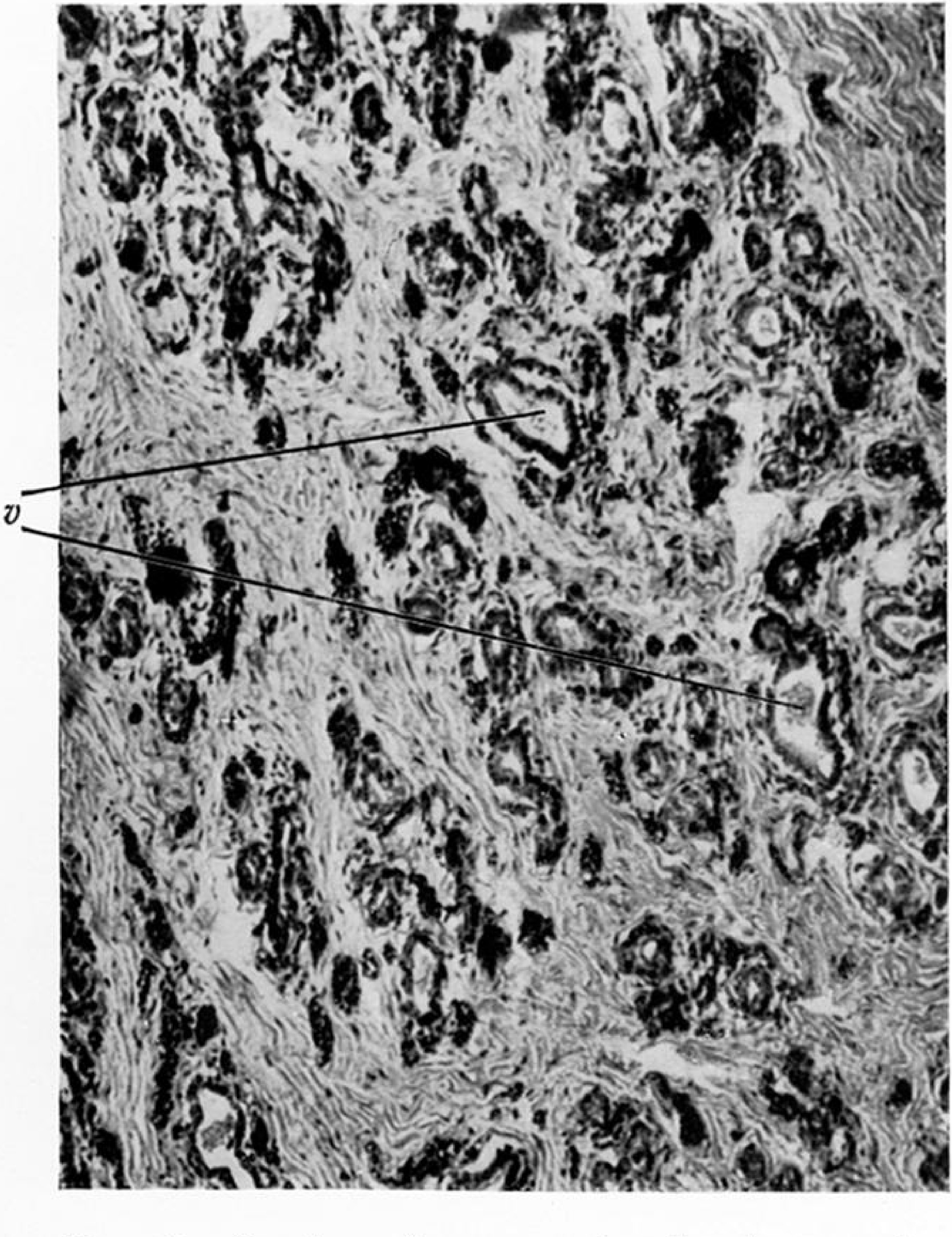

FIG. 51. Section of prostate showing increased vascularity. Vessels, *v*. × 130.

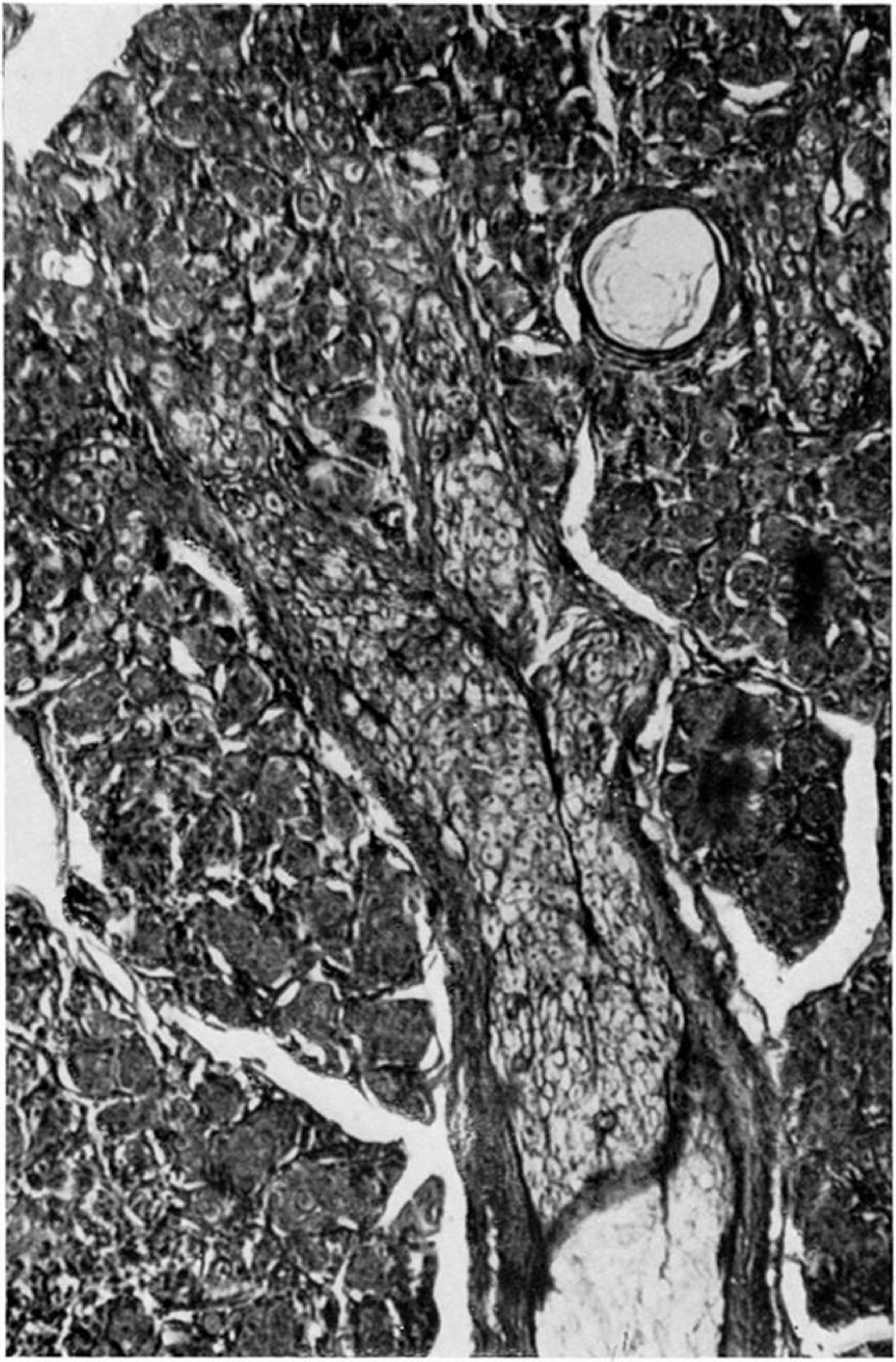

FIG. 52. Section of anal gland. The commencement of a duct, showing cells passing from the acini into the duct, and degenerating as they travel down it. ×130.

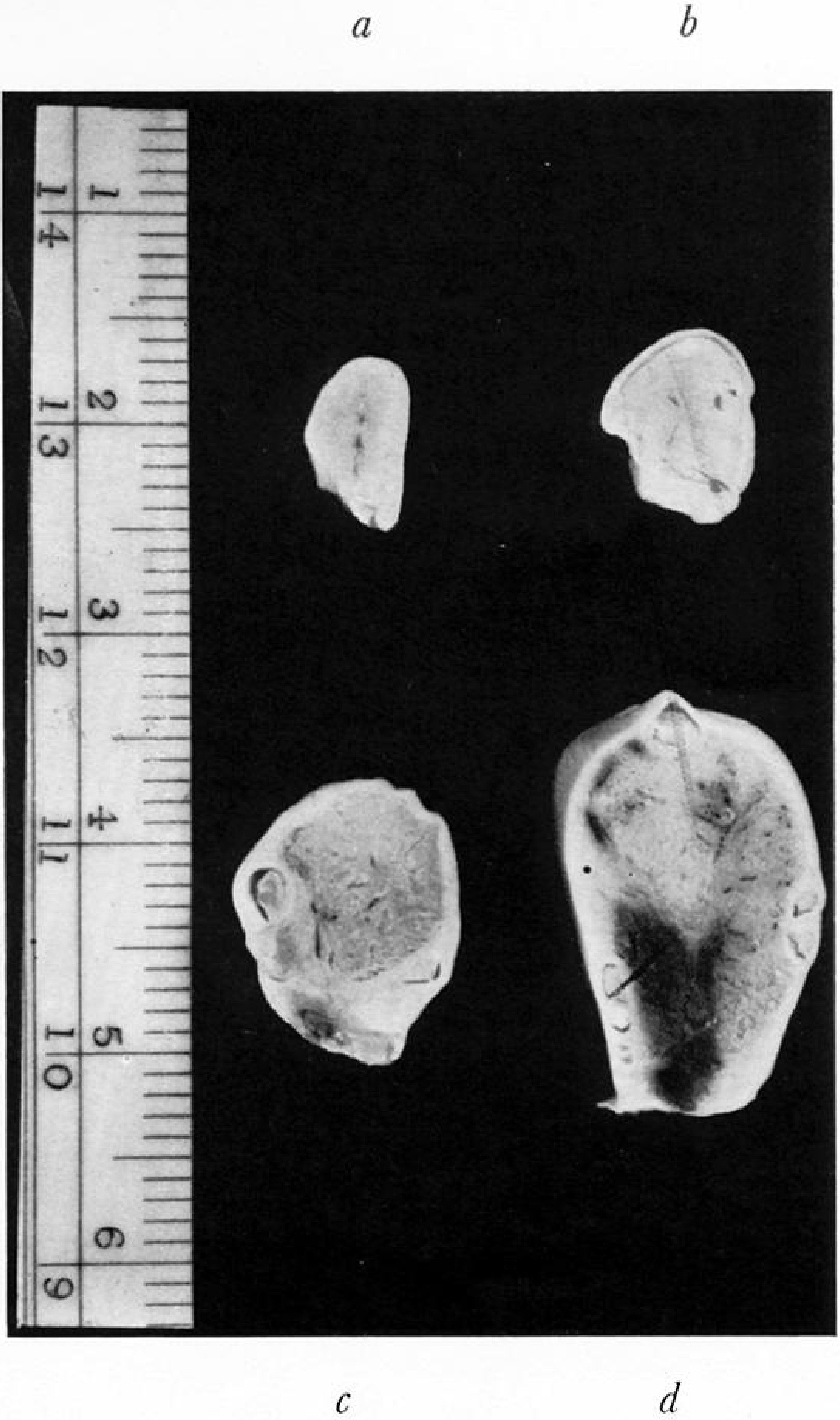

FIG. 53. Sections of ovary. *a*, prepubertal group A, no visible follicles. *b*, prepubertal group B, some visible follicles. *c*, adult in anoestrus: one large corpus luteum and two visible follicles. *d*, adult, pregnant. Two young corpora lutea (top and right) and one old one (bottom, dark in colour). Several visible follicles. Scale of cm.

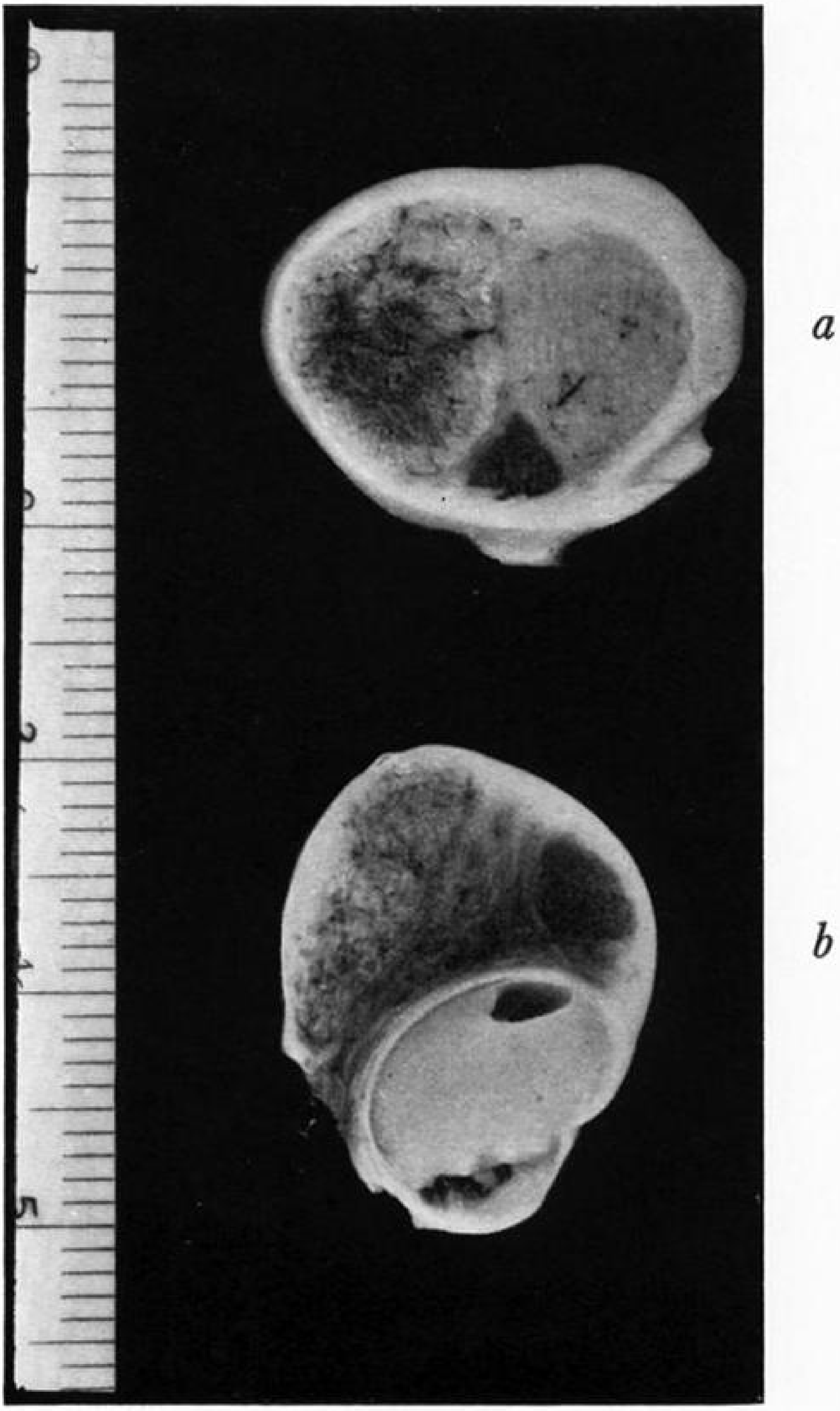

FIG. 54. Sections of ovary. *a*, pregnant: corpora lutea of three ages: the youngest on the right, the oldest below. *b*, at oestrus: two corpora lutea of different ages, the youngest on the left, and, below, a ripe follicle. Scale of cm.

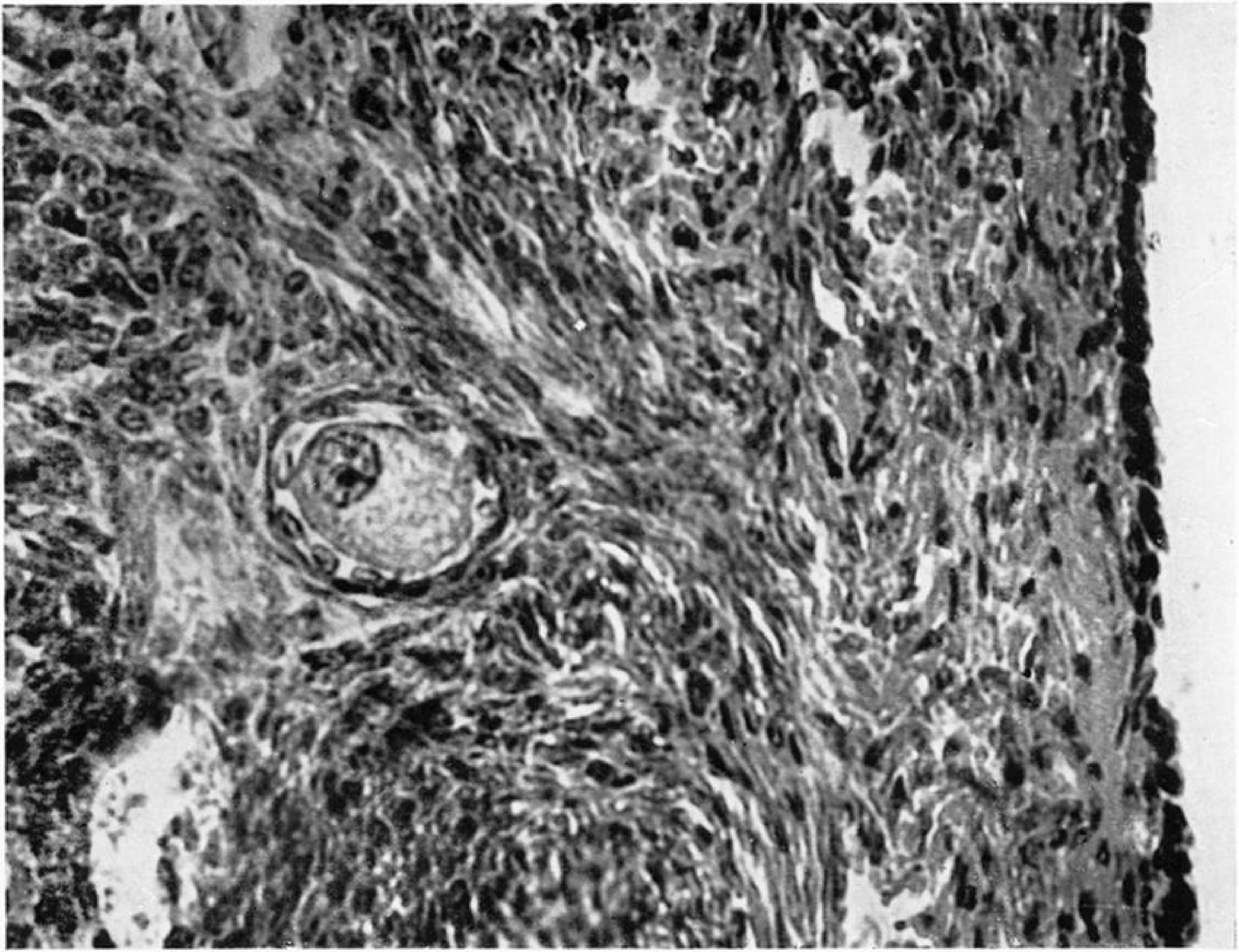

FIG. 56. A follicle early in the first stage of growth. The follicular epithelium consists of a single layer of flattened cells. The surface of the ovary, with the germinal epithelium, on the right. × 430.

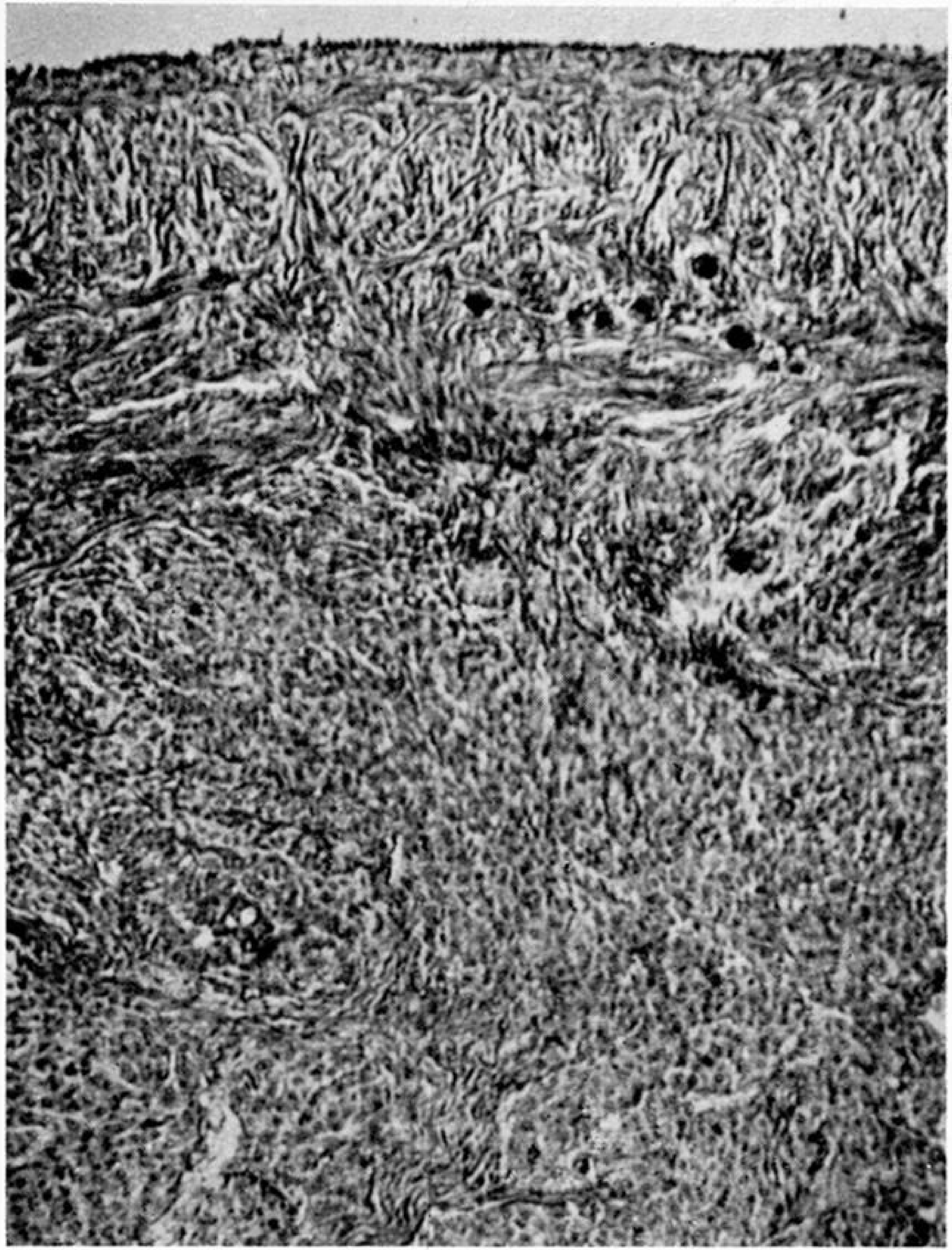

FIG. 55. Section of part of the ovary showing cortex and peripheral stroma. The dearth of follicles is typical. × 130.

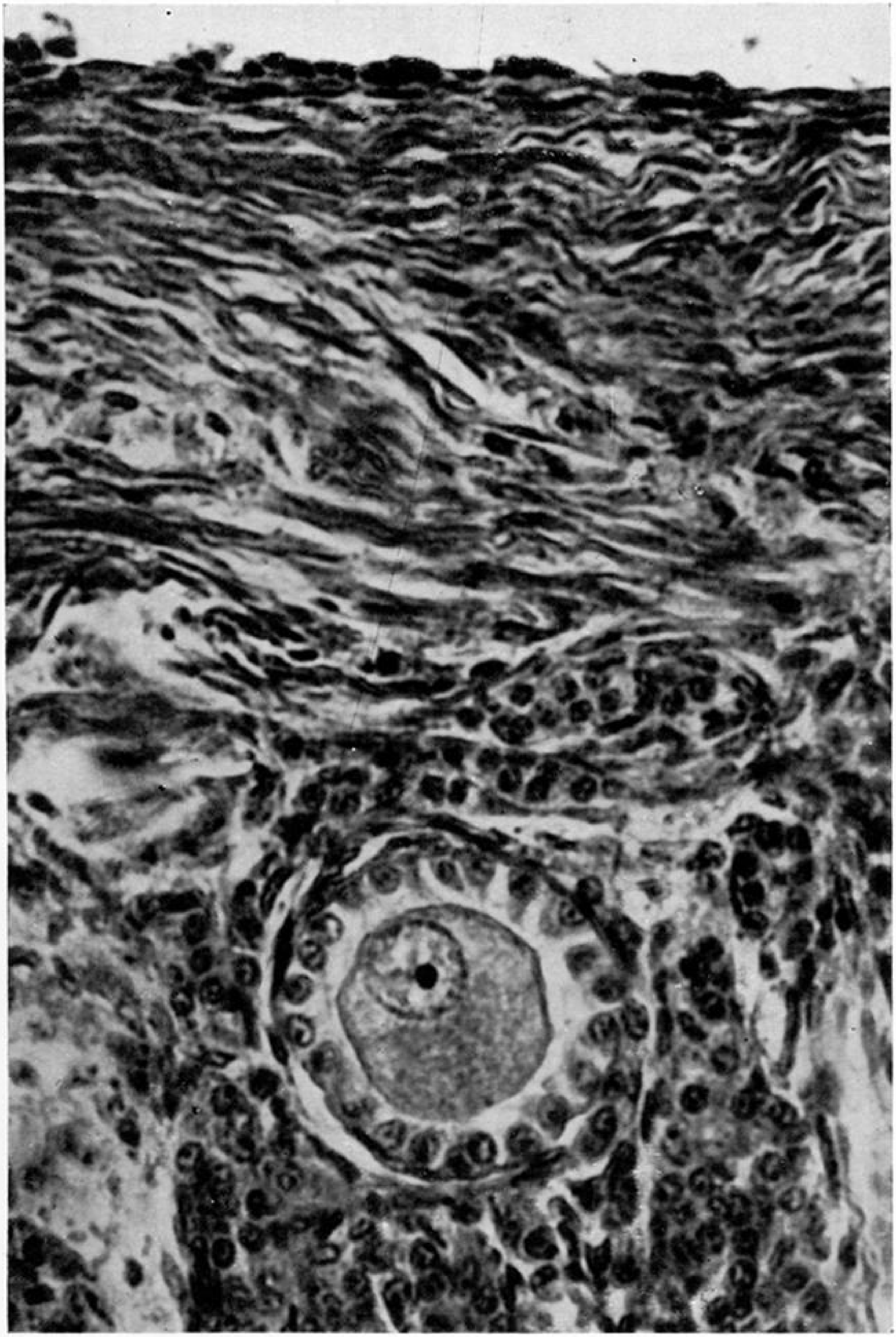

FIG. 57. Follicle late in the first stage of growth. The follicular epithelium consists of a single layer of cubical cells. Surface of the ovary above. × 430.

FIG. 58. A follicle in the second stage of growth. The follicular epithelium consists of two layers of cells. The follicle lies in the peripheral stroma, just internal to the cortex. × 130.

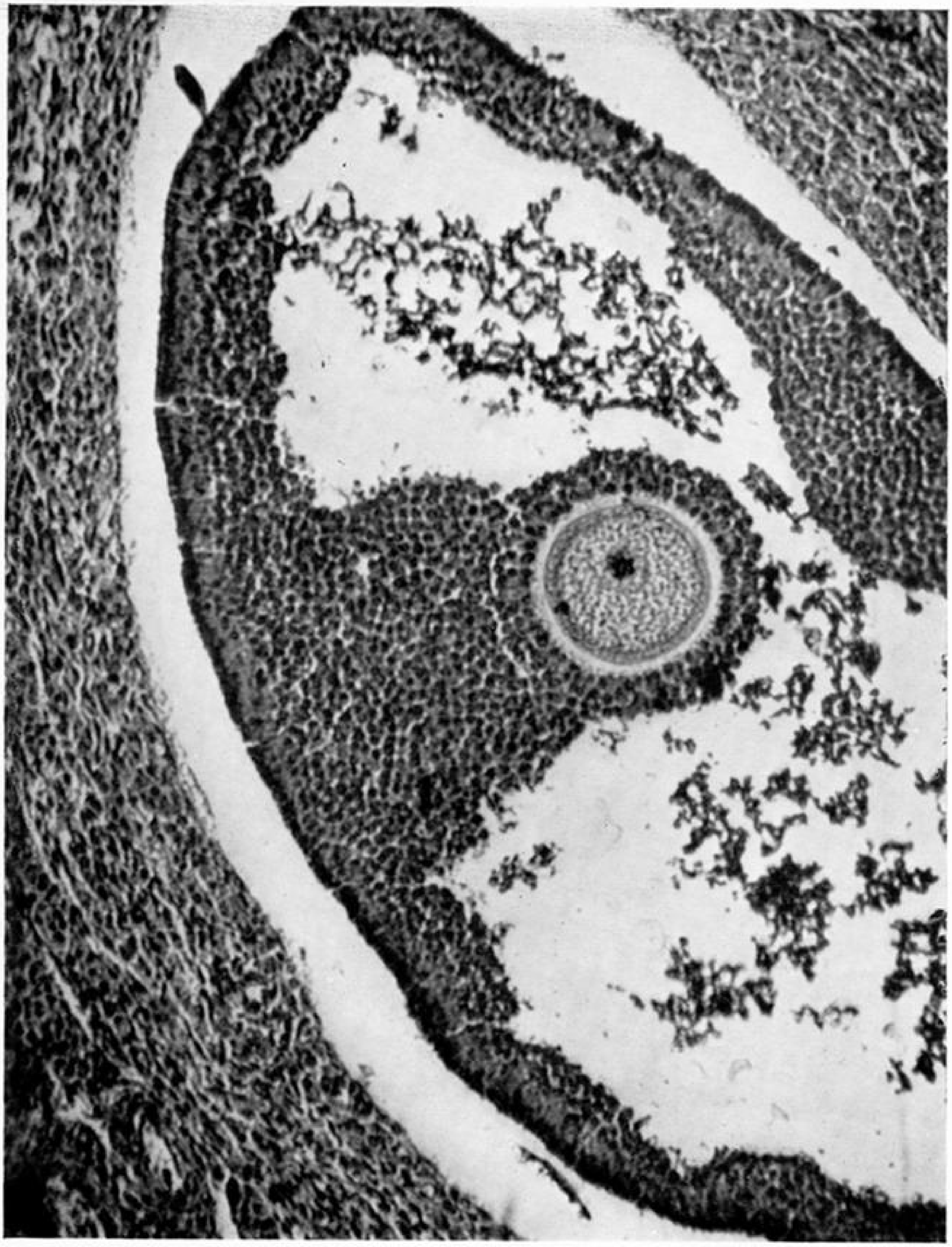

FIG. 59. A follicle early in the third stage of growth, with the formation of the antrum begun. The shrinkage of the epithelium from the follicular wall is due to fixation. The antrum contains coagulated liquor folliculi. × 130.

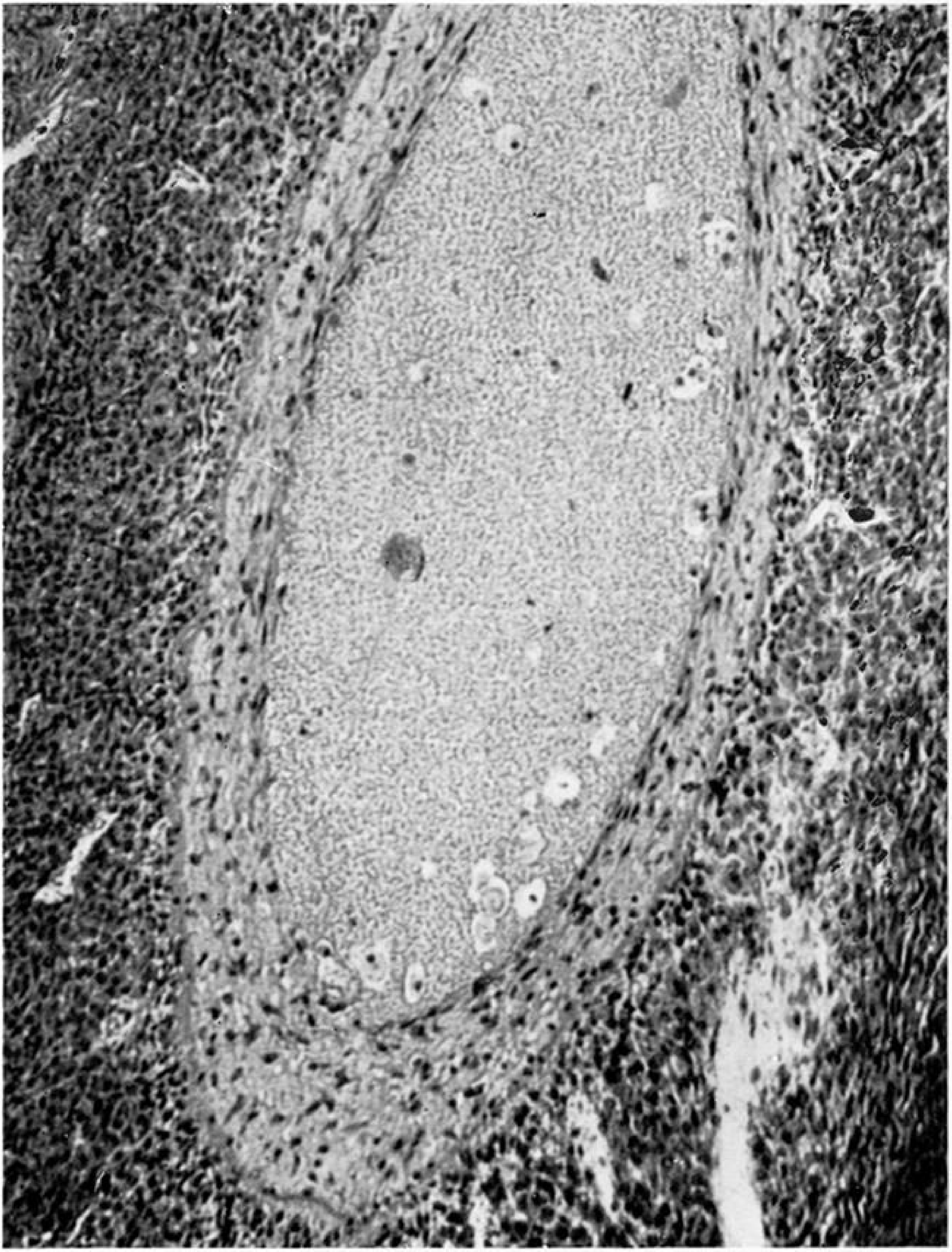

FIG. 60. A follicle in early atresia, with degenerate epithelium and central coagulum. × 130.

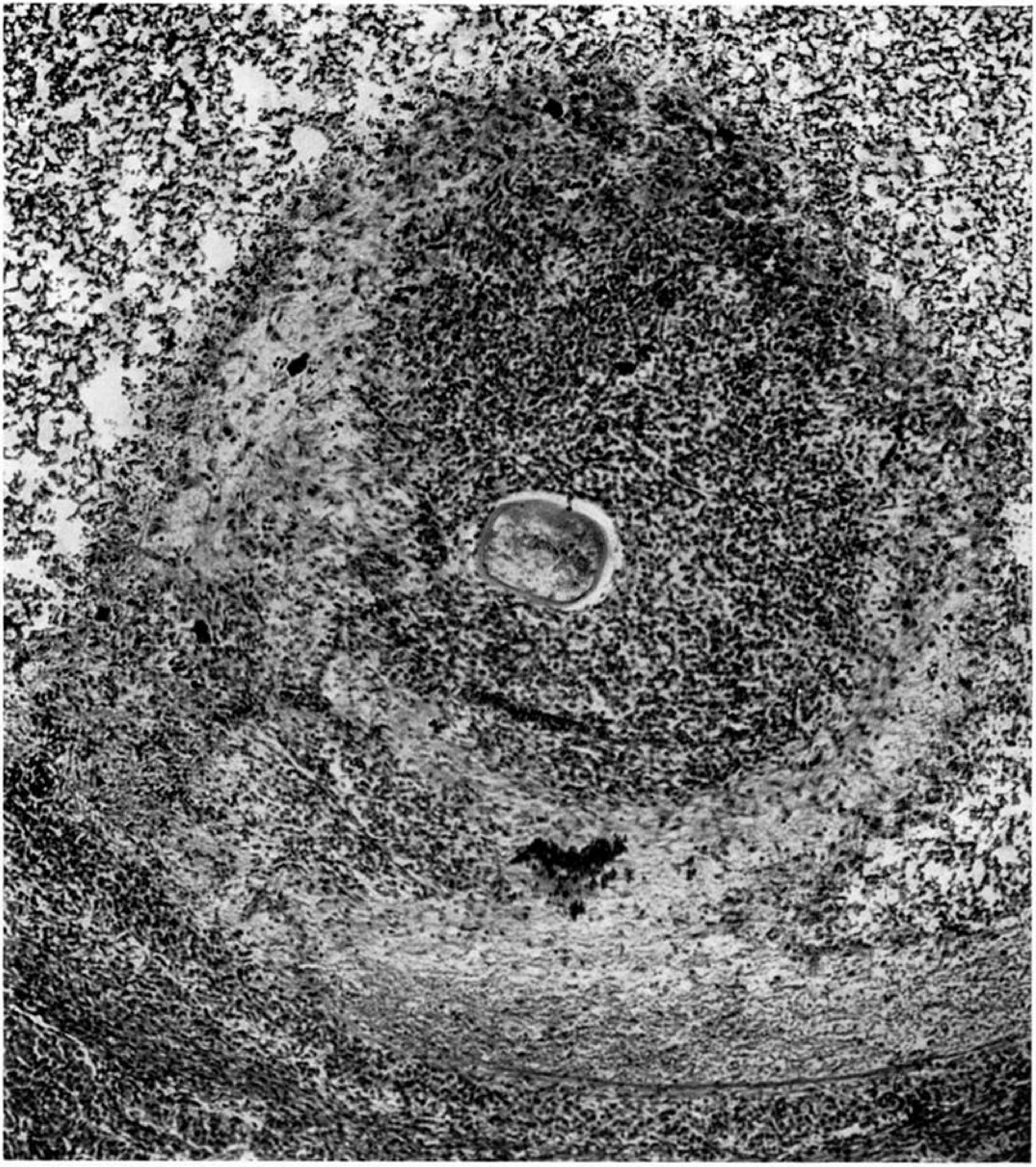

FIG. 61. Atresia in a follicle with a large antrum. The degenerate cumulus with remains of the ovum. The antrum is filled with coagulum. × 93.

Fig. 62. An atretic follicle completely filled by invading connective tissue: remains of the ovum still conspicuous. × 93.

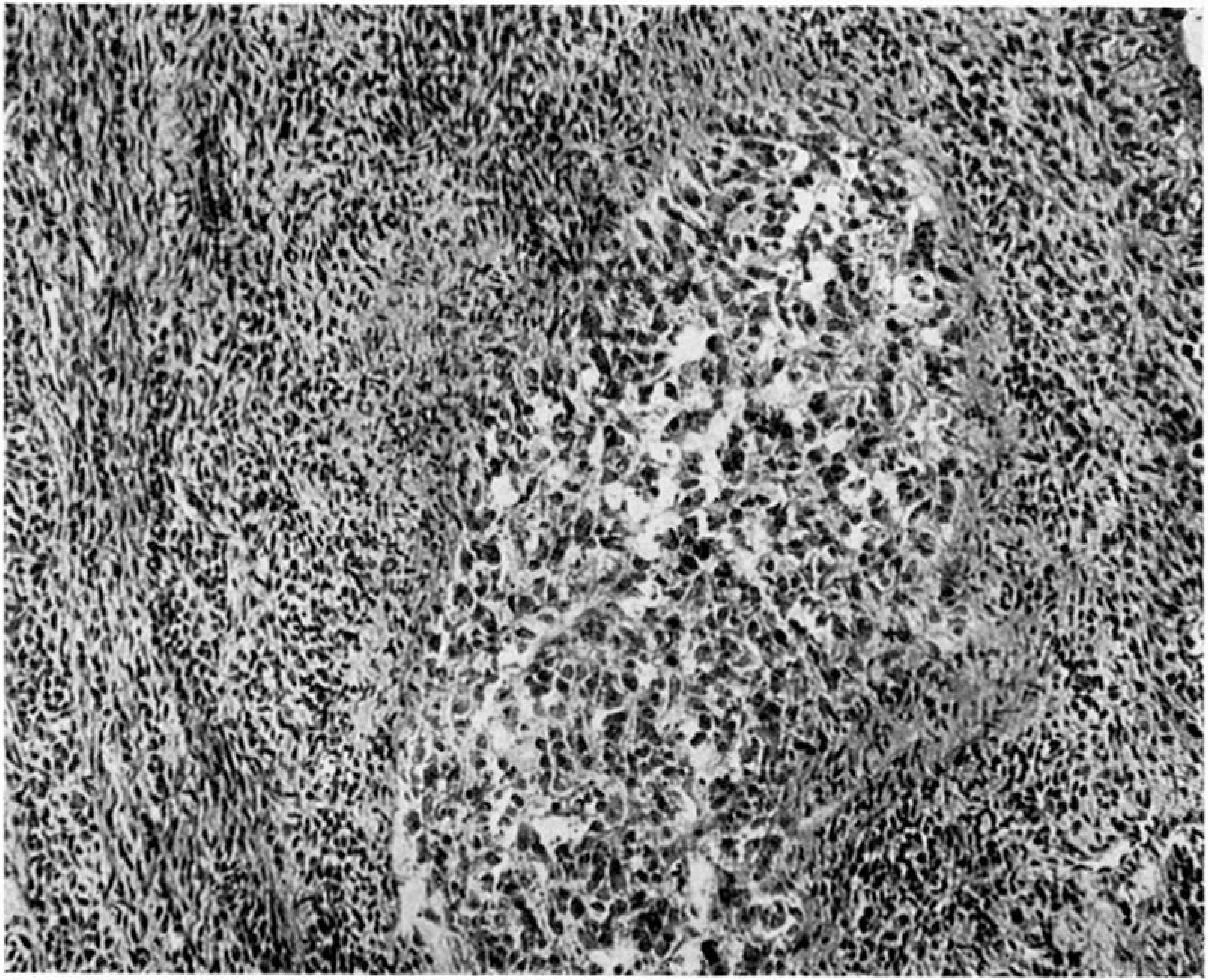

FIG. 63. Luteal atresia in a prepubertal animal. ×130.

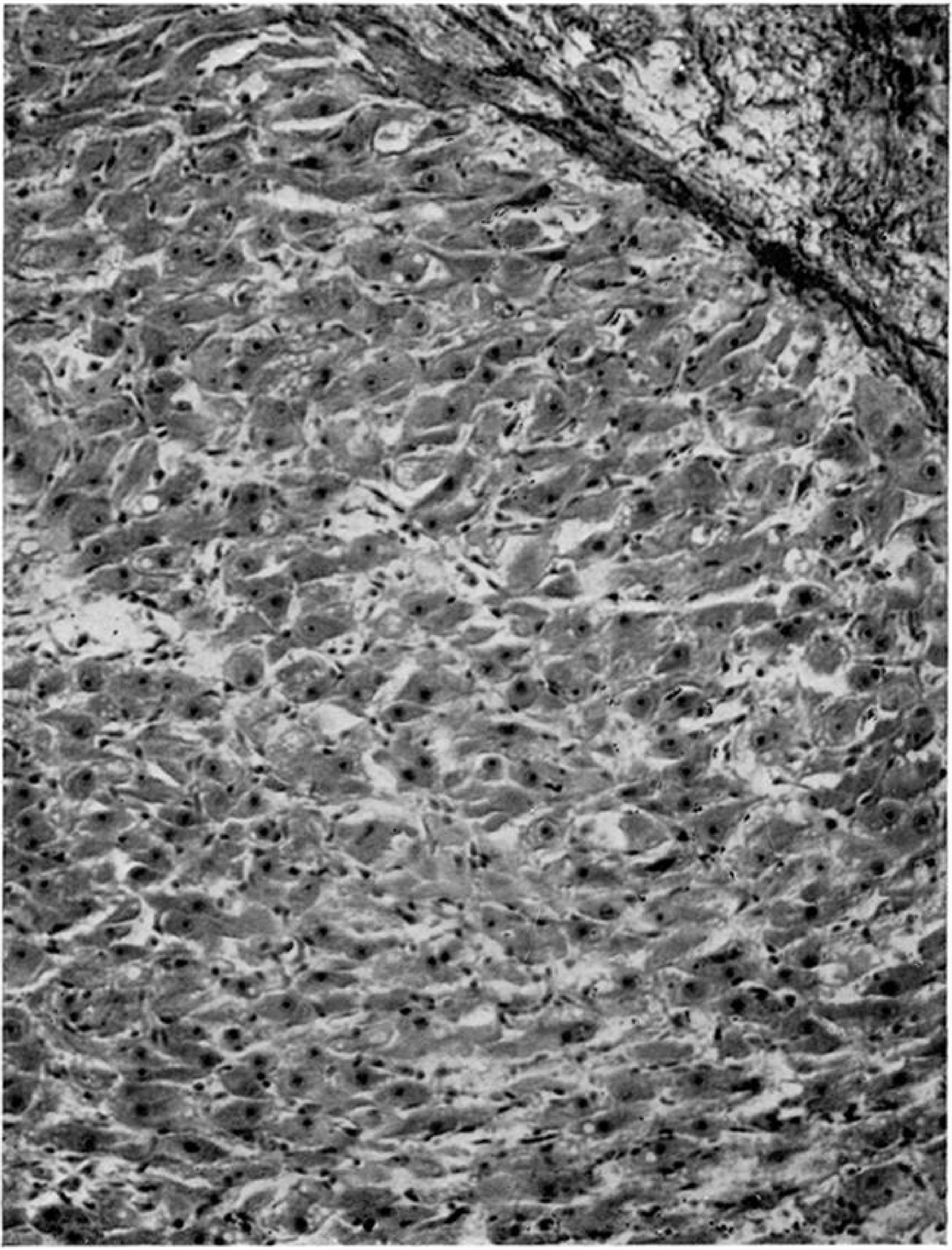

FIG. 64. Part of a very young corpus luteum. A portion of the central clot of fibrin is seen at the top right-hand corner. ×130.

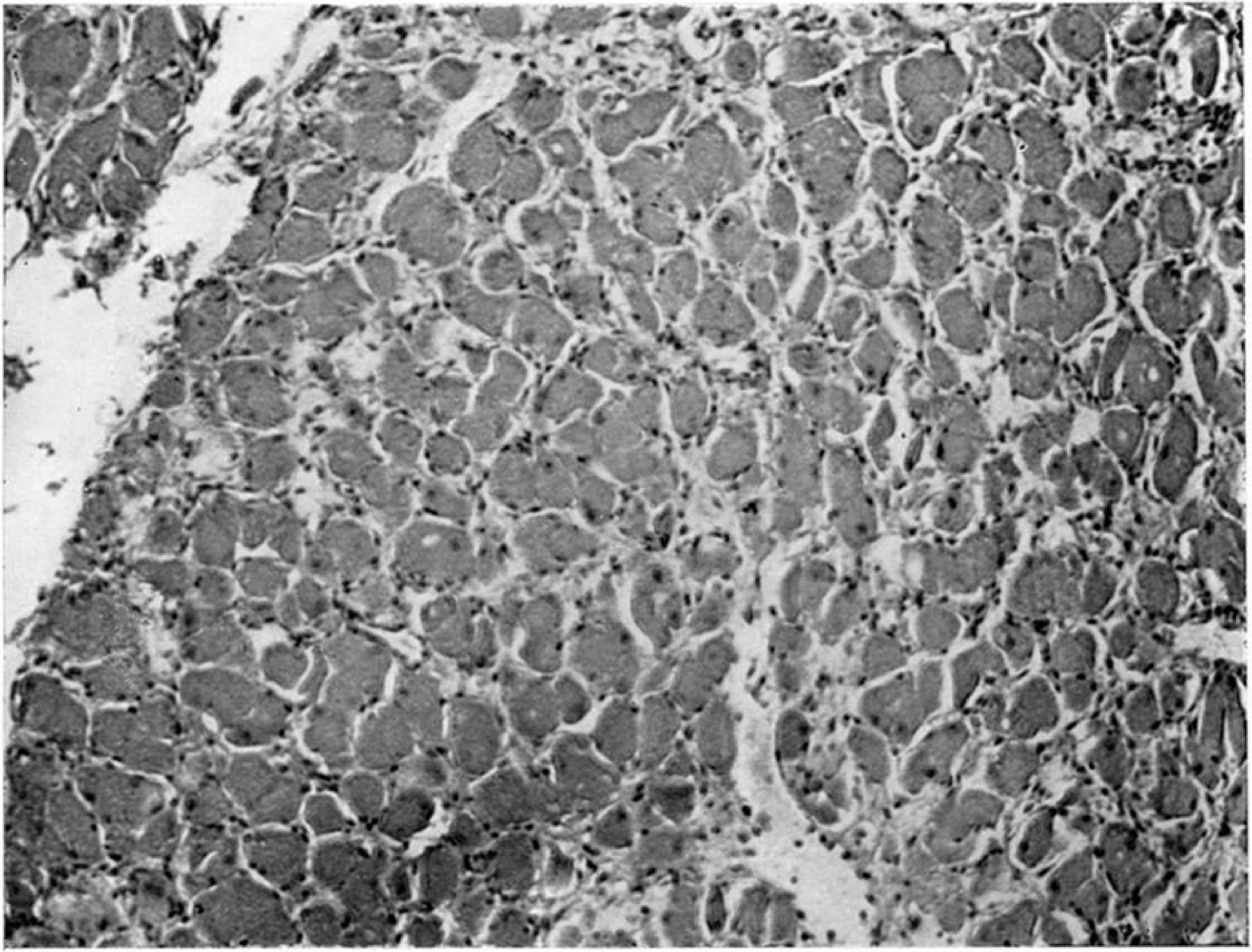

FIG. 65. Corpus luteum in early pregnancy. Part of the central space, from which the clot has been resorbed, is shown. ×130.

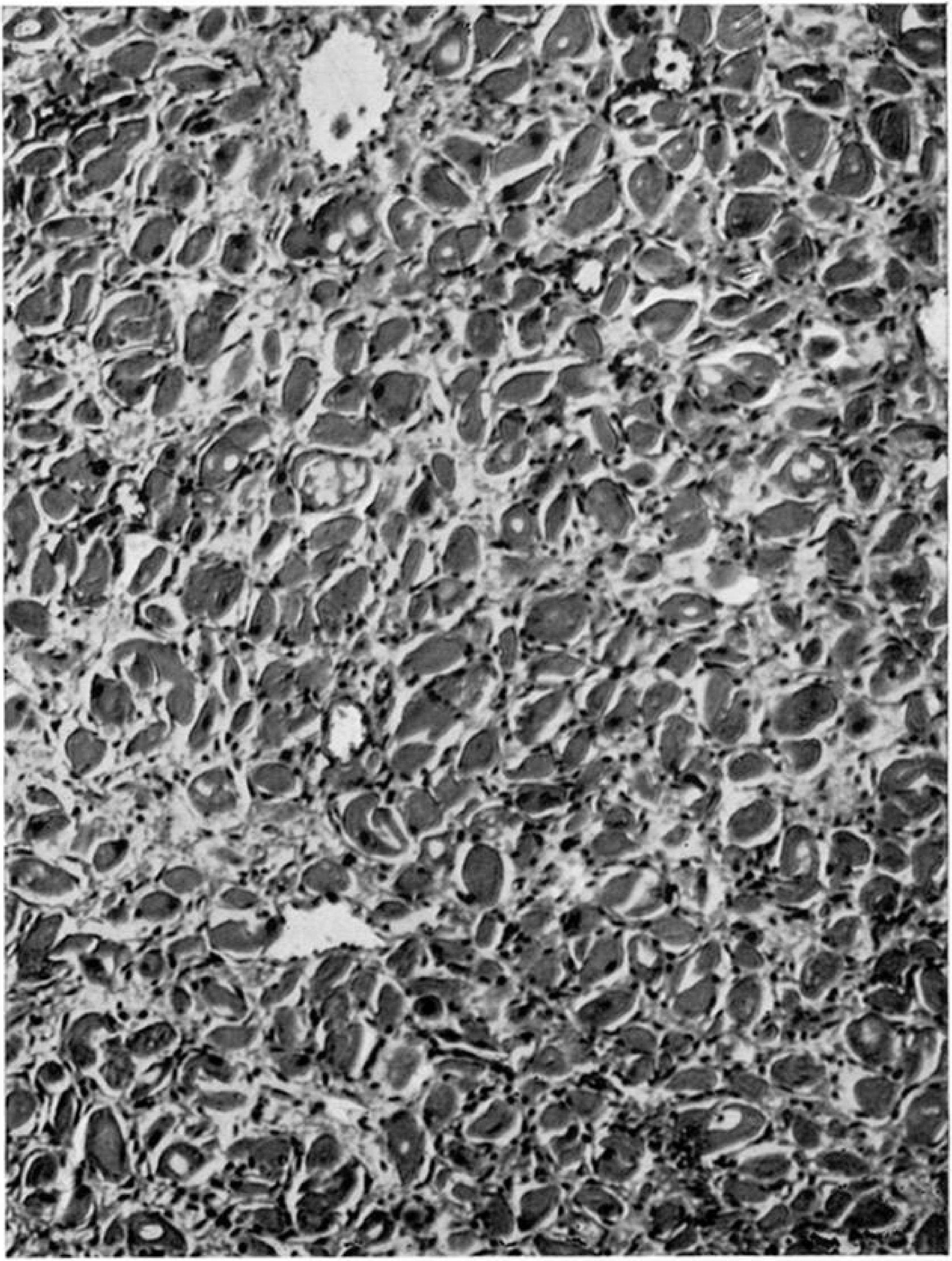

FIG. 66. Corpus luteum at about mid-pregnancy. × 130.

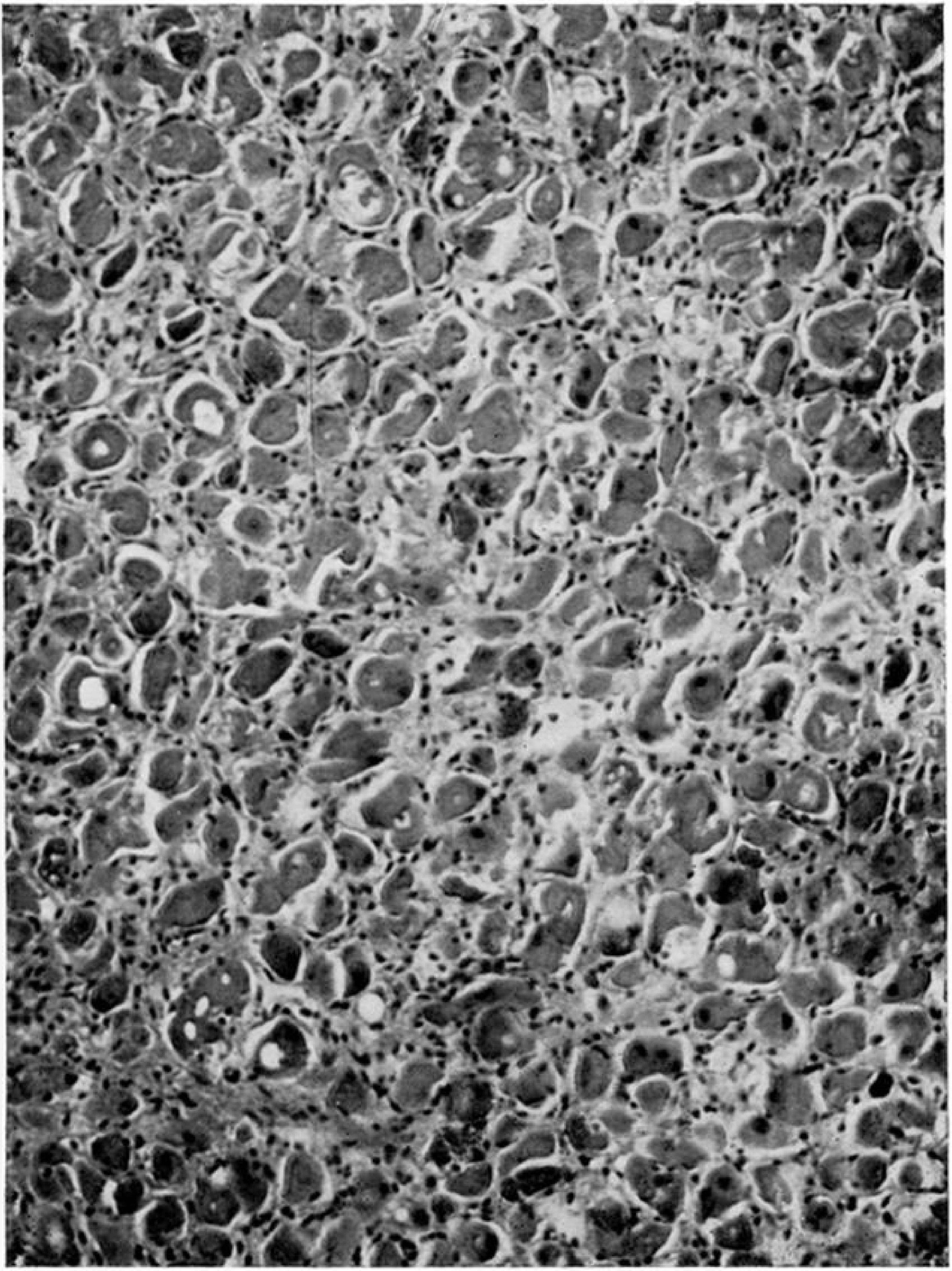

FIG. 67. Corpus luteum nearly at full term of pregnancy. ×130.

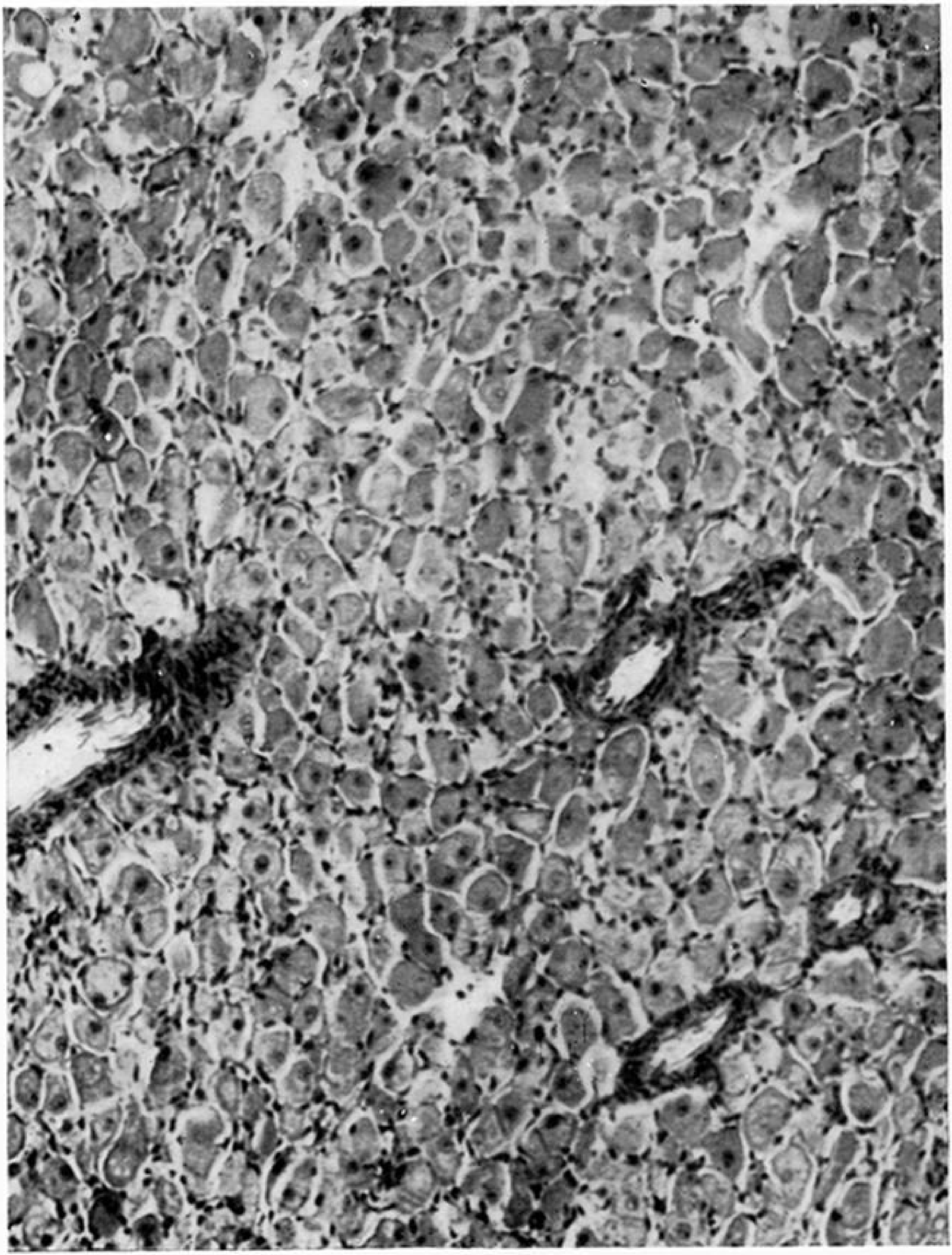

FIG. 68. Corpus luteum in early lactation. × 130.

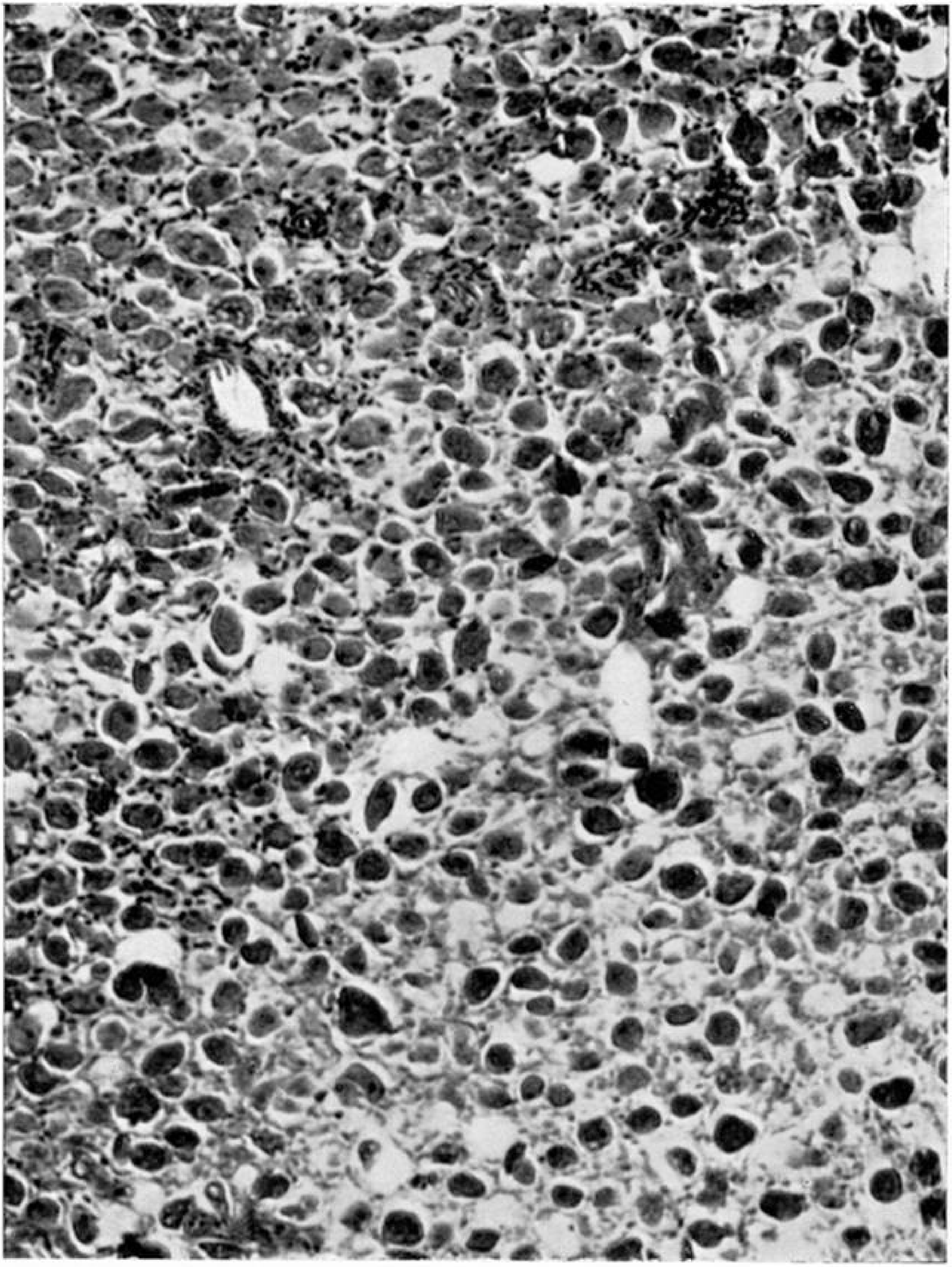

FIG. 69. Corpus luteum late in lactation. × 130.

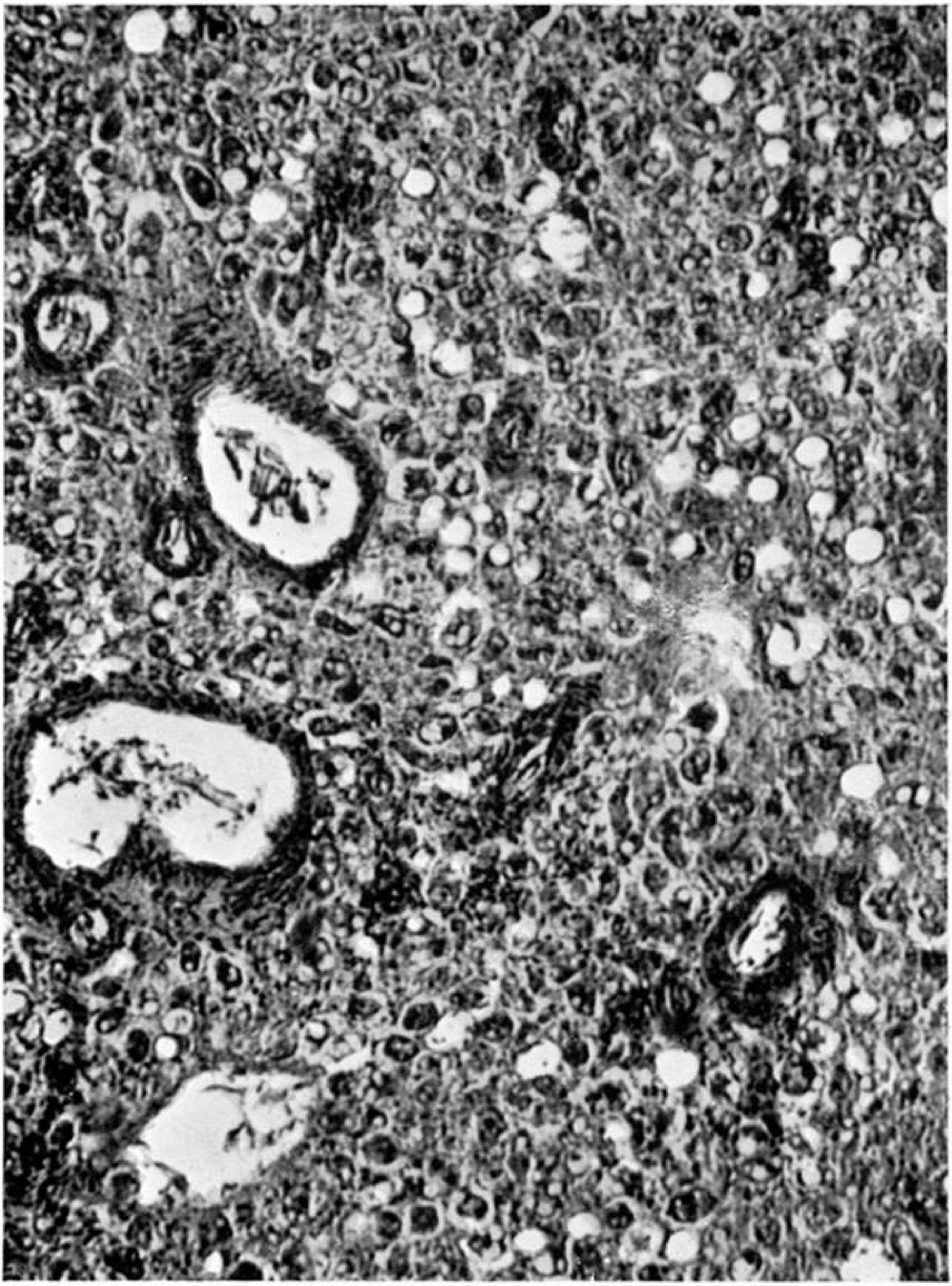

FIG. 70. Section of old corpus luteum showing blood vessels and vacuoles. ×130.

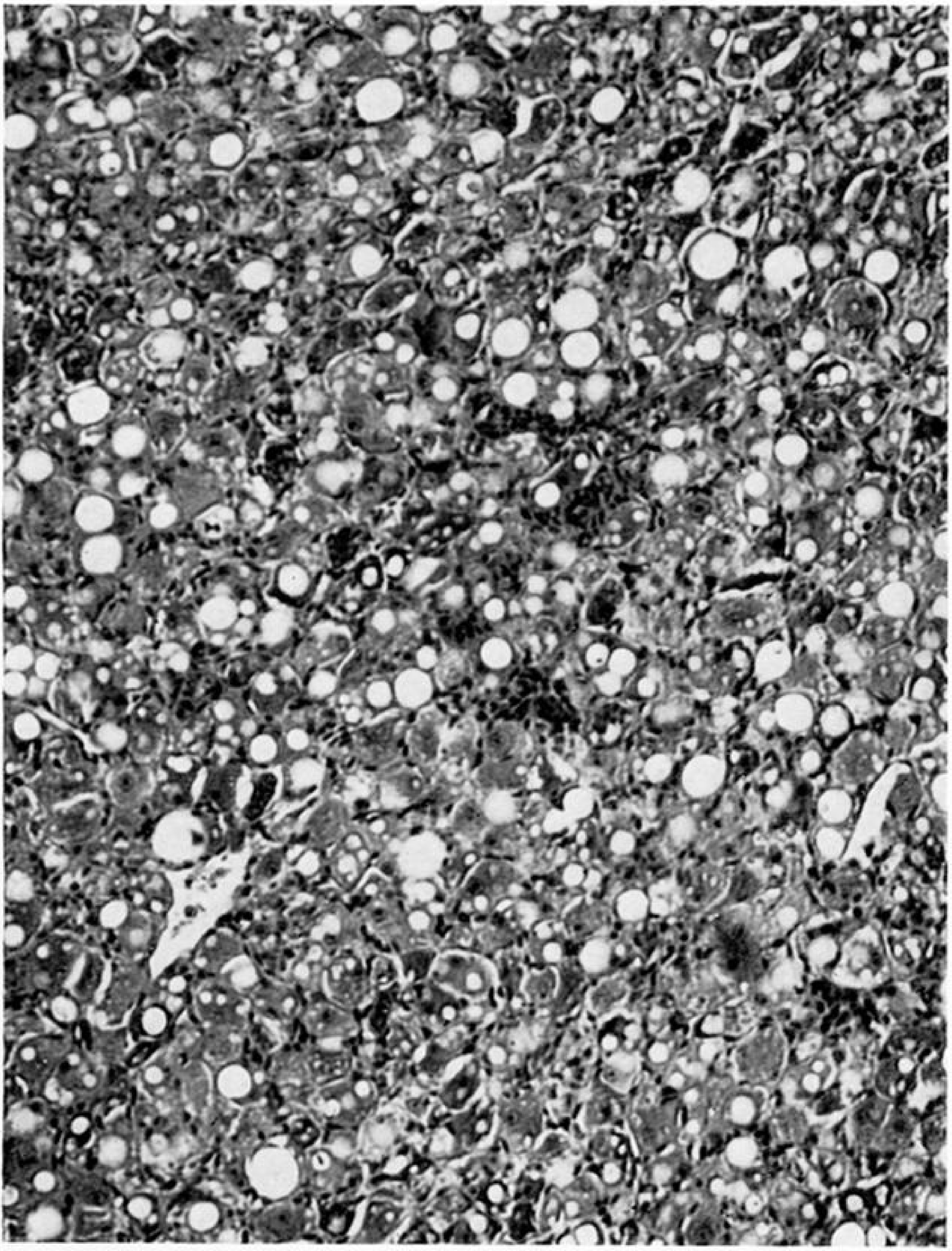

FIG. 71. The occurrence of vacuoles in a comparatively young corpus luteum. × 130.

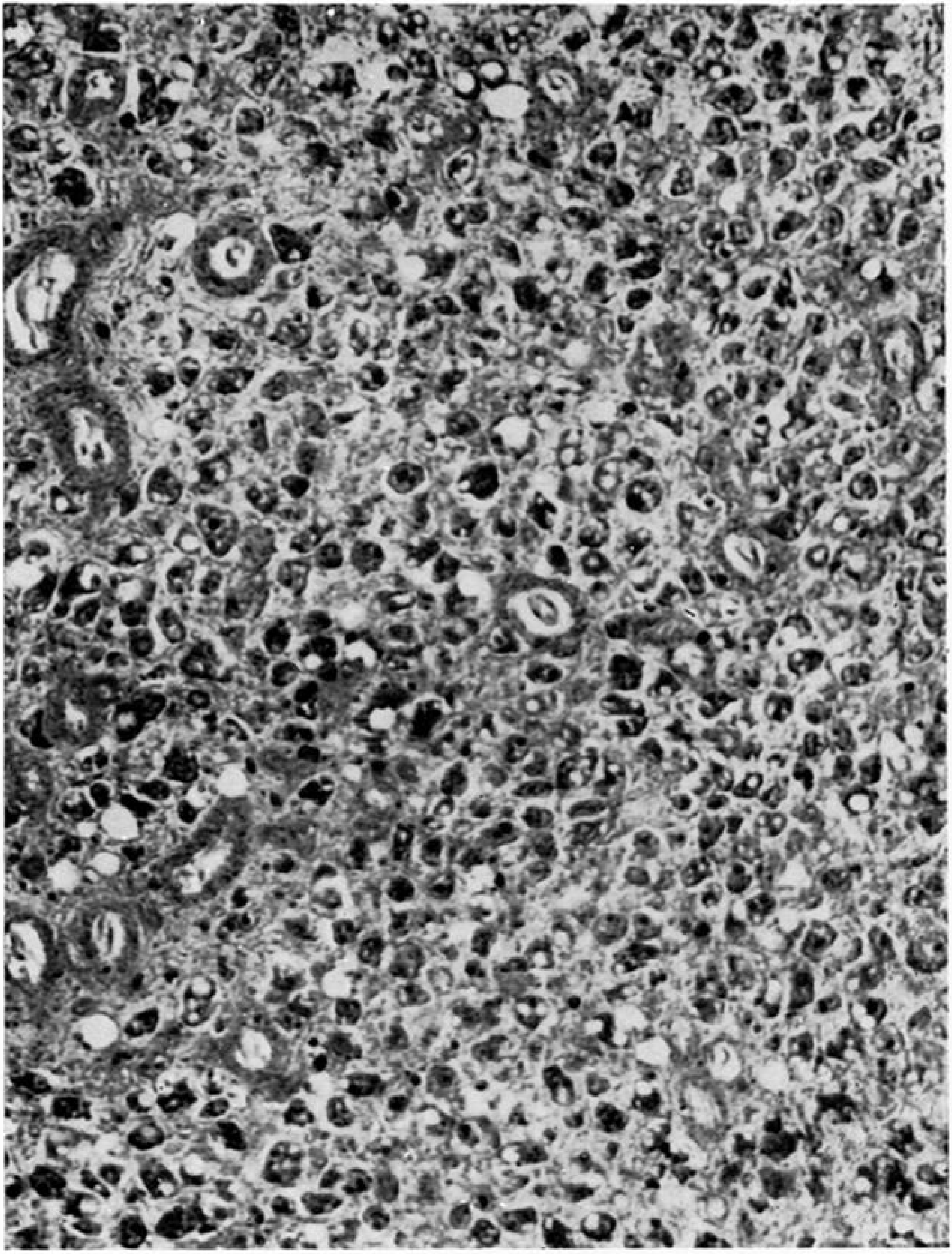

FIG. 72. Section of very old residual corpus luteum. × 130.

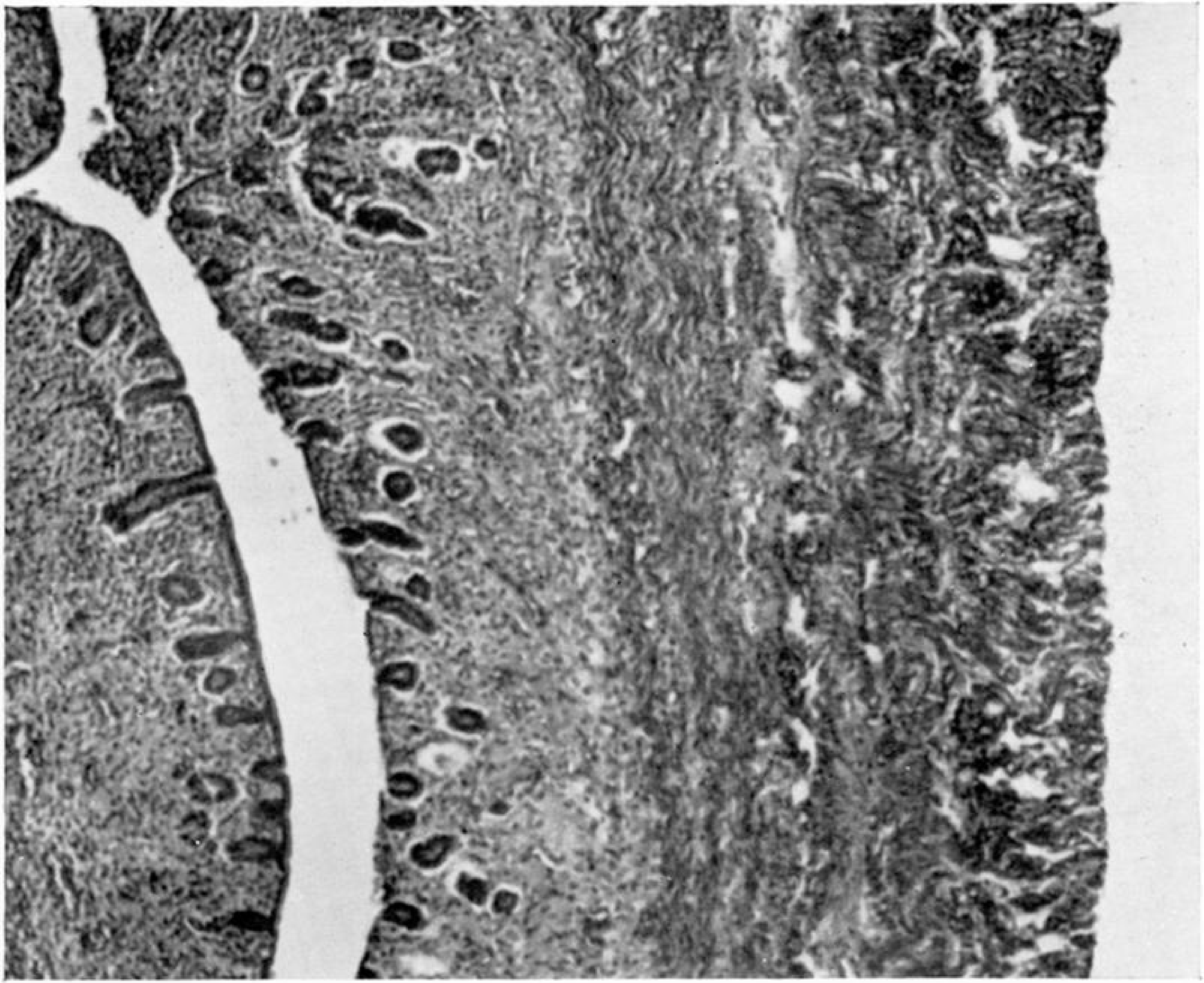

FIG. 73. Uterine mucosa. Prepubertal group A. ×130.

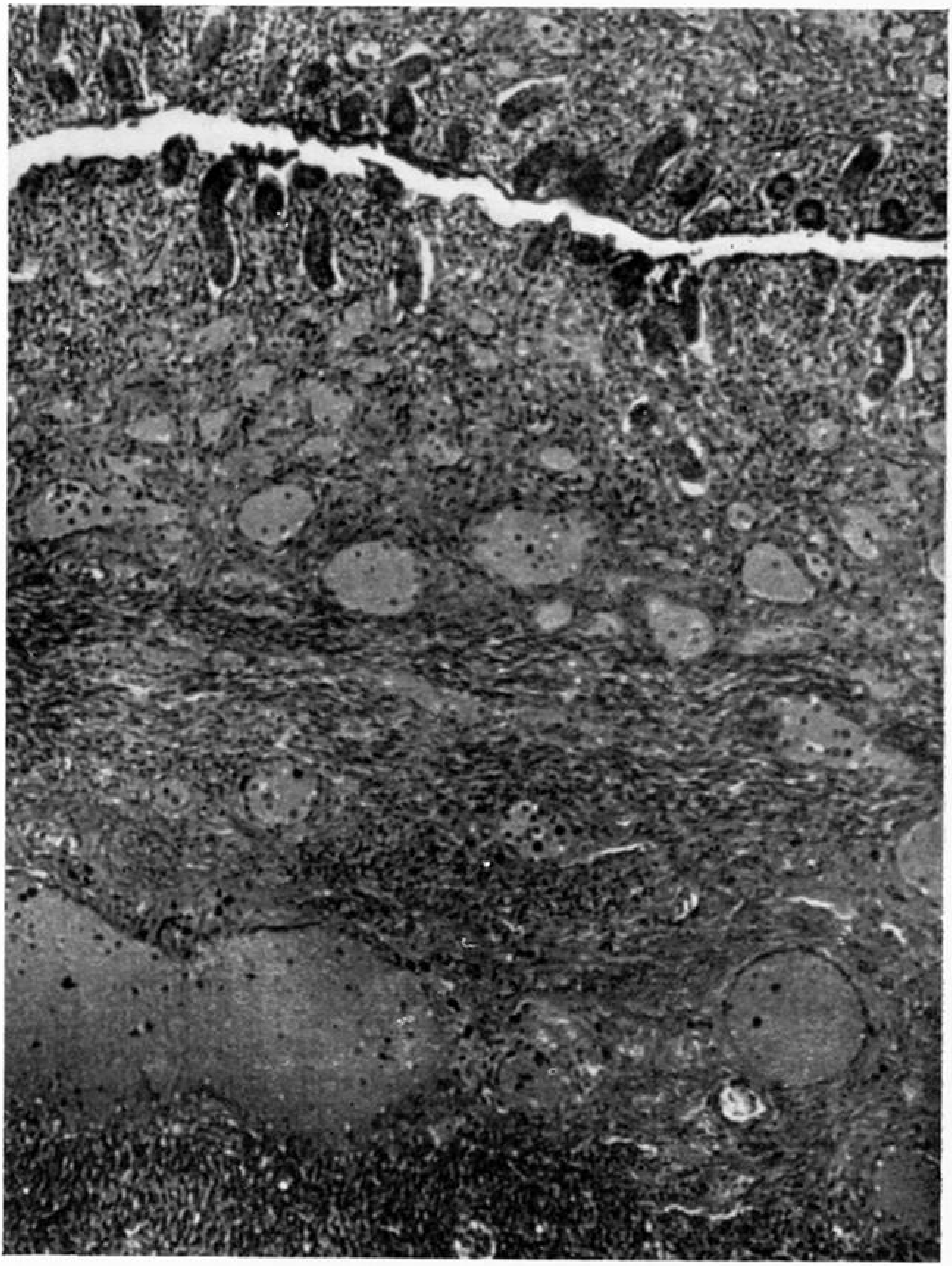

FIG. 74. Uterine mucosa and muscle layers highly vascularized. Prepubertal group B, approaching first oestrus. ×130.

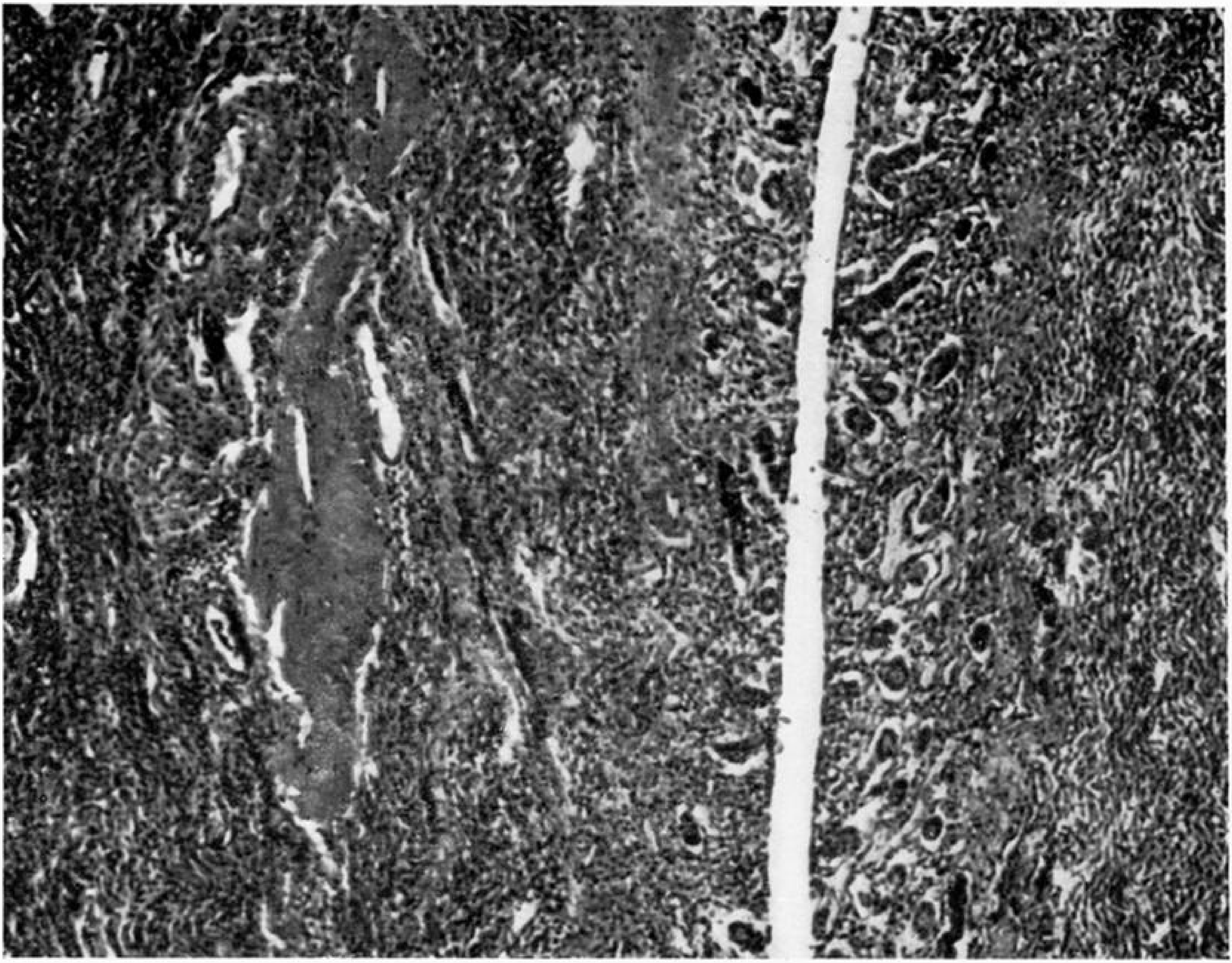

FIG. 75. Uterine mucosa during lactation. ×130.

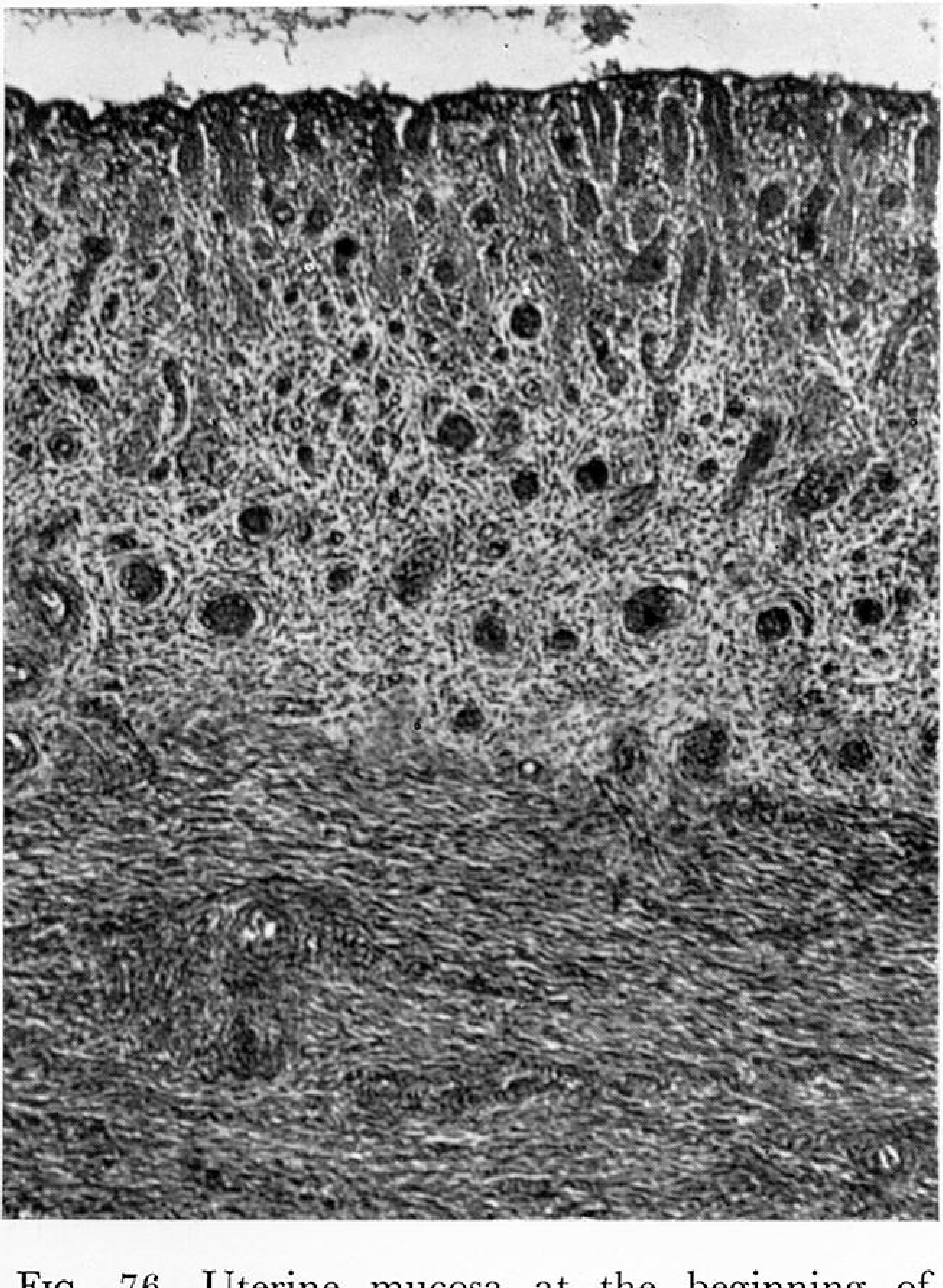

FIG. 76. Uterine mucosa at the beginning of pro-oestrus: increase in number and length of glands. ×130.

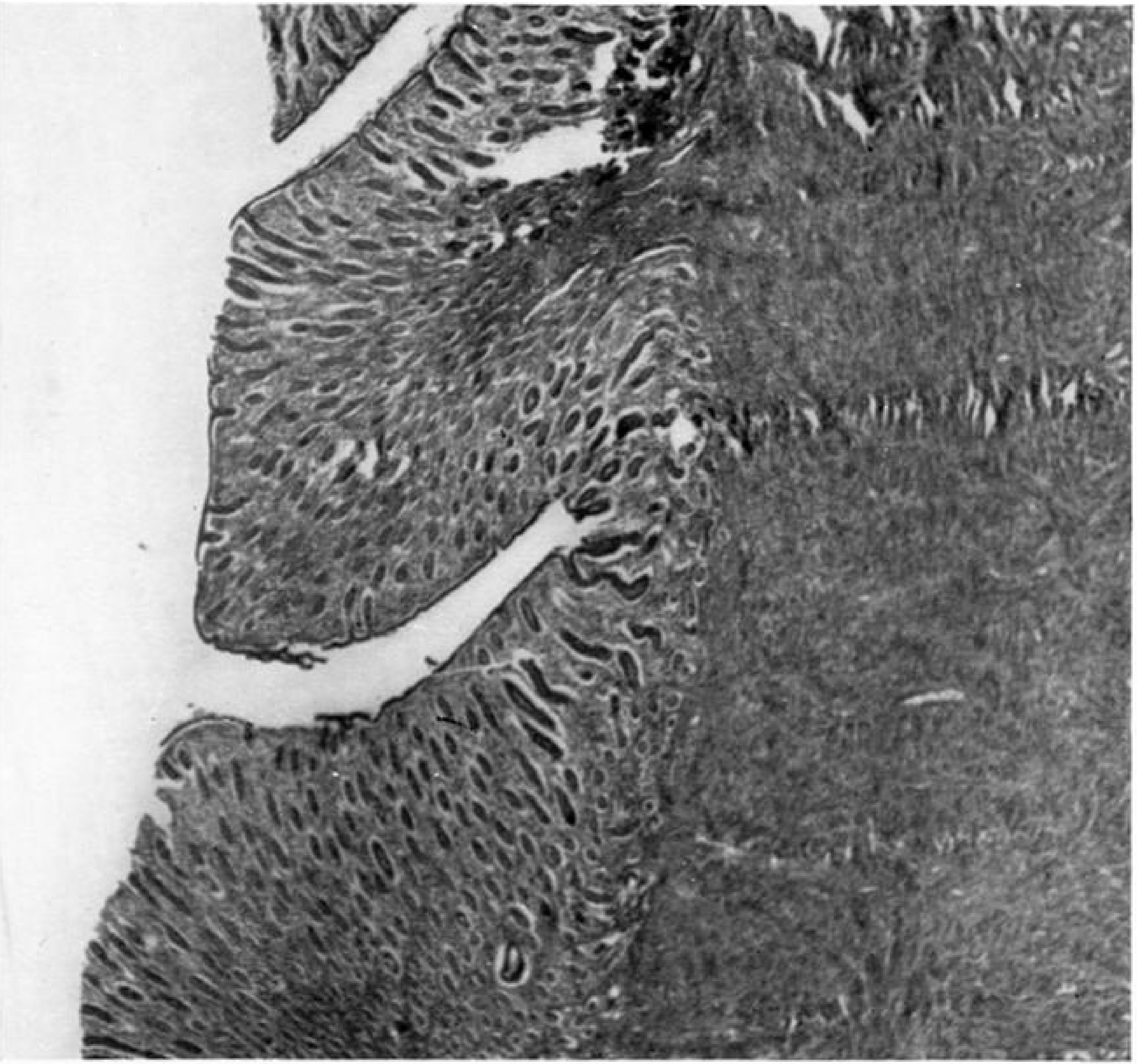

FIG. 77. Uterine mucosa at oestrus. × 30.

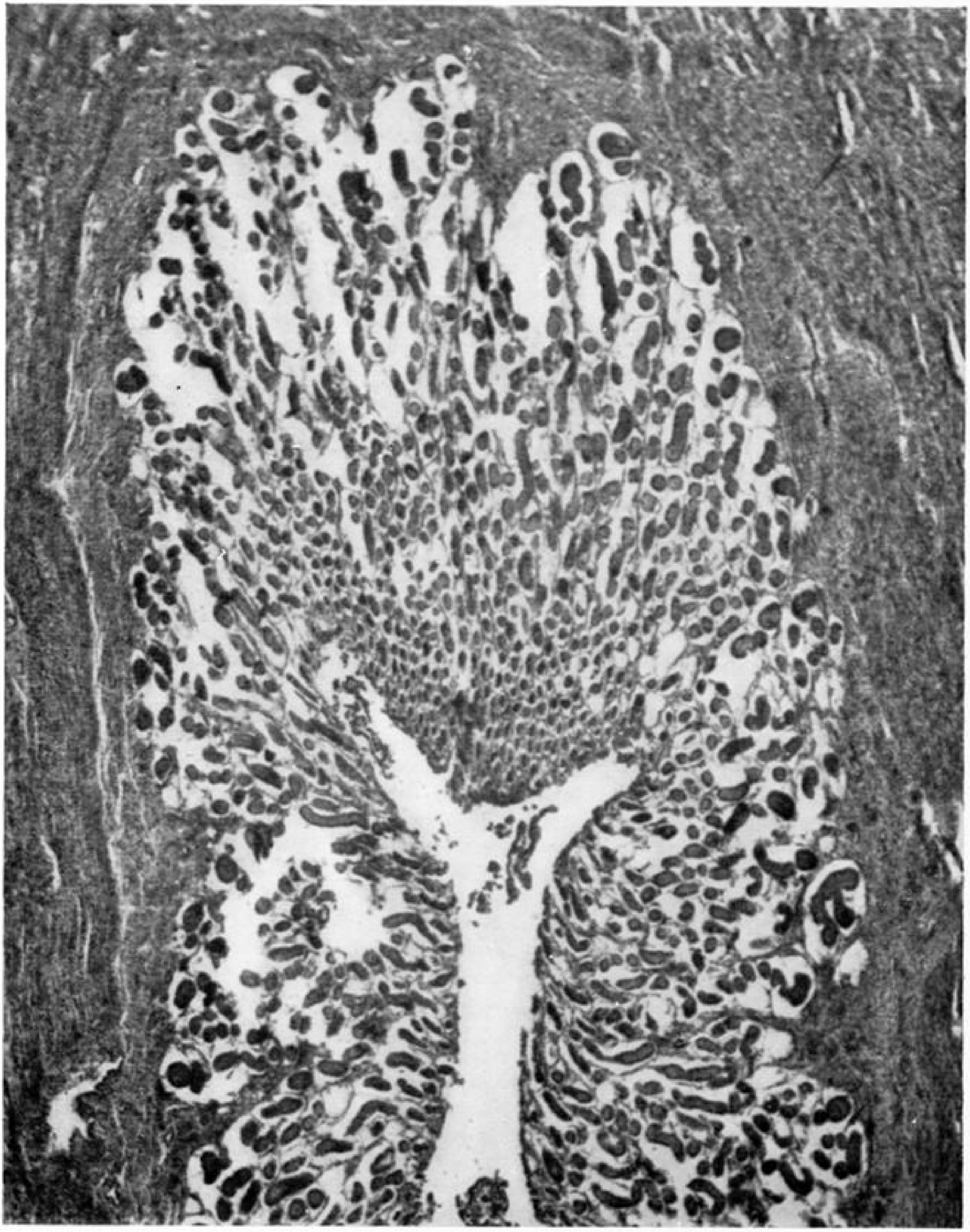

FIG. 78. Uterine mucosa: progestational proliferation. The shrinkage is due to delay in fixation. × 30.

FIG. 79. Uterine mucosa of the sterile horn in early pregnancy. The bases of the wide glands have narrow tails which penetrate the muscularis mucosae. × 130.

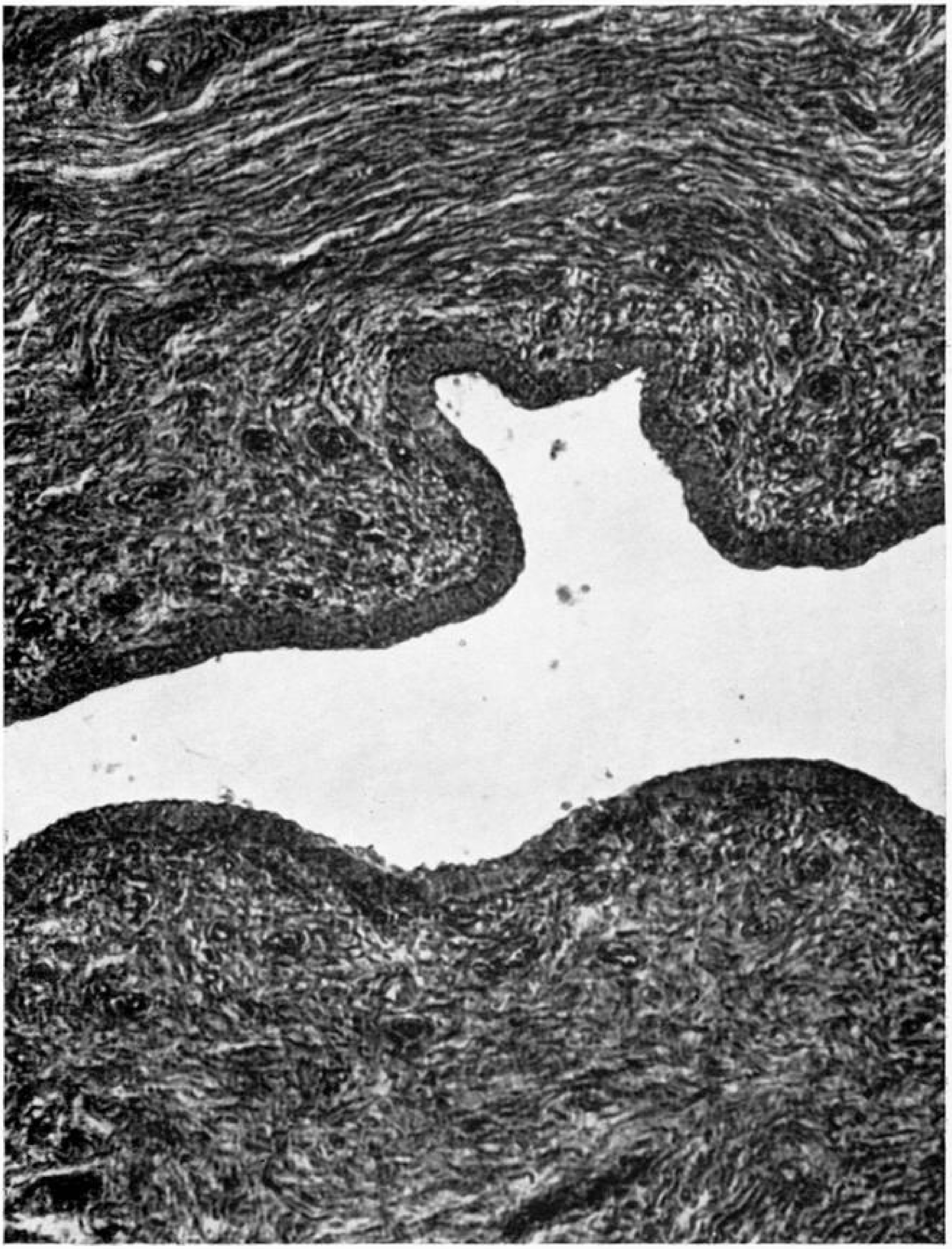

FIG. 81. Vaginal wall and epithelium in anoestrus (prepubertal). ×130.

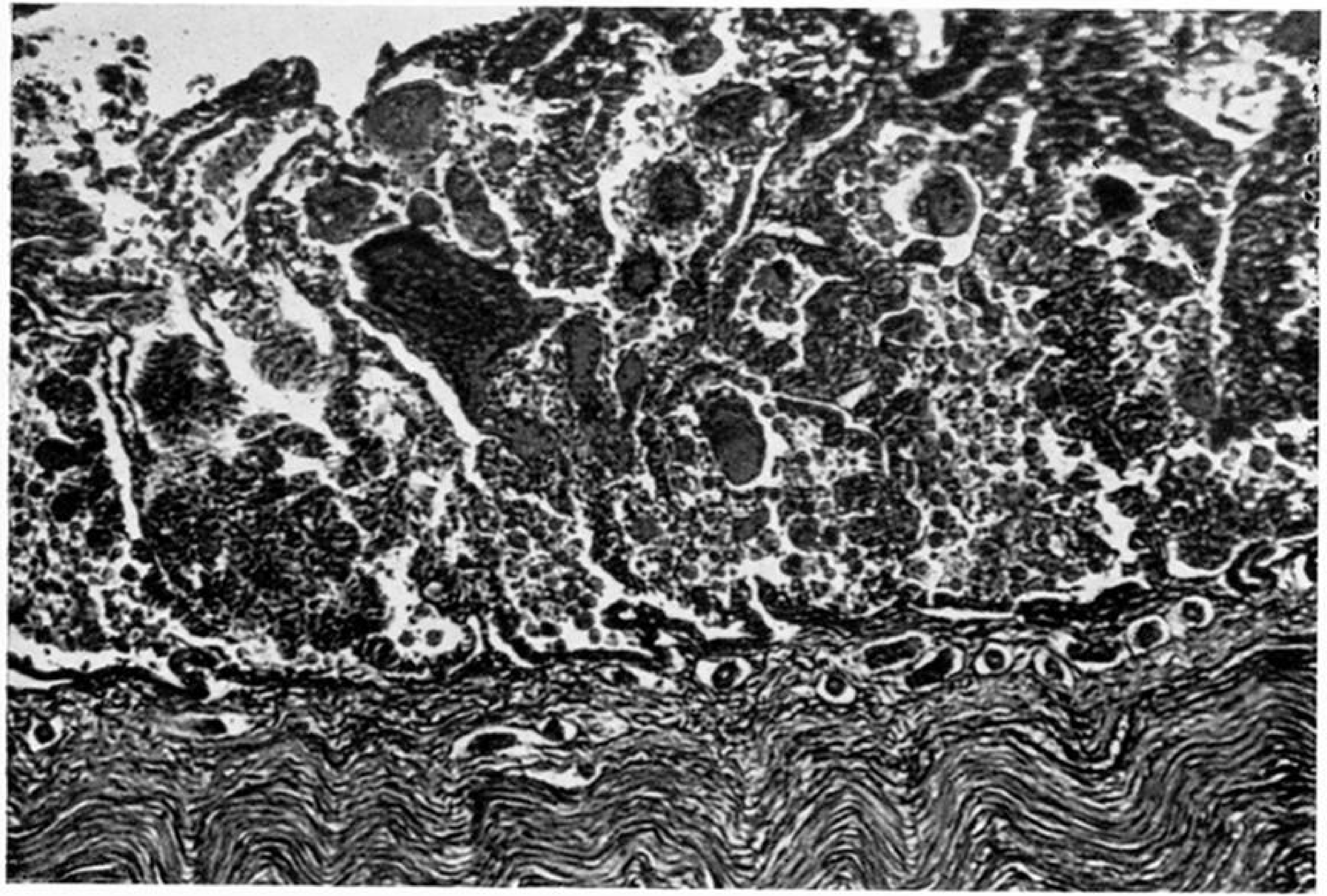

FIG. 80 (on left). Uterine mucosa of the sterile horn in late pregnancy. The epithelium of the bases of the glands is forming a new epithelial lining for the uterus beneath the degenerate mucosa. × 130.

FIG. 82 (on right). Vaginal wall and epithelium in anoestrus (parous). × 130.

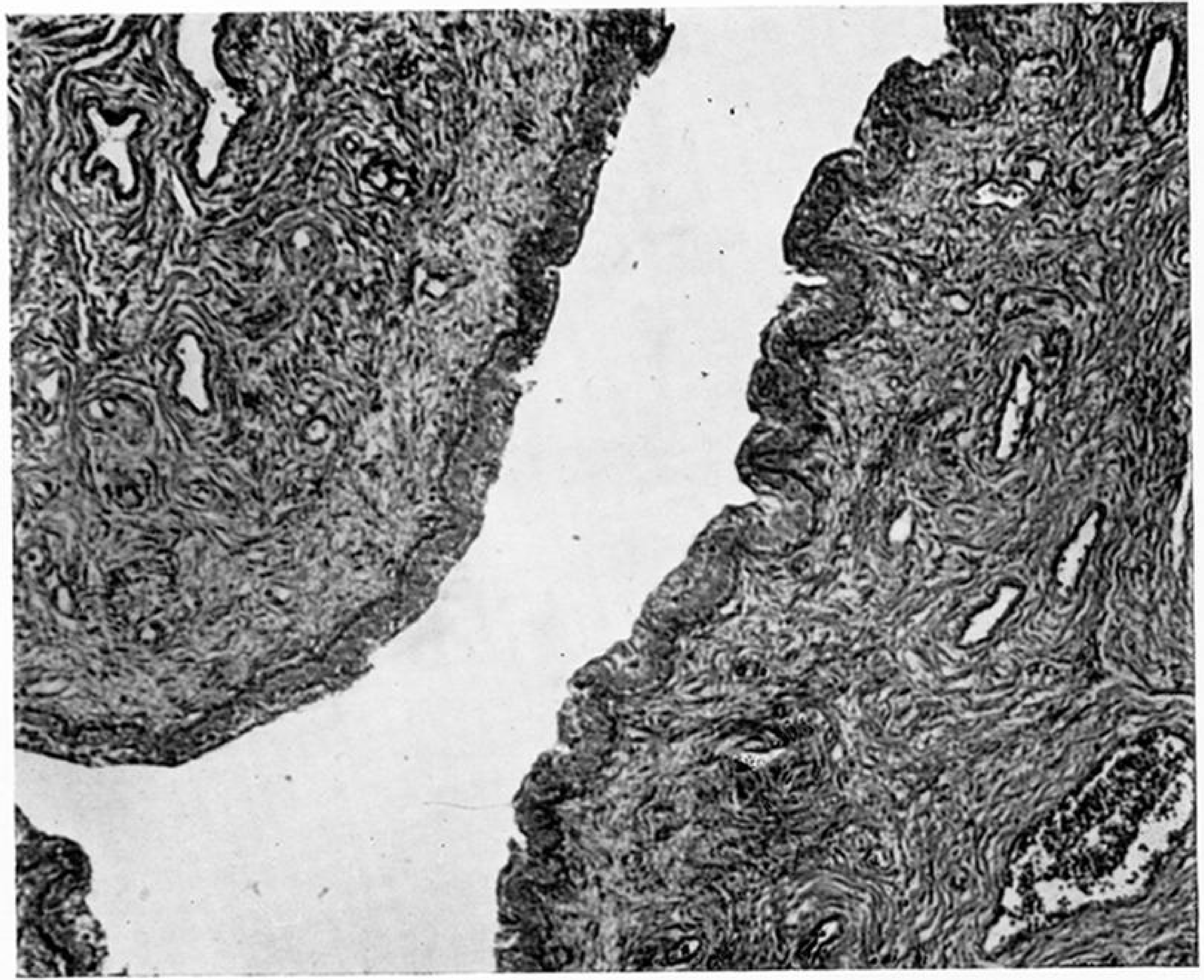

FIG. 83 (above). Vaginal wall and epithelium at oestrus. Vascularization of muscle layer. Cornification of epithelium and separation of it into layers. Desquamation into lumen. × 130.

FIG. 84 (on right). Vaginal wall and epithelium during pregnancy. ×130.

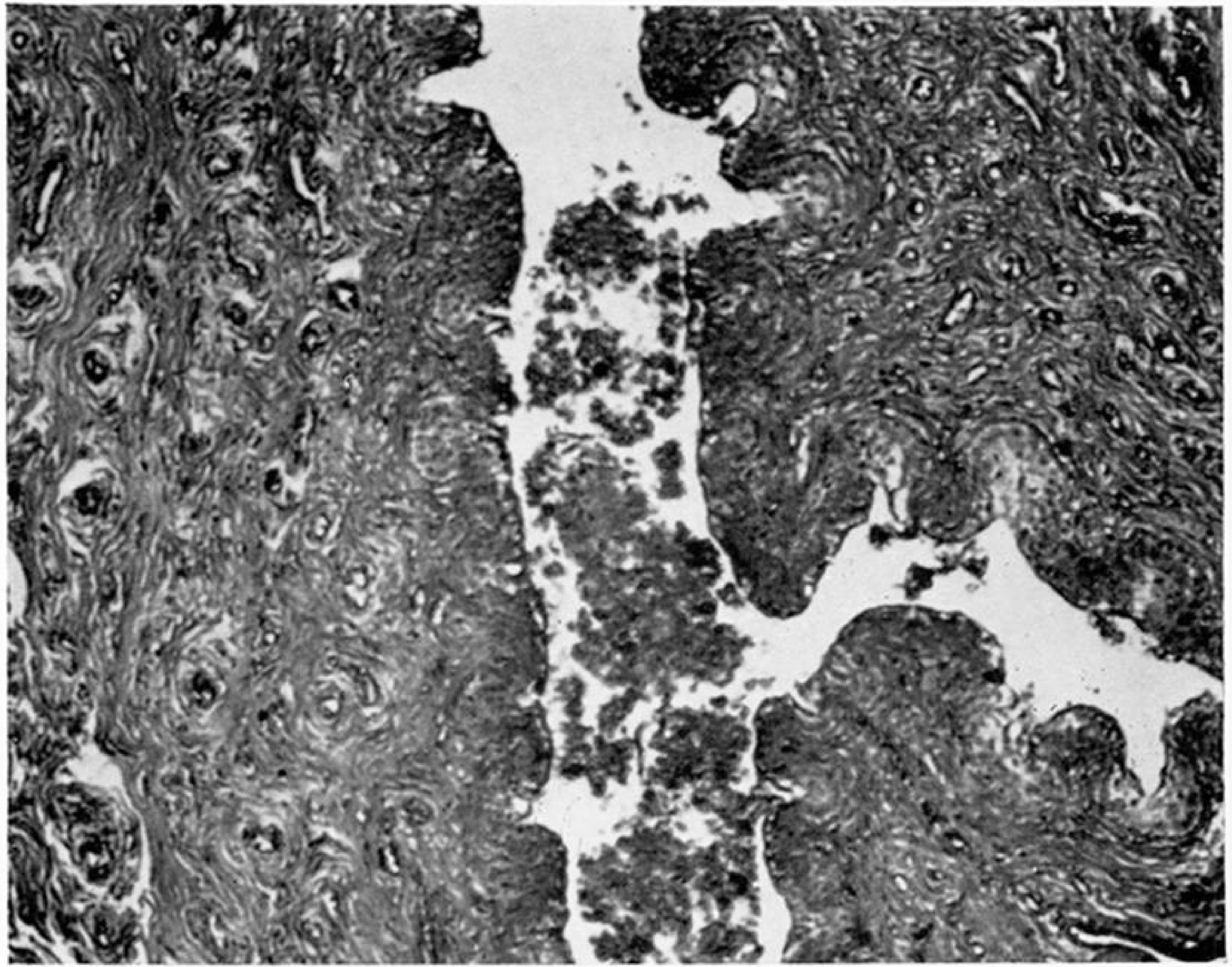

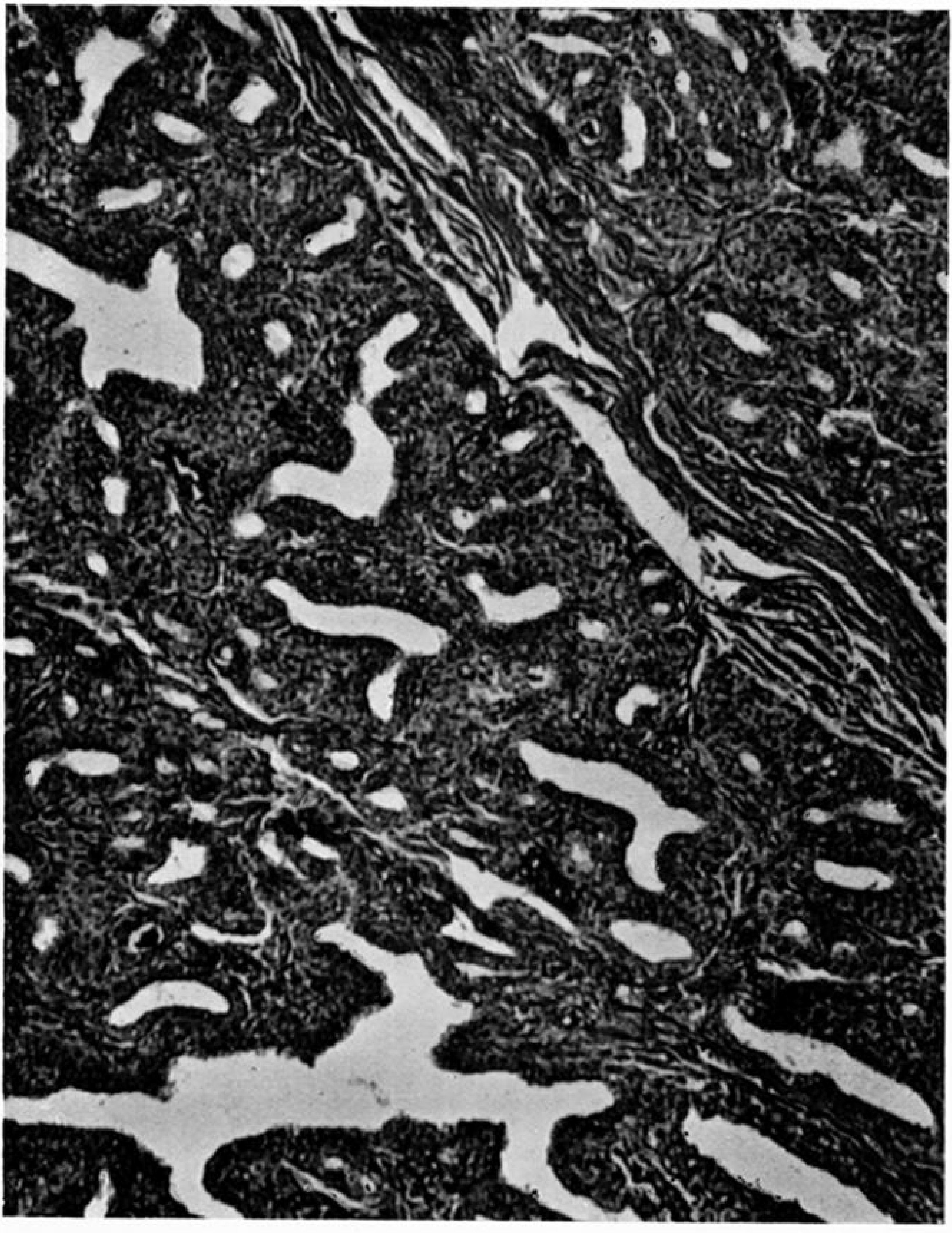

FIG. 85. Bartholin's gland: prepubertal. × 130.

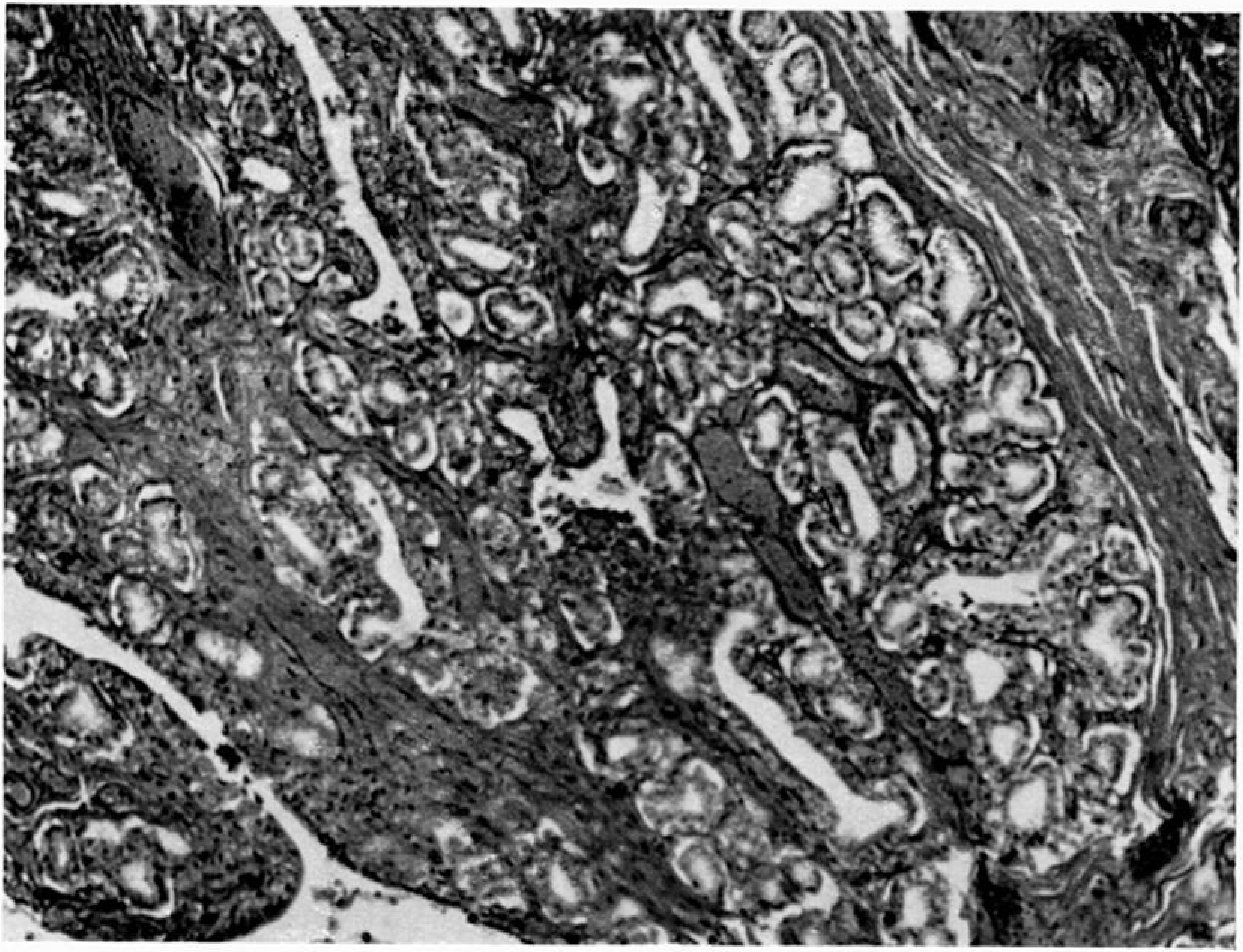

FIG. 86. Bartholin's gland at pro-oestrus. × 130.

FIG. 87. Bartholin's gland at oestrus. ×130.